

# Recent Advances and Emerging Innovations in Transurethral Resection of Bladder Tumor (TURBT) for Non-Muscle Invasive Bladder Cancer: A Comprehensive Review of Current Literature

Rei Ben Muvhar<sup>1</sup>, Reem Paluch<sup>2</sup>, Matan Mekayten<sup>3,4</sup> 

<sup>1</sup>Faculty of Medicine, Hebrew University of Jerusalem, Jerusalem, Israel; <sup>2</sup>Faculty of Medicine, Technion-Israel, Institute of Technology, Haifa, Israel; <sup>3</sup>Adelson School of Medicine, Ariel University, Ariel, Israel; <sup>4</sup>Department of Urology, Sanz Medical Center, Laniado Hospital, Netanya, Israel

Correspondence: Rei Ben Muvhar, Email rei.benmuvhar@mail.huji.ac.il

**Abstract:** Bladder cancer management, particularly non-muscle-invasive bladder cancer (NMIBC), has evolved significantly due to advancements in imaging techniques and surgical methodologies. Enhanced tumor visualization methods, including Photodynamic Diagnosis (PDD) and Narrow-Band Imaging (NBI), offer improved detection rates for both papillary tumors and carcinoma in situ (CIS), compared to traditional white-light cystoscopy (WLC). Recent studies suggest that these technologies enhance diagnostic accuracy, reduce recurrence rates, and improve oncological outcomes. Additionally, transurethral resection of bladder tumors (TURBT), performed with advanced imaging, has demonstrated better resection quality, particularly in terms of detrusor muscle presence. Despite these innovations, challenges remain in the long-term impact on recurrence-free and progression-free survival. Artificial intelligence (AI) integration into cystoscopic imaging further promises enhanced diagnostic precision and cost-effective bladder cancer management. As personalized treatment paradigms emerge, predictive biomarkers, including genomic and pathological markers, may help stratify patients for aggressive treatment, sparing those at lower risk from unnecessary interventions. Future research should focus on validating these AI models and combining them with enhanced imaging modalities to refine treatment protocols further. These advancements collectively represent a significant leap toward precision medicine in bladder cancer care.

**Keywords:** bladder neoplasms, transurethral resection, photodynamic therapy, narrow-band imaging, artificial intelligence, recurrence-free survival, biomarkers, tumor, precision medicine

## Introduction

Bladder cancer (BC) is one of the most common cancers globally, with an annual incidence of 570,000 new cases globally in 2020, and 212,000 deaths.<sup>1</sup> The majority (~76%) of patients are men.<sup>2</sup> This disparity between incidence and prevalence, coupled with high recurrence rates requiring prolonged surveillance, significantly impacts quality of life (QOL)<sup>3–5</sup> and places a substantial burden on healthcare systems in terms of resources and costs. Some researchers have even suggested that bladder cancer is the most expensive cancer to treat.<sup>6,7</sup>

TURBT is central to the diagnosis and management of bladder cancer, particularly in NMIBC, which accounts for approximately 75–80% of cases.<sup>8,9</sup> TURBT involves endoscopic examination, tumor sampling, and resection of visible tumors under white light.<sup>10,11</sup> Despite the relatively favorable prognosis for NMIBC, with cancer-specific survival rates of 66% at 15 years<sup>12</sup> and 88% at 8.7 years,<sup>13</sup> high recurrence and progression rates post-TURBT pose significant challenges. These rates vary widely based on clinical and pathological parameters, leading to recommendations for a second TURBT within 2–6 weeks in high-risk cases.<sup>10,11,14</sup> The method and quality of TURBT,<sup>15</sup> as well as the use of

adjunctive treatments, significantly impact patient outcomes. However, there remains a need for a deeper understanding of optimal TURBT practices, predictive factors, and the benefits of new technologies in improving long-term outcomes and reducing recurrence.

All these factors, along with accumulating evidence regarding the initial diagnostic process, will be discussed in this review, with the aim of providing a comprehensive and up-to-date overview of the various aspects of TURBT surgery, as well as the therapeutic and prognostic value of innovations in this field. The recommendations of major urological associations for each topic reviewed are also summarized.

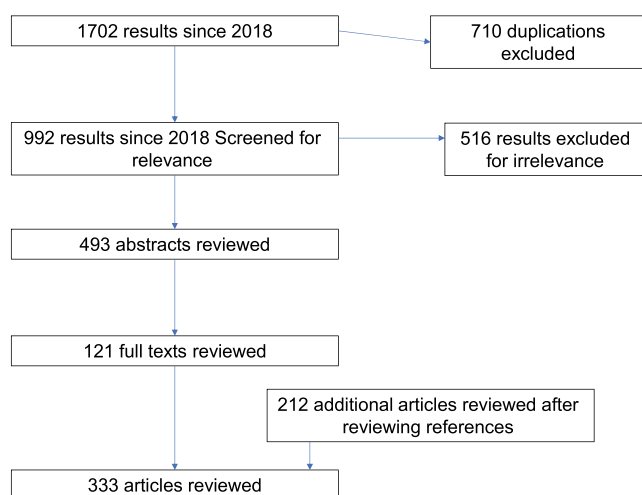
## Methods: Systematic Review Process

A systematic literature review was conducted on PubMed between January 2018 and September 2024, using specific terms related to key components that were deemed relevant to a comprehensive review of different aspects of TURBT in NMIBC patients. The focus was on ways to improve its outcomes, based on a preliminary search for reviews, and the EAU and AUA guidelines. The search yielded a total of 1702 results since January 2018. After removing duplicates, 992 unique results were obtained, of which 493 abstracts were reviewed. A total of 121 full-text articles were thoroughly analyzed, including the relevant references. To provide a comprehensive assessment and augment our findings, we meticulously scrutinized the references cited within the articles and incorporated any additional relevant sources that we deemed necessary, as depicted in Figure 1. The detailed search strategy and process is described in the [Supplementary material](#).

Unfortunately, due to space limitations, we could not include topics such as immediate instillation of chemotherapy, the role of TURBT in MIBC, or alternatives to TURBT (eg, active surveillance or radical cystectomy). Similarly, chapters on repeat TURBT, risk stratification, recurrence mechanisms, and TURBT complications were excluded. We also reviewed the current American Urological Association (AUA) and European Association of Urology (EAU) guidelines and commented accordingly on each topic, where available.

## Aim of the Study

The primary aim of this review is to provide a comprehensive analysis of current literature pertaining to TURBT, including unique aspects such as patient selection, diagnostic approach, and surgical techniques. The review also focuses on methods to improve TURBT outcomes, particularly oncological results like recurrence, progression, and overall survival (OS). Finally, the study touches upon future directions for TURBT and identifies open questions for further investigation.



**Figure 1** Flow diagram of the evidence acquisition in this systematic review on TURBT aspects.

## Diagnostic and Pre-Procedural Approach to TURBT

### Laboratory and Imaging Assessment

Before performing TURBT, several diagnostic tests are recommended, as they can influence the surgeon's approach. Urine cytology, which has a high sensitivity for high-grade (HG) tumors (60–84%)<sup>16,17</sup> and is highly specific (>95%),<sup>18</sup> should be included. However, urine cytology has low sensitivity for low-grade (LG) tumors (16–26%),<sup>16,17</sup> potentially necessitating random bladder biopsies to identify non-trivial flat reddish lesions. Novel molecular tumor markers cannot replace cystoscopy or urine cytology but may serve as adjunctive tools to detect tumors missed during cystoscopy and aid in surveillance.<sup>11</sup> Simultaneous upper urinary tract lesions occur in less than 2% of cases<sup>19–21</sup> but are more common when the tumor is located at the trigone (7.5%)<sup>21</sup> or in cases of multiple high-risk CIS tumors.<sup>22</sup>

Both the AUA and EAU guidelines recommend upper urinary tract imaging as part of the initial evaluation. The AUA suggests using computed tomography urography (CTU) or magnetic resonance urography (MRU) due to their ability to detect lymph nodes and filling defects, while the EAU recommends abdominal ultrasound or CTU as basic tests, with CTU/MRU recommended when bladder cancer is detected and the risk of simultaneous upper urinary tract carcinoma (UUTC) is high. Imaging should likely be risk-stratified and conducted within six months of initial diagnosis.<sup>10</sup> Positive imaging should direct the surgeon to inspect upper tract lesions during TURBT using ureteroscopes.

A newer modality, multiparametric magnetic resonance imaging (mpMRI), along with the VI-RADS system, is used to differentiate NMIBC from muscle-invasive bladder cancer (MIBC) prior to TURBT and can guide other decisions.<sup>23</sup> Over the past six years, five systematic reviews and meta-analyses involving thousands of patients have been published.<sup>24–28</sup> These studies reported sensitivities of 78–91%, specificities of 84–92%, and an area under the curve (AUC) of 0.93,<sup>27,28</sup> with good inter-observer agreement.<sup>26</sup> Integration of mpMRI into the diagnostic process has been shown to significantly reduce the time to appropriate treatment.<sup>29</sup> Despite these promising results, it is still too early to rely solely on mpMRI for accurate staging diagnosis. It is not a substitute for TURBT and is not yet recommended by major urological associations.<sup>10,11</sup>

### Physical and Bimanual Examination in Preoperative Assessment of Bladder Cancer

Physical examination should include an assessment of body habitus, abdomen, and genitalia, as tumors located in the anterior or posterior bladder wall may be challenging to resect in obese patients. In men, the examination should include a digital rectal exam to assess the prostate, which may reveal tumor involvement. Bladder wall thickening may suggest MIBC, while a palpable or mobile mass could indicate cT3 disease, and a fixed mass may suggest cT4 disease. Although physical examinations rarely yield significant findings in NMIBC patients,<sup>10</sup> they remain a critical part of preoperative evaluation.<sup>30</sup> The EAU guidelines state, “A focused urological examination is mandatory, although it does not reveal NMIBC”.

Bimanual examination under anesthesia (BEUA) is used before and after TURBT to establish clinical staging. A palpable mass post-resection suggests locally advanced disease and is associated with significant prognostic value. For instance, a palpable mass after TURBT predicted five- and ten-year survival rates of 83% versus 50%, and 70% versus 45%, respectively.<sup>31</sup> Ploeg et al found that BEUA accurately predicted the stage in 57.6% of patients, but resulted in understaging in 31% and overstaging in 11.3%.<sup>32</sup> Additionally, BEUA use has declined over time, with notable differences between teaching and non-teaching hospitals. Rozanski et al<sup>33</sup> found BEUA alone was correct in only 35% of cases (similar to findings by Mehrsai<sup>34</sup>), but combining BEUA with cross-sectional imaging improved staging accuracy for T3 disease or higher. The EAU guidelines recommend BEUA,<sup>11</sup> though the AUA guidelines consider it optional.<sup>10</sup>

### Pre-TURBT Cystoscopy

Flexible cystoscopy is recommended on an outpatient basis prior to TURBT to identify and characterize suspicious lesions. Experienced practitioners can use tumor appearance to estimate stage and grade,<sup>35–37</sup> and this evaluation can help determine whether outpatient fulguration of low-grade tumors is appropriate.<sup>38</sup> However, cystoscopy is not always necessary prior to TURBT, especially when imaging results are definitive.

## Anesthesia Considerations

Anesthesia strategy should be carefully discussed with the anesthesiologist, considering patient comorbidities and tumor characteristics. General anesthesia with paralysis is often preferred to ensure patient immobility, optimize bladder relaxation, and minimize bladder motion during breathing.<sup>39</sup> However, spinal anesthesia has been suggested to offer advantages over general anesthesia, with a hazard ratio for recurrence of approximately 0.6.<sup>40</sup> Adding an obturator nerve block (ONB) to spinal anesthesia can improve detrusor muscle (DM) sampling and prolong recurrence-free survival (RFS) while potentially reducing complications.<sup>41–43</sup> Muscle relaxation is particularly crucial for lesions near the ureteral orifices, as the obturator jerk reflex may increase the risk of bladder perforation.

## Surgical Considerations

### TURBT Quality and Its Influence on Outcomes

The primary goal of TURBT is to diagnose, stage, and treat bladder cancer by obtaining tissue for histopathological evaluation and removing visible tumors. TURBT serves as both a diagnostic and therapeutic procedure, guiding decisions for additional treatments, such as intravesical therapy or cystectomy.

Several indicators of high-quality TURBT have been proposed, some of which have been incorporated into broader national and population health programs.<sup>39,44–48</sup> One critical indicator is the presence of DM in the resected specimen. Numerous studies have demonstrated that the absence of DM is a significant predictor of poor oncological outcomes, including a higher likelihood of residual disease post-TURBT,<sup>45,49–53</sup> reduced RFS,<sup>54–56</sup> and increased recurrence rates, especially for T1 disease.<sup>57</sup> Studies have further shown a strong correlation—up to 3.58 times higher risk—between the absence of DM and progression to T2 disease.<sup>54,56,58</sup>

The EAU guidelines consider the presence of DM in the resected specimen a surrogate marker of resection quality and mandate its presence in all TURBT procedures, except for low-risk Ta LG tumors. When DM is absent, a second TURBT is typically recommended.<sup>11</sup> However, the AUA guidelines only state that a lack of DM increases the risk of understaging.<sup>10</sup>

### Implications of Incomplete Resection and Positive Margins on TURBT Outcomes

Incomplete resection during TURBT is difficult to estimate due to the use of small tissue fragments. While some studies have found no significant correlation between complete macroscopic resection and RFS,<sup>46,59</sup> others have demonstrated that positive pathological margins are associated with higher rates of residual disease and recurrence. For instance, Jancke et al found that TURBT procedures with positive findings on additional marginal resection had significantly higher overall recurrence rates (83% vs 57%) and local recurrence rates (58% vs 19%), with a p-value of less than 0.001.<sup>60</sup> Similar findings have been reported for vertical<sup>61</sup> and lateral margins.<sup>62</sup> Both the EAU and AUA guidelines recognize complete resection as a key quality indicator for effective TURBT. Positive margins are considered a strong indication for repeat TURBT, except in cases where immediate cystectomy is planned.<sup>10,11,15</sup>

### Impact of Surgeon Experience on TURBT Outcomes

Surgeon experience plays a critical role in determining TURBT outcomes. Brausi et al identified significant variability in residual disease rates across different institutions, underscoring the importance of surgeon skill and thoroughness.<sup>15</sup> TURBT is unique in that much of the procedure is performed by a single individual, meaning the surgeon's expertise greatly influences complex decisions, from determining whether TURBT would be overtreatment for an indolent tumor to assessing whether the patient would benefit from early cystectomy.<sup>63</sup>

Less experienced surgeons have been shown to obtain less DM in resected specimens, especially in high-risk cases or those involving tumors in challenging locations. This correlates with worse oncological outcomes, including higher rates of residual disease at the first follow-up cystoscopy, increased recurrence, and more postoperative complications.<sup>50–52,64–69</sup> Additionally, higher survival rates have been associated with surgeries performed by high-volume surgeons for T1 disease.<sup>63</sup> Studies assessing the learning curve of TURBT suggest that clinical outcomes improve markedly after

approximately 101 operations, with optimal results seen after 170 procedures. The poorest results were observed in the first 45 cases, despite increasing case complexity during that period.<sup>68</sup>

While some studies have not demonstrated a significant association between surgeon experience and outcomes,<sup>70–73</sup> this could be due to factors such as the training environment, supervision, and teaching techniques.<sup>74</sup> Some alternative surgical techniques may also influence the findings.<sup>75</sup> Specific scoring systems have been developed to assess resident competency in TURBT.<sup>76,77</sup> Despite the potential benefits of centralizing TURBT to experienced surgeons, practical considerations mean that standard TURBT procedures cannot be restricted to a select few. Therefore, improving outcomes across a broad range of surgeons remains essential.<sup>78</sup>

The EAU guidelines endorse surgical training programs to improve outcomes, though they provide no concrete recommendations, while the AUA guidelines do not address this issue.<sup>11</sup>

## The Impact of Surgical Checklists on TURBT Outcomes: Documentation, Implementation, and Clinical Implications

Surgical checklists play a crucial role in documenting patient outcomes and ensuring accurate, consistent management. They allow surgeons to record key factors, such as tumor invasion, incomplete resection, absence of DM, tumor grade, and administration of immediate chemotherapy, all of which influence surveillance decisions and additional interventions (chemotherapy, radiotherapy, or surgery). The use of bladder diagrams has been introduced as a quality performance indicator in national programs, such as Scotland's,<sup>45</sup> and is strongly recommended by the EAU guidelines.<sup>11</sup>

The introduction of surgical checklists has shown significant benefits. Haynes et al reported a 30-day mortality reduction and fewer complications after checklist implementation among 7,688 patients.<sup>79</sup> Other studies have shown similar positive outcomes.<sup>80</sup> A large study in Scotland's National Quality Improvement Program demonstrated strong responses to these initiatives, although it lacked a control group.<sup>45</sup> In the context of TURBT, controlled studies examining the impact of surgical checklists have shown improvements in documentation,<sup>81–84</sup> but the evidence regarding their impact on DM presence, recurrence rates, or RFS remains conflicting.<sup>82,84–87</sup> Nonetheless, the EAU guidelines strongly recommend using surgical checklists and documenting critical details of the patient, tumor, and operation, including a bladder diagram.<sup>11</sup>

## Challenges and Considerations in TURBT Procedures

### Limitations in Equipment Accessibility

TURBT is not always performed smoothly due to the availability of endoscopic equipment for bladder tumor resection. Several anatomical challenges, such as a large prostate or high bladder neck, can limit instrument access and maneuverability. For instance, a high bladder neck can make it difficult for the surgeon to reach certain areas, necessitating the use of specialized instruments or partial prostate resection to improve visibility. Additionally, urethral strictures may require urethral dilators or endoscopic incision tools such as Otis dilators.

### Tumor Location and Surgical Considerations

Tumor location significantly affects treatment outcomes. Tumors situated in the bladder dome or anterior wall are associated with worse overall survival and RFS.<sup>88</sup> For bladder dome tumors, partial cystectomy may offer improved survival rates. Tumors located in the bladder neck, particularly on the dorsal aspect, have also been linked to poorer RFS and PFS.<sup>89–92</sup>

Special precautions are required when resecting tumors from the lateral bladder wall to avoid the obturator nerve reflex (ONR), which increases the risk of bladder perforation. Minimizing bladder distension, reducing energy levels, and using blunt dissection with the resection loop are strategies to avoid ONR.<sup>74,93</sup> Neuromuscular blockade, en bloc resection of bladder tumors (ERBT), and laser use have also been shown to reduce ONR incidence.

### Special Considerations in Tumor Resection

Tumors in the anterior bladder wall present particular challenges and may require assistance, such as suprapubic pressure, to improve resectoscope access. Open-angled resection loops are recommended for more efficient resection. When



operating near the ureteral orifices, coagulation should be avoided to prevent scarring and subsequent ureteric obstruction. For tumors affecting the ureteral orifices, resection should be performed using cutting settings to preserve renal function. Temporary ureteral stent placement can help reduce the risk of stricture formation. Postoperative imaging, such as renal ultrasound or CTU, is recommended to evaluate renal function.<sup>74</sup>

## Tumors in Bladder Diverticula

Bladder diverticula, defined as outpouchings of the bladder wall, frequently lack a complete muscular layer, which poses significant challenges for surgical intervention. In cases of tumors located within these diverticula, particularly HG or T1 tumors, achieving complete resection is markedly difficult. The absence of a DM layer heightens the risk of bladder perforation, making the attainment of deep surgical margins nearly unattainable. Furthermore, the narrow neck of the diverticula may impose additional limitations on surgical access, thereby complicating the procedure even further. This anatomical constraint not only impairs visibility but also restricts the maneuverability of surgical instruments, ultimately increasing the risk of incomplete tumor resection or subsequent recurrence. Given these challenges, partial or radical cystectomy, or diverticulectomy, is frequently recommended in such cases.<sup>10</sup>

## The Role of Random Biopsies in Staging and Diagnosis

Random biopsies are typically performed to detect concomitant CIS and to improve staging accuracy, especially in patients with positive cytology but no visible tumor on cystoscopy.<sup>11</sup> Random biopsies are more commonly performed in intermediate- and high-risk patients, as well as in cases with positive cytology.<sup>94–98</sup> However, random biopsies carry risks such as tumor reimplantation,<sup>99</sup> bleeding, and infection. Consequently, they should be reserved for specific cases where they are clearly indicated.

The current EAU guidelines recommend biopsies of suspicious areas, as well as random biopsies and urethral biopsies, in cases of positive cytology with normal-appearing cystoscopy.<sup>11</sup> The AUA guidelines recommend random biopsies for intermediate- to high-risk patients with persistent or recurrent disease or those who have undergone intravesical therapy.<sup>10</sup> A prostatic urethra biopsy is also recommended in cases of bladder neck tumors or visible prostatic urethral abnormalities.<sup>11</sup>

## En Bloc Resection of Bladder Tumor (ERBT) Technique

ERBT is a relatively new but well-established technique, supported by comprehensive protocols.<sup>100</sup> It can be performed using a variety of instruments. The procedure begins with creating a circumferential incision approximately 5 mm from the tumor edge, deep to the muscularis mucosa layer, followed by the separation of the tumor from the surrounding tissue toward the center.<sup>101</sup> The primary goal of ERBT is to avoid tumor fragmentation by removing the tumor in one piece, ensuring clear margins and minimizing the risk of leaving residual disease. This approach adheres strictly to oncological principles, preventing the spread of floating cancer cells and enabling more accurate and reliable pathological staging,<sup>61,102</sup> reducing the risk of understaging<sup>103,104</sup> and improving predictions of disease progression.<sup>61,105</sup> Moreover, it helps ensure that DM is present in the specimen, which is crucial for improving oncological outcomes.

A review of the literature, including nine randomized controlled trials (RCTs) and several systematic reviews, demonstrates that ERBT is significantly safer, with fewer complications such as perforation and ONR.<sup>69,101,106–111</sup> Residual disease at the first follow-up cystoscopy or re-TURBT is also less frequent with ERBT.<sup>106–109,112</sup> While older studies showed similar recurrence rates between ERBT and traditional TURBT, more recent studies indicate better outcomes with ERBT, including a higher presence of DM in specimens and shorter hospitalization times.<sup>106,107,110,111</sup> However, the impact of ERBT on recurrence rates remains conflicting.<sup>101,106–112</sup>

While the extraction of large tumors through the urethra presents significant challenges,<sup>113</sup> a comprehensive collaborative statement has deemed en bloc resection feasible for tumors exceeding 3 cm in diameter.<sup>101</sup> Approaches to address this issue include utilizing specialized retrieval bags to extract the tumor's water component<sup>114</sup> or employing laparoscopic forceps to remove the detached specimen.<sup>115</sup> Alternative strategies involve morcellation of the exophytic portion of the tumor prior to ERBT of the tumor base, enabling more precise pathological examination of tumor base margins, or segmenting the whole specimen of broad-based tumors into two or three parts.<sup>101</sup> Due to these challenges,

**Table 1** Summary of Evidence on ERBT Outcomes Compared to Conventional TURBT

Outcomes ERBT Seems to Have no Effect	Outcomes with Uncertainty Regard ERBT Effect	Outcomes ERBT Seems to Improve	Outcomes that ERBT has yet to be Studied
Operative time <sup>107,109–111,129</sup>	Recurrence-free survival (RFS) in 3, 6 and 12 months <sup>101,106–112</sup>	Obturator nerve reflex (ONR) <sup>69,107,109–111,129</sup>	Progression-free survival (PFS)
Risk of urethral stricture <sup>130,131</sup>	Catheterization time <sup>107,109–111,129</sup>	Bladder perforation <sup>69,106–112,129</sup>	Overall survival
	Irrigation time <sup>109–111,129</sup>	Higher rates of detrusor muscle in specimen <sup>107,112,129</sup>	
		Less frequent residual disease in first follow up <sup>69,106–109,112</sup>	
		Hospitalization time <sup>107,109–111,129</sup>	

**Notes:** However, the use of laser-assisted techniques in conjunction with ERBT has been shown to improve recurrence-free survival (RFS) and reduce hospitalization duration, without significantly impact on operative time or the risk of urethral stricture formation.

most larger studies have focused on tumors with diameters of less than 3 cm, potentially introducing bias in favor of ERBT, but few studies have demonstrated improved safety and efficacy of ERBT compared to conventional TURBT, even for tumors larger than 3 cm.<sup>116,117</sup>

Bipolar energy is the most commonly used energy source for ERBT.<sup>118</sup> Some studies report no significant difference between energy sources,<sup>119</sup> while others suggest that lasers, particularly thulium-based lasers, may offer superior safety and efficacy.<sup>108,120–125</sup> However, further discussion of these considerations is beyond the scope of this review.<sup>93</sup>

ERBT is estimated to be performed daily by about two-thirds of surgeons, with approximately half of them using the technique whenever feasible.<sup>118,126</sup> However, its use varies and is difficult to quantify.<sup>127</sup> The learning curve for ERBT is estimated to be around 13–20 procedures, depending on the surgeon's experience.<sup>100,128</sup> While the current AUA guidelines do not address ERBT,<sup>10</sup> the EAU guidelines mention ERBT as an option that increases the likelihood of obtaining DM in specimens, though it is not yet fully recommended.<sup>11</sup> Based on existing evidence, ERBT appears to be a safer and potentially more effective surgical approach when feasible, see Table 1.

## Energy Source and Enhanced Cystoscopy

### Comparison of Monopolar and Bipolar Electrocautery in TURBT

TURBT is typically performed using either monopolar or bipolar electrocautery. Monopolar electrocautery uses high voltage for tissue cutting, requiring current to flow from the resection electrode through the patient's body to a skin electrode, along with hypotonic fluid for irrigation. Bipolar TURBT confines energy between electrodes at the resectoscope site, allowing the use of a physiological irrigation medium and lower energy sources, which may reduce the risk of complications such as TUR syndrome.

While some studies favor bipolar TURBT for its reduced complications, the differences in outcomes like perforation rates, hospitalization time, catheterization time, and hemoglobin drop often lack statistical significance.<sup>132–142</sup> Although bipolar energy may result in better DM sampling<sup>140,142</sup> and less thermal damage to surrounding tissue,<sup>136–138</sup> there is no clear advantage in oncological outcomes such as recurrence rates. However, bipolar TURBT may yield better results for tumors larger than 3 cm.<sup>143</sup> The EAU summarizes the current evidence as controversial and inconclusive. The AUA states that bipolar electrocautery “may serve to enhance complete resection and reduce complications”.

### Advantages of LASER in TURBT Procedures

Laser technology has become highly regarded in urology due to its precision and versatility in treating various conditions. Lasers provide highly targeted energy, allowing for the precise cutting or ablation of tumor tissue while minimizing damage to surrounding healthy areas. This precision is especially advantageous in delicate surgeries like TURBT, where preserving

healthy bladder tissue is critical. In addition, lasers offer superior hemostatic properties, reducing intraoperative bleeding,<sup>144,145</sup> which enhances surgical visibility and lowers the risk of complications. The minimally invasive nature of laser procedures also contributes to faster recovery times, shorter hospital stays,<sup>130,131,146–150</sup> and less postoperative pain,<sup>145</sup> making laser an appealing tool in modern urological practices.

However, laser technology has its drawbacks. One of the main limitations is cost—laser equipment is more expensive to acquire and maintain than traditional TURBT equipment. Laser procedures may also have a steeper learning curve for surgeons accustomed to traditional methods, requiring specialized training to ensure optimal outcomes. While it might be expected that laser use would increase operating time, most studies have not found a significant increase in procedure duration.<sup>129–131,146,147,150</sup>

Multiple studies and meta-analyses have demonstrated that laser TURBT, whether used with ERBT or conventional TURBT techniques, results in similar outcomes but with significantly lower rates of ONR and bladder perforation. Laser TURBT is also associated with reduced hospitalization, catheterization, and irrigation times compared to conventional TURBT.<sup>130,131,146–150</sup> However, evidence on laser technology's effect on recurrence rates remains inconclusive. The EAU guidelines mention laser use as a feasible alternative to electrocautery, while the AUA does not reference it. Current evidence suggests that laser technology is a safer and efficient tool, likely to be preferred when available.

## Photodynamic Diagnosis (PDD) in TURBT

PDD enhances the detection of bladder tumors, particularly CIS, which are not easily identified through standard cystoscopy.<sup>74,151</sup> PDD involves intravesical administration of a photosensitizing agent that accumulates in tumor cells, causing them to fluoresce under specific wavelengths of light. The most widely studied photosensitizer for bladder cancer is hexaminolevulinic acid (HAL).<sup>74</sup> PDD has demonstrated advantages over white-light cystoscopy, with improved detection rates for papillary tumors (7–35.2%)<sup>152,153</sup> and CIS (20–40.7%).<sup>154,155</sup> Sensitivity rates of 90.1–95% have been reported.<sup>152,153,155</sup>

PDD has also shown a reduction in recurrence rates compared to standard cystoscopy, with recurrence rates reduced from 18% to 14%.<sup>154</sup> Estimates of recurrence rates in studies using PDD range from 19.8% to 37.2%.<sup>156–158</sup> However, PDD has a relatively high false-positive rate, ranging from 1% to 26%.<sup>159</sup> Despite its diagnostic benefits, PDD does not replace the need for other treatments, such as Bacillus Calmette–Guérin (BCG) therapy, particularly for high-risk cases.<sup>160</sup>

The EAU guidelines recommend PDD during TURBT, if available.<sup>11</sup> The AUA suggests offering PDD (often referred to as blue-light cystoscopy or BLC) at TURBT and considering its use in patients with positive cytology and normal cystoscopy findings.<sup>10</sup>

## Narrow Band Imaging (NBI)

NBI enhances the visualization of bladder tumors by filtering light into blue and green wavelengths, which highlight blood vessels at different tissue depths. This enhances differentiation between normal and tumor tissue.<sup>161</sup> NBI was originally developed for gastrointestinal endoscopy<sup>162</sup> but has since been adapted for urological applications.

Most studies, including meta-analyses, have shown that NBI improves tumor detection rates when combined with WLC.<sup>155,161,163–169</sup> NBI has been particularly effective in detecting CIS,<sup>168,170,171</sup> with approximately 10% more bladder cancer patients being diagnosed with NBI than with standard WLC.<sup>170</sup>

However, the influence of NBI on recurrence rates remains mixed. Some studies have demonstrated significant improvements in recurrence rates at 3 and 12 months.<sup>169,171–173</sup> For instance, one systematic review and meta-analysis reported a hazard ratio (HR) of 0.63 for NBI compared to WLC.<sup>172</sup> However, other studies have found no significant differences, particularly in long-term follow-up.<sup>164,174–176</sup> Some have suggested that the addition of BCG may influence outcomes,<sup>171</sup> though further research is needed to clarify this effect. Notably, even in studies that did not show overall benefits, patients with low-risk tumors (TaG1, <3 cm) benefited from NBI, with 5.6% recurrence at 12 months compared to 27.3% with standard TURBT.<sup>174</sup>



Studies on PFS and OS with NBI are similarly inconclusive.<sup>171,172,177</sup> One recent Cochrane review found no difference in adverse events between NBI and WLC, despite concerns that higher false-positive rates might lead to overtreatment.<sup>172</sup>

Few studies have directly compared PDD and NBI. A study by Drejer et al<sup>163</sup> conducted in 2017 on 136 patients found no significant differences between the two imaging techniques, which was consistent with findings from a later meta-analysis<sup>171</sup> in 2023. However, other meta-analysis suggested that 5-aminolevulinic acid (5-ALA) might have a lower recurrence rate compared to HAL (OR for recurrence in 5-ALA compared to HAL was 0.48, 95% CI [0.26–0.95]), but the superiority over NBI was insignificant (OR= 0.53, 95% CI [0.26–1.09]).<sup>177</sup>

The specificity of different imaging methods remains controversial. While some researchers<sup>171</sup> found that NBI had better specificity (similar to WLC, at 0.76) compared to PDD, Others<sup>178</sup> reported the opposite findings. Moreover, Chen et al observed that NBI had higher diagnostic accuracy, even after omitting studies with high risk of bias and those with less than 100 patients.<sup>179</sup> On the other hand, some studies found PDD to be significantly more sensitive in a retrospective study of 114 patients.<sup>180</sup>

More importantly, uncertainty persists regarding the oncological impact of NBI. While meta-analyses of RCTs suggest an insignificant advantage of HAL over NBI, the cost-effectiveness of NBI is in question, particularly when considering its use in routine practice.<sup>181</sup> Further complicating the decision between these methods is the need for instillation of a photosensitizing agent in PDD, which introduces additional costs and logistical considerations. Moreover, the reduced specificity of PDD after recent intravesical therapy (39.6% false positive rate for biopsy within six months, compared to 25.7% in patients who never underwent intravesical therapy) is a concern.<sup>182</sup>

In summary, NBI generally provides better detection rates and diagnostic accuracy and likely reduces recurrence at 12 months. However, further studies are required to assess its long-term effects on RFS, PFS, and OS. Additionally, there is a need for direct head-to-head comparisons between imaging techniques to establish clearer guidelines for their use.

The EAU guidelines weakly recommend the use of enhanced tumor visualization methods (PDD, NBI) during TURBT, if available.<sup>11</sup> The AUA guidelines suggest offering BLC or considering NBI during TURBT, and also consider BLC (along with urethral and random biopsies) in patients with positive cytology but normal-appearing cystoscopy.<sup>10</sup>

## SPIES - IMAGE1 S (Formerly SPIES)

The “IMAGE1 S™” system is a software that processes cystoscopy images to create enhanced contrast without the need for physical filters,<sup>183</sup> which may reduce costs associated with expensive equipment. Early studies suggested that this system could improve diagnostic accuracy.<sup>184,185</sup> However, evidence regarding its overall impact remains limited.

One RCT found no significant differences in recurrence rates between groups at 18 months, except for low- to intermediate-risk primary tumors ( $p=0.035$ ) and borderline effects in low- to intermediate-risk patients ( $p=0.068$ ).<sup>186</sup> A recently published blinded RCT with 12-month follow-up ( $n=103$ ) showed lower recurrence rates for the IMAGE1 S group (12.2% vs 25.9%,  $P=.080$ ). Recurrence rates in low- and intermediate-risk groups were significantly lower (7.7% vs 30.8%,  $P=.003$ ), and RFS was higher in the IMAGE1 S group (85.2% vs 62.8%, Log Rank: 0.021, HR=0.215). However, no differences were observed in high- and very-high-risk groups. Complications were primarily grade I and occurred more frequently with IMAGE1 S (20.4% vs 7.4%,  $P=.083$ ).<sup>187</sup>

These findings leave an open question regarding whether IMAGE1 S can effectively reduce recurrence rates, especially in low- to intermediate-risk patients, and its potential to reduce the personal and economic burden of bladder cancer.

## Future Directions

There are still many open questions regarding the integration of different imaging techniques and TURBT. For example, is restaging TURBT necessary when advanced imaging modalities and improved surgical techniques have already been used in the initial procedure? We look forward to future prospective studies to explore these questions. We also anticipate more extensive use of simulators and training programs to enhance the competency of new urologists. The role of artificial intelligence (AI) in interpreting cystoscopy images has been studied in multiple works, with high diagnostic accuracy.<sup>188–190</sup> Other AI models showed performance equivalent to expert interpretation, with faster image

recognition.<sup>191,192</sup> These models still need to undergo prospective randomized trials and will likely require modifications for continuous video analysis. However, once fully operational, AI could revolutionize TURBT and cystoscopy.

Other intriguing developments include the “closing the loop” concept, with autonomous cystoscopy monitored by non-urologist staff,<sup>193</sup> as described by O’Sullivan in 2022. Although this approach is still in its early stages, it represents a promising direction for the future.

In other aspects of bladder cancer management, AI models are expected to play a more prominent role soon. These models may improve cytology accuracy,<sup>17,194,195</sup> as seen in studies like Lebrete’s 2022 analysis and Sokolov’s 2018 research. AI also shows promise in pathology interpretation, with models like those developed by Abuhasenin<sup>196</sup> for staging accuracy based on CTU images, or Qureshi’s 2024 MRI+mRNA marker model.<sup>197</sup>

Similarly, AI is being used to develop biomarkers to predict recurrence and progression. These include genomic and pathological biomarkers,<sup>198</sup> as demonstrated by Tokuyama in 2022, and models based on clinical data,<sup>199,200</sup> as reported by Sluzarczyk in 2023 and Lucas in 2022. These predictive tools will play a key role in personalizing treatment, helping clinicians identify patients who need more aggressive treatments while sparing others from unnecessary interventions. However, these models are yet to be validated in prospective trials, and the effect of their integration into traditional decision-making processes on oncological outcomes remains unknown.

Urine biomarkers also represent a rapidly advancing area, especially for surveillance,<sup>11,201,202</sup> as shown in Singer’s 2023 study. Such markers could eventually guide more personalized therapy, improving treatment outcomes for patients with bladder cancer. Advances in tumor classification, as mentioned by Teoh in 2022,<sup>183</sup> will also contribute to more tailored treatment approaches.

Emerging advancements from related fields, such as gastroenterological surgery, offer promising directions for urological innovation. Techniques like NBI and machine learning were already discussed earlier. Additionally, the integration of ultrasound technologies, particularly endoscopic ultrasound (EUS), could significantly enhance bladder cancer management. EUS can aid in tumor localization, assessment of invasion depth in suspected MIBC, and planning the extent of resection for large tumors. Innovative methods for bleeding control, such as injection therapy, in addition to thermal coagulation, also warrant exploration. Furthermore, genomic profiling of tumors could provide valuable insights for treatment planning, including decisions regarding adjuvant therapy. Techniques involving tissue ablation, such as argon plasma coagulation, heater probes, cryoablation, and radiofrequency or microwave ablation, present additional opportunities. These modalities could be utilized for achieving hemostasis or in palliative care settings where pathological examination is not required. Their application in managing recurrent LG NMIBC will remain outside the scope of this review. These emerging approaches could complement established energy sources, including bipolar technology, laser systems, and hydrodissection. We expect that a multidisciplinary approach to urological procedures would add to collaboration and innovation, ultimately improving TURBT and other related interventions.

## Conclusions

TURBT remains the cornerstone of NMIBC diagnosis and treatment. The integration of enhanced imaging techniques such as PDD, NBI, and ERBT, alongside AI and biomarker advancements, promises to revolutionize patient outcomes by improving diagnostic accuracy and reducing recurrence rates. Surgeon experience and quality measures such as surgical checklists will continue to play an important role. Future research should explore the combined use of advanced diagnostic modalities and assess their long-term effects on oncological outcomes. With these innovations, bladder cancer management stands on the brink of a new era in precision medicine.

## Disclosure

The authors report no conflicts of interest in this work.

## References

1. Sung H, Ferlay J, Siegel RL, et al. Global cancer statistics 2020: GLOBOCAN estimates of incidence and mortality worldwide for 36 cancers in 185 countries. *Ca A Cancer J Clin.* 2021;71(3):209–249. doi:10.3322/caac.21660
2. Siegel RL, Miller KD, Jemal A. Cancer statistics, 2015. *Ca A Cancer J Clin.* 2015;65(1):5–29. doi:10.3322/caac.21254

3. Catto JWF, Downing A, Mason S. Quality of life after bladder cancer: a cross-sectional survey of patient-reported outcomes. *Eur Urol.* 2021;79(5):621–632. doi:10.1016/j.eururo.2021.01.032
4. Lee LJ, Kwon CS, Forsythe A, Mamolo CM, Masters ET, Jacobs IA. Humanistic and economic burden of non-muscle invasive bladder cancer: results of two systematic literature reviews. *Clinicoecon Outcomes Res.* 2020;12:693–709. doi:10.2147/CEOR.S274951
5. Rogers Z, Glaser A, Catto JWF. Health-related quality of life after a diagnosis of bladder cancer: a longitudinal survey over the first year. *BJU Int.* 2024;133(4):460–473. doi:10.1111/bju.16242
6. Botteman MF, Pashos CL, Redaelli A, Laskin B, Hauser R. The health economics of bladder cancer. *Pharmacoeconomic.* 2003;21(18):1315–1330. doi:10.1007/BF03262330
7. Sievert KD, Amend B, Nagele U. Economic aspects of bladder cancer: what are the benefits and costs? *World J Urol.* 2009;27:295–300 doi: 10.1007/s00345-009-0395-z.
8. Aldousari S, Kassouf W. Update on the management of non-muscle invasive bladder cancer. *Can Urol Assoc J.* 2010;4(1):56–64. doi:10.5489/cuaj.777
9. Nielsen ME, Smith AB, Meyer A-M. Trends in stage-specific incidence rates for urothelial carcinoma of the bladder in the United States: 1988 to 2006. *Cancer.* 2014;120(1):86–95. doi:10.1002/cncr.28397
10. Bladder cancer: non-muscle invasive guideline - American urological association [Internet]. [cited 2023 Jun 18]. Available from: <https://www.auanet.org/guidelines-and-quality/guidelines/bladder-cancer-non-muscle-invasive-guideline>. Accessed February 06, 2025.
11. Babjuk M, Burger M, Compérat E, et al. EAU guidelines on non-muscle-invasive bladder cancer (TaT1 and CIS). *Invasive Bladder Cancer.* 2024;71:447–61.
12. Cookson MS, Herr HW, Zhang ZF, Soloway S, Sogani PC, Fair WR. The treated natural history of high risk superficial bladder cancer: 15-year outcome. *J Urol.* 1997;158(1):62–67. doi:10.1097/00005392-199707000-00017
13. Palou J, Sylvester RJ, Faba OR. Female gender and carcinoma in situ in the prostatic urethra are prognostic factors for recurrence, progression, and disease-specific mortality in T1G3 bladder cancer patients treated with bacillus Calmette-Guerin. *Europ urol.* 2012;62(1):118–125. doi:10.1016/j.eururo.2011.10.029
14. Sylvester RJ, van der Meijden APM, Oosterlinck W. Predicting recurrence and progression in individual patients with stage Ta T1 bladder cancer using EORTC risk tables: a combined analysis of 2596 patients from seven EORTC trials. *Europ Urol.* 2006;49:466–477 doi: 10.1016/j.eururo.2005.12.031.
15. Brausi M, Collette L, Kurth K. Variability in the recurrence rate at first follow-up cystoscopy after TUR in stage Ta T1 transitional cell carcinoma of the bladder: a combined analysis of seven EORTC studies. *Europ urol.* 2002;41(5):523–531. doi:10.1016/S0302-2838(02)00068-4
16. Yafi FA, Brimo F, Steinberg J, Aprikian AG, Tanguay S, Kassouf W. Prospective analysis of sensitivity and specificity of urinary cytology and other urinary biomarkers for bladder cancer. *Urol Oncol.* 2015;33(2):66.e25–31. doi:10.1016/j.urolonc.2014.06.008
17. Lebre T, Pignot G, Colombel M. Artificial intelligence to improve cytology performances in bladder carcinoma detection: results of the VisioCyt test. *BJU Int.* 2022;129(3):356–363. doi:10.1111/bju.15382
18. Raitanen M-P, Aine R, Rintala E. Differences between local and review urinary cytology in diagnosis of bladder cancer. An interobserver multicenter analysis. *Eur Urol.* 2002;41(3):284–289. doi:10.1016/S0302-2838(02)00006-4
19. Tan WS, Sarpong R, Khetrapal P. Can renal and bladder ultrasound replace computerized tomography urogram in patients investigated for microscopic hematuria? *J Urol.* 2018;200(5):973–980. doi:10.1016/j.juro.2018.04.065
20. Tan WS, Feber A, Sarpong R. Who should be investigated for haematuria? Results of a contemporary prospective observational study of 3556 patients. *Europ Urol.* 2018;74(1):10–14. doi:10.1016/j.eururo.2018.03.008
21. Palou J, Rodríguez-Rubio F, Huguet J. Multivariate analysis of clinical parameters of synchronous primary superficial bladder cancer and upper urinary tract tumor. *J Urol.* 2005;174(3):859–861. (). doi:10.1097/01.ju.0000169424.79702.6d
22. Millán-Rodríguez F, Chéchile-Toniolo G, Salvador-Bayarri J, Huguet-Pérez J, Vicente-Rodríguez J. Upper urinary tract tumors after primary superficial bladder tumors: prognostic factors and risk groups. *J Urol.* 2000;164(4):1183–1187. doi:10.1016/S0022-5347(05)67137-6
23. Erkok M, Otunctemur A, Bozkurt M. The efficacy and reliability of VI-RADS in determining candidates for repeated transurethral resection in patients with high-risk non-muscle invasive bladder cancer. *Int J Clin Pract.* 2021;75(9):e14584. doi:10.1111/ijcp.14584
24. Gandhi N, Krishna S, Booth CM. Diagnostic accuracy of magnetic resonance imaging for tumour staging of bladder cancer: systematic review and meta-analysis. *BJU Int.* 2018;122(5):744–753. doi:10.1111/bju.14366
25. Woo S, Panebianco V, Narumi Y. diagnostic performance of vesical imaging reporting and data system for the prediction of muscle-invasive bladder cancer: a systematic review and meta-analysis. *Eur Urol Oncol.* 2020;3(3):306–315. doi:10.1016/j.euo.2020.02.007
26. Carando R, Afferi L, Marra G. The effectiveness of multiparametric magnetic resonance imaging in bladder cancer (vesical imaging-reporting and data system): a systematic review. *Arab J Urol.* 2020;18(2):67–71. doi:10.1080/2090598X.2020.1733818
27. Del Giudice F, Flammia RS, Pecoraro M. The accuracy of vesical imaging-reporting and data system (VI-RADS): an updated comprehensive multi-institutional, multi-readers systematic review and meta-analysis from diagnostic evidence into future clinical recommendations. *World J Urol.* 2022;40(7):1617–1628. doi:10.1007/s00345-022-03969-6
28. Jazayeri SB, Dehghanbanadaki H, Hosseini M. Diagnostic accuracy of vesical imaging-reporting and data system (VI-RADS) in suspected muscle invasive bladder cancer: a systematic review and diagnostic meta-analysis. *Urol Oncol.* 2022;40(2):45–55. doi:10.1016/j.urolonc.2021.11.008
29. James N, Pirrie S, Liu W, et al. Image directed redesign of bladder cancer treatment pathways: the BladderPath RCT. *Health Technol Assess.* 2024;28(42):1–65.
30. Ko K. Chapter 5 - Physical Examination. In: Ku JH, editor. *Bladder Cancer*. Academic Press; 2018:57–65.
31. Wijkström N, Lagerkvist N, Näslund W. Evaluation of clinical staging before cystectomy in transitional cell bladder carcinoma: a long-term follow-up of 276 consecutive patients. *Br J Urol.* 1998;81(5):686–691. doi:10.1046/j.1464-410x.1998.00637.x
32. Ploeg M, Kiemeny LALM, Smits GA. Discrepancy between clinical staging through bimanual palpation and pathological staging after cystectomy. *J Urol Oncol.* 2012;30(3):247–251. doi:10.1016/j.urolonc.2009.12.020
33. Rozanski AT, Benson CR, McCoy JA. Is exam under anesthesia still necessary for the staging of bladder cancer in the era of modern imaging? *Bladder Cancer.* 2015;1(1):91–96. doi:10.3233/BLC-150006

34. Mehrsai A, Mansoori D, Taheri mahmoudi M, Sina A, Seraji A, Pourmand GH. A comparison between clinical and pathologic staging in patients with bladder cancer. *Urol J*. 2004;1(2):85–89.
35. Mariappan P, Lavin V, Phua CQ, Khan SAA, Donat R, Smith G. Predicting grade and stage at cystoscopy in newly presenting bladder cancers—a prospective double-blind clinical study. *Urology*. 2017;109:134–139. doi:10.1016/j.urology.2017.08.007
36. During V, Sole G, Jha A, Anderson J, Bryan R. Prediction of histological stage based on cystoscopic appearances of newly diagnosed bladder tumours. *Annals*. 2016;98(8):547–551. doi:10.1308/rcsann.2016.0246
37. Vale L, Sousa J, Abreu-Mendes P. The value of surgeon's perception during transurethral resection of bladder tumors: can we trust in our eyes and experience to predict grade and staging? *Porto Biomed J*. 2022;7:e179 doi: 10.1097/j.pbj.0000000000000179.
38. Herr HW, Donat SM, Dalbagni G. Correlation of cystoscopy with histology of recurrent papillary tumors of the bladder. *J Urol*. 2002;168(3):978–980. doi:10.1016/S0022-5347(05)64555-7
39. Mostafid H, Kamat AM, Daneshmand S. Best practices to optimise quality and outcomes of transurethral resection of bladder tumours. *Eur Urol Oncol*. 2021;4(1):12–19. doi:10.1016/j.euo.2020.06.010
40. Choi W-J, Baek S, Joo E-Y. Comparison of the effect of spinal anesthesia and general anesthesia on 5-year tumor recurrence rates after transurethral resection of bladder tumors. *Oncotarget*. 2017;8(50):87667–87674. doi:10.18632/oncotarget.21034
41. Erbay G, Akyol F, Karabakan M, Celebi B, Keskin E, Hirik E. Effect of obturator nerve block during transurethral resection of lateral bladder wall tumors on the presence of detrusor muscle in tumor specimens and recurrence of the disease. *Kaohsiung J Med Sci*. 2017;33(2):86–90. doi:10.1016/j.kjms.2016.11.006
42. Doluoglu OG, Yildiz AK, Kacan T, Bayburtluoglu V, Bektas M, Ozgur BC. Efficacy of obturator nerve block during transurethral resection on non-muscle invasive intermediate and high risk lateral wall bladder tumours: a prospective randomized controlled study. *Urol J*. 2022;19(6):445–450. doi:10.22037/uj.v18i.6953
43. Deng W, Zhang Q, Yao H. A systematic review and meta-analysis comparing the safety and efficacy of spinal anesthesia and spinal anesthesia combined with obturator nerve block in transurethral resection of bladder tumors. *Emerg Med Int*. 2022;2022:8490462.
44. Montgomery JS, Miller DC, Weizer AZ. Quality indicators in the management of bladder cancer. *J National Compr Cancer Network*. 2013;11(4):492–500. doi:10.6004/jnccn.2013.0061
45. Mariappan P, Johnston A, Padovani L. Enhanced quality and effectiveness of transurethral resection of bladder tumour in non-muscle-invasive bladder cancer: a multicentre real-world experience from scotland's quality performance indicators programme. *Europ urol*. 2020;78(4):520–530. doi:10.1016/j.eururo.2020.06.051
46. Muilwijk T, Akand M, Raskin Y. Quality control indicators for transurethral resection of bladder tumor: results from an embedded Belgian multicenter prospective registry. *Eur Urol Oncol*. 2023;6(4):422–430. doi:10.1016/j.euo.2022.11.005
47. Akand M, Muilwijk T, Raskin Y, Vrieze MD, Joniau S, Aa FVD. Quality control indicators for transurethral resection of non-muscle-invasive bladder cancer. *Clinical Genitourinary Cancer*. 2019;17(4):e784–92. doi:10.1016/j.clgc.2019.04.014
48. Ristau BT, Smaldone MC. Performance measurement and quality improvement initiatives for bladder cancer care. *Curr Urol Rep*. 2018;19(12):100.
49. Mariappan P, Zachou A, Grigor KM. Detrusor muscle in the first, apparently complete transurethral resection of bladder tumour specimen is a surrogate marker of resection quality, predicts risk of early recurrence, and is dependent on operator experience. *Europ Urol*. 2010;57(5):843–849. doi:10.1016/j.eururo.2009.05.047
50. Mariappan P, Finney SM, Head E. Good quality white-light transurethral resection of bladder tumours (GQ-WLTURBT) with experienced surgeons performing complete resections and obtaining detrusor muscle reduces early recurrence in new non-muscle-invasive bladder cancer: validation across time and place and recommendation for benchmarking. *BJU Int*. 2012;109(11):1666–1673. doi:10.1111/j.1464-410X.2011.10571.x
51. Huang J, Fu J, Zhan H. Analysis of the absence of the detrusor muscle in initial transurethral resected specimens and the presence of residual tumor tissue. *Urol Int*. 2012;89(3):319–325. doi:10.1159/000341103
52. Rouprêt M, Yates DR, Varinot J. The presence of detrusor muscle in the pathological specimen after transurethral resection of primary pT1 bladder tumors and its relationship to operator experience. *Can J Urol*. 2012;19(5):6459–6464.
53. Czech AK, Gronostaj K, Frydrych J. Identification of potential prognostic factors for absence of residual disease in the second resection of T1 bladder cancer. *Cent Eur J Urol*. 2019;72(3):252–257. doi:10.5173/cej.2019.1908
54. Shindo T, Masumori N, Kitamura H. Clinical significance of definite muscle layer in TUR specimen for evaluating progression rate in T1G3 bladder cancer: multicenter retrospective study by the Sapporo medical university urologic oncology consortium (SUOC). *World J Urol*. 2014;32(5):1281–1285. doi:10.1007/s00345-013-1205-1
55. Volz Y, Trappmann R, Ebner B. Absence of detrusor muscle in TUR-BT specimen – can we predict who is at highest risk? *BMC Urol*. 2023;23:106. doi:10.1186/s12894-023-01278-7
56. Mariappan P, Johnston A, Trail M, et al. Achieving benchmarks for national quality indicators reduces recurrence and progression in non-muscle-invasive bladder cancer. *Eur Urol Oncol*. 2024;S2588–9311(24)00037–3.
57. Palou J, Pisano F, Sylvester R. Recurrence, progression and cancer-specific mortality according to stage at re-TUR in T1G3 bladder cancer patients treated with BCG: not as bad as previously thought. *World J Urol*. 2018;36(10):1621–1627. doi:10.1007/s00345-018-2299-2
58. Volz Y, Trappmann R, Ebner B. Upstaging after transurethral resection of the bladder for non-muscle-invasive cancer of the bladder: who is at highest risk? *Urol Int*. 2024;108(1):42–48. doi:10.1159/000535024
59. Baird B, Bilgili A, Anderson A. Oncological outcomes of visibly complete transurethral resection prior to neoadjuvant chemotherapy for bladder cancer. *Int Braz J Urol*. 2023;49(4):479–489. doi:10.1590/S1677-5538.IBJU.2023.0123
60. Jancke G, Rosell J, Jahnsen S. Residual tumour in the marginal resection after a complete transurethral resection is associated with local recurrence in Ta/T1 urinary bladder cancer. *Scand J Urol*. 2012;46(5):343–347. doi:10.3109/00365599.2012.684700
61. Yanagisawa T, Miki J, Yorozu T, et al. Vertical lamina propria invasion diagnosed by en bloc transurethral resection is a significant predictor of progression for pT1 bladder cancer. *J Urol*. 2021; 205(6):1622–8.
62. Eissa A, Zoeir A, Ciarlariello S. En-bloc resection of bladder tumors for pathological staging: the value of lateral margins analysis. *Minerva Urol Nefrol*. 2020;72(6):763–769. doi:10.23736/S0393-2249.20.03551-1



63. Wettstein MS, Pham S, Qadri SR, et al. Association between surgical case volume and survival in T1 bladder cancer: a need for centralization of care? *Can Urol Assoc J*. 2020;14(9):E394–401.
64. Bos D, Allard CB, Dason S, Ruzhynsky V, Kapoor A, Shayegan B. Impact of resident involvement in endoscopic bladder cancer surgery on pathological outcomes. *Scand J Urol*. 2016;50(3):234–238. doi:10.3109/21681805.2016.1163616
65. Ali MH, Eltobgy A, Ismail IY, Ghobish A. Role of surgeon experience in the outcome of transurethral resection of bladder tumors. *Urol Ann*. 2020;12(4):341–346. doi:10.4103/UA.UA\_138\_19
66. Bube SH, Brix R, Christensen MB. Surgical experience is predictive for bladder tumour resection quality. *Scand J Urol*. 2022;56:391–396 doi:10.1080/21681805.2022.2119271.
67. Bebane S, Denize J, Goujon A. Perioperative outcomes of transurethral resection for t1 bladder tumors: quality evaluation based on patient, tumor and surgeon criteria. *World J Urol*. 2021;39(11):4159–4165. doi:10.1007/s00345-021-03765-8
68. Poletajew S, Krajewski W, Kaczmarek K. The learning curve for transurethral resection of bladder tumour: how many is enough to be independent, safe and effective surgeon? *J Surg Edu*. 2020;77(4):978–985. doi:10.1016/j.jsurg.2020.02.010
69. Yanagisawa T, Kawada T, von Deimling M. Repeat transurethral resection for non-muscle-invasive bladder cancer: an updated systematic review and meta-analysis in the contemporary era. *Eur Urol Focus*. 2024;10(1):41–56. doi:10.1016/j.euf.2023.07.002
70. Zurkirchen MA, Sulser T, Gaspert A, Hauri D. Second transurethral resection of superficial transitional cell carcinoma of the bladder: a must even for experienced urologists. *Urol Int*. 2004;72(2):99–102. doi:10.1159/000075961
71. Shoshany O, Mano R, Margel D, Baniel J, Yossepowitch O. Presence of detrusor muscle in bladder tumor specimens—predictors and effect on outcome as a measure of resection quality. *J Urol Oncol*. 2014;32(1):40.e17–40.e22. doi:10.1016/j.urolonc.2013.04.009
72. Chang DTS, Picardo A. Repeat transurethral resection is still an essential tool in treating non-muscle invasive bladder cancer: the Western Australian experience. *Bladder*. 2020;7(2):e42. doi:10.14440/bladder.2020.814
73. Del Giudice F, D'Andrea D, Pradere B. Surgical checklist adherence across urology expertise levels impacts transurethral resection of bladder tumour quality indicators. *BJU Int*. 2023;131(6):712–719. doi:10.1111/bju.15920
74. Kim LHC, Patel MI. Transurethral resection of bladder tumour (TURBT). *Transl Androl Urol*. 2020;9(6):3056–3072. doi:10.21037/tau.2019.09.38
75. Yanagisawa T, Sato S, Hayashida Y. Clinical impact of detrusor muscle in en bloc resection for T1 bladder cancer. *J Urol Oncol*. 2023;41(12):484.e7–484.e15. doi:10.1016/j.urolonc.2023.08.004
76. de Vries AH, Muijtjens AMM, van Genugten HGJ. Development and validation of the TOCO-TURBT tool: a summative assessment tool that measures surgical competency in transurethral resection of bladder tumour. *Surg Endosc*. 2018;32(12):4923–4931. doi:10.1007/s00464-018-6251-8
77. Bube SH, Kingo PS, Madsen MG. Validation of a novel assessment tool identifying proficiency in transurethral bladder tumor resection: the OSATURBS assessment tool. *J Endourol*. 2022;36(4):572–579. doi:10.1089/end.2021.0768
78. Mariappan P. Attention to detail and a permissive set-up: crucial for an effective TURBT. *Nat Rev Urol*. 2021;18(5):253–254. doi:10.1038/s41585-021-00441-9
79. Haynes AB, Weiser TG, Berry WR. A surgical safety checklist to reduce morbidity and mortality in a global population. *N Engl J Med*. 2009;360(5):491–499. doi:10.1056/NEJMsa0810119
80. Patel J, Ahmed K, Guru KA. An overview of the use and implementation of checklists in surgical specialties – a systematic review. *Int J Surg*. 2014;12(12):1317–1323. doi:10.1016/j.ijsu.2014.10.031
81. Anderson C, Weber R, Patel D. A 10-item checklist improves reporting of critical procedural elements during transurethral resection of bladder tumor. *J Urol*. 2016;196(4):1014–1020. doi:10.1016/j.juro.2016.03.151
82. Taoka R, Tsunemori H, Matsuoka Y. Use of surgical checklist during transurethral resection increases detrusor muscle collection rate and improves recurrence-free survival in patients with non-muscle-invasive bladder cancer. *Int J Urol*. 2021;28(7):727–732. doi:10.1111/iju.14548
83. Guerero DN, Bruce A, Vayalapa S, Menon V, Hadi ME, Khashaba S. Improving the quality of transurethral resection of bladder tumour (TURBT) operative notes following the European association of urology guidelines: a completed audit loop study. *Cureus*. 2022;14:1
84. Dave P, Patel RD, Desai K, Davila J, Sankin A. A procedural checklist for transurethral resection of bladder tumors (TURBT) enhances operative dictation and assesses surgeon accuracy of tumor characteristic predictions. *Bladder Cancer*. 2023;9(4):335–344. doi:10.3233/BLC-230074
85. Suarez-Ibarrola R, Soria F, Abufaraj M. Surgical checklist impact on recurrence-free survival of patients with non-muscle-invasive bladder cancer undergoing transurethral resection of bladder tumour. *BJU Int*. 2019;123(4):646–650. doi:10.1111/bju.14557
86. Sörenby A, Baseckas G, Bendahl P-O. Reducing recurrence in non-muscle-invasive bladder cancer by systematically implementing guideline-based recommendations: effect of a prospective intervention in primary bladder cancer patients. *Scand J Urol*. 2019;53(2–3):109–115. doi:10.1080/21681805.2019.1604568
87. Kikuchi H, Osawa T, Abe T. Quality improvement in managing patients with non-muscle-invasive bladder cancer by introducing a surgical checklist for transurethral resection of bladder tumor. *PLoS One*. 2022;17(10):e0276816. doi:10.1371/journal.pone.0276816
88. Liu L, Li K, Wang SG, et al. The prognostic impact of tumor location in non-muscle-invasive bladder cancer patients undergoing transurethral resection: insights from a cohort study utilizing Chinese multicenter and SEER registries. *Int J Surg*. 2024;2024:10–97. doi:10.1097/JS9.0000000000001675.
89. Waseda Y, Kobayashi S, Kanda E. Impact of bladder neck involvement on recurrence in patients with non-muscle-invasive bladder cancer: an analysis based on a time-dependent model. *Clin Genitourin Cancer*. 2020;18(2):e62–70. doi:10.1016/j.clgc.2019.10.005
90. Fukushima H, Moriyama S, Waseda Y. Significance of bladder neck involvement in risk substratification of intermediate-risk non-muscle-invasive bladder cancer. *Eur Urol Focus*. 2021;7(2):366–372. doi:10.1016/j.euf.2020.01.006
91. Vukomanovic I, Colovic V, Soldatovic I, Hadzi-Djokic J. Prognostic significance of tumor location in high-grade non-muscle-invasive bladder cancer. *Med Oncol*. 2012;29(3):1916–1920. doi:10.1007/s12032-011-9999-4
92. Nakamura Y, Fukushima H, Yoshitomi K. Significance of dorsal bladder neck involvement in predicting the progression of non-muscle-invasive bladder cancer. *Int J Urol*. 2023;30(4):381–388. doi:10.1111/iju.15136
93. Nicoletti R, Gauhar V, Castellani D, Enikeev D, Herrmann TRW, Teoh JYC. Current techniques for en bloc transurethral resection of bladder tumor: a hands-on guide through the energy landscape. *Eur Urol Focus*. 2023;9(4):567–570. doi:10.1016/j.euf.2023.04.007
94. Taguchi I, Gohji K, Hara I. Clinical evaluation of random biopsy of urinary bladder in patients with superficial bladder cancer. *Int J Urol*. 1998;5(1):30–34. doi:10.1111/j.1442-2042.1998.tb00229.x

95. van der Meijden A, Oosterlinck W, Brausi M, Kurth KH, Sylvester R, de Balincourt C. Significance of bladder biopsies in Ta, T1 bladder tumors: a report from the EORTC Genito-Urinary Tract Cancer Cooperative Group. EORTC-GU group superficial bladder committee. *Eur Urol.* 1999;35(4):267–271. doi:10.1159/000019859
96. Hara T, Takahashi M, Gondo T. Risk of concomitant carcinoma in situ determining biopsy candidates among primary non-muscle-invasive bladder cancer patients: retrospective analysis of 173 Japanese cases. *Int J Urol.* 2009;16(3):293–298. doi:10.1111/j.1442-2042.2008.02241.x
97. Otsuka M, Taguchi S, Nakagawa T. Clinical significance of random bladder biopsy in primary T1 bladder cancer. *Mol Clin Oncol.* 2018;8(5):665–670. doi:10.3892/mco.2018.1587
98. Iinuma K, Yuhara K, Kotaka H. Preoperative predictive factors of carcinoma in situ in the normal-appearing mucosa in patients who underwent an initial transurethral resection for non-muscle-invasive bladder cancer under white light cystoscopy. *Cancer Rep.* 2021;4(2):e1321. doi:10.1002/cnr2.1321
99. Khan KS, Kunz R, Kleijnen J, Antes G. Five steps to conducting a systematic review. *J R Soc Med.* 2003;96(3):118–121. doi:10.1177/014107680309600304
100. Teoh JY-C, D'Andrea D, Gallioli A. En bloc resection of bladder tumour: the rebirth of past through reminiscence. *World J Urol.* 2023;41(10):2599–2606. doi:10.1007/s00345-023-04547-0
101. Teoh JY-C, MacLennan S, Chan VW-S. An international collaborative consensus statement on en bloc resection of bladder tumour incorporating two systematic reviews, a two-round delphi survey, and a consensus meeting. *Europ Urol.* 2022;78:546–569. doi: 10.1016/j.eururo.2020.04.059.
102. Guven S, Colecchia M, Oltulu P. How do endoscopic bladder tumor resection techniques affect pathology practice? EAU Section of Uro-Technology (ESUT) and Uro-pathology (ESUP) survey. *World J Urol.* 2023;41(10):2617–2625. doi:10.1007/s00345-022-04022-2
103. Gallioli A, Diana P, Fontana M. En Bloc versus conventional transurethral resection of bladder tumors: a single-center prospective randomized noninferiority trial. *Eur Urol Oncol.* 2022;5:440–448. doi: 10.1016/j.euo.2022.05.001.
104. Struck JP, Kramer MW, Katzendorn O. Bicentric retrospective analysis of en bloc resection and muscularis mucosae detection rate in non-muscle invasive bladder tumors: a real-world scenario. *Adv Ther.* 2021;38(1):258–267. doi:10.1007/s12325-020-01529-1
105. Sato S, Yanagisawa T, Miki J, et al. pT1 subclassification predicts progression-free survival in en bloc resection of bladder tumor specimens. *Arch Pathol Lab Med.* 2024;148(5):573–580. doi:10.5858/arpa.2023-0044-OA
106. Li DX, Yu QX, Wu RC, Wang J, Feng DC, Deng S. Efficiency of transurethral en-bloc resection vs. conventional transurethral resection for non-muscle-invasive bladder cancer: an umbrella review. *Cancer Med.* 2024;13(11):e7323. doi:10.1002/cam4.7323
107. Wang CW, Lee PJ, Wu CW, Ho CH. Comparison of pathological outcome and recurrence rate between en bloc transurethral resection of bladder tumor and conventional transurethral resection: a meta-analysis. *Cancers.* 2023;15(7):2055. doi:10.3390/cancers15072055
108. Sari Motlagh R, Rajwa P, Mori K. Comparison of clinicopathologic and oncological outcomes between transurethral en bloc resection and conventional transurethral resection of bladder tumor: a systematic review. Meta-analysis, and network meta-analysis with focus on different energy sources. *J Endourol.* 2022;36(4):535–547.
109. Li Z, Zhou Z, Cui Y, Zhang Y. Systematic review and meta-analysis of randomized controlled trials of perioperative outcomes and prognosis of transurethral en-bloc resection vs. conventional transurethral resection for non-muscle-invasive bladder cancer. *Int J Surg.* 2022;104:106777. doi:10.1016/j.ijsu.2022.106777
110. Yang Y, Liu C, Yang X, Wang D. Transurethral en bloc resection with monopolar current for non-muscle invasive bladder cancer based on TNM system. *Transl Cancer Res.* 2020;9(4):2210–2219. doi:10.21037/tcr.2020.03.48
111. Zhang D, Yao L, Yu S. Safety and efficacy of en bloc transurethral resection versus conventional transurethral resection for primary nonmuscle-invasive bladder cancer: a meta-analysis. *World J Surg Oncol.* 2020;18(1):4. doi:10.1186/s12957-019-1776-4
112. Yanagisawa T, Mori K, Motlagh RS. En Bloc resection for bladder tumors: an updated systematic review and meta-analysis of its differential effect on safety, recurrence and histopathology. *J Urol.* 2022;207(4):754–768. doi:10.1097/JU.0000000000002444
113. Teoh JYC, Mayor N, Li KM, Lo KL, Ng CF, Mostafid H. En-bloc resection of bladder tumour as primary treatment for patients with non-muscle-invasive bladder cancer: routine implementation in a multi-centre setting. *World J Urol.* 2021;39(9):3353–3358. doi:10.1007/s00345-021-03675-9
114. Maurice MJ, Ponsky LE. En bloc transurethral resection of bladder lesions: a trick to retrieve specimens up to 4.5 cm. *BJU Int.* 2013;111(3):E15–6. doi:10.1111/bju.12020\_8
115. Naselli A, Introini C, Germinale F, Spina B, Puppo P. En bloc transurethral resection of bladder lesions: a trick to retrieve specimens up to 4.5 cm. *BJU Int.* 2012;109(6):960–963. doi:10.1111/j.1464-410X.2012.10982.x
116. Petov V, Timofeeva E, Sukhanov R, et al. Prospective non-randomized comparison of transurethral laser en bloc resection vs. conventional resection of bladder tumors larger than 3 cm. *Minerva Urol Nephrol.* 2024;76(4):436–441. doi:10.23736/S2724-6051.24.05682-9
117. Yao Z, Li Y, Ding Y, et al. Thulium laser en bloc resection reduces recurrence rates in NMIBC patients with tumor diameters  $\geq 3$  cm compared to transurethral resection: a non-randomized controlled study. *BMC Cancer.* 2024;24:1239. doi:10.1186/s12885-024-13022-x
118. Bonfante G, Puliatti S, Sighinolfi MC. A survey-based study on the spread of en-bloc resection of bladder tumors among IEA and ESUT members. *Minerva Urol Nephrol.* 2021;73(4):413–416. doi:10.23736/S2724-6051.21.04627-9
119. Kramer MW, Rassweiler JJ, Klein J. En bloc resection of urothelium carcinoma of the bladder (EBRUC): a European multicenter study to compare safety, efficacy, and outcome of laser and electrical en bloc transurethral resection of bladder tumor. *World J Urol.* 2015;33(12):1937–1943. doi:10.1007/s00345-015-1568-6
120. Ortner G, Güven S, Somani BK. Experts' recommendations in laser use for the treatment of bladder cancer: a comprehensive guide by the European section of uro-technology (ESUT) and training and research in urological surgery and technology (TRUST)-group. *World J Urol.* 2024;42(1):79. doi:10.1007/s00345-024-04786-9
121. Enikeev D, Babjuk M, Shpikina A, Shariat S, Glybochko P. En bloc resection for nonmuscle-invasive bladder cancer: selecting a proper laser. *Current Opinion Urol.* 2022;32(2):173. doi:10.1097/MOU.0000000000000968
122. Diana P, Gallioli A, Fontana M. Energy source comparison in en-bloc resection of bladder tumors: subanalysis of a single-center prospective randomized study. *World J Urol.* 2023;41(10):2591–2597. doi:10.1007/s00345-022-04042-y



123. Li K, Xu Y, Tan M, Xia S, Xu Z, Xu D. A retrospective comparison of thulium laser en bloc resection of bladder tumor and plasmakinetic transurethral resection of bladder tumor in primary non-muscle invasive bladder cancer. *Lasers Med Sci.* 2019;34(1):85–92. doi:10.1007/s10103-018-2604-8
124. Mao T, Zhang H, Cui J, Zhao Z, Jiao D, Zhang W. The 980 nm diode laser treatment for non-muscle-invasive bladder tumor with en bloc technique: single-center experience. *World J Surg Oncol.* 2022;20(1):324. doi:10.1186/s12957-022-02786-w
125. Li S, Jia Y, Yu C. Influences of different operative methods on the recurrence rate of non-muscle-invasive bladder cancer. *Urol J.* 2020;18(4):411–416. doi:10.22037/uj.v16i7.5965
126. Waldbillig F, Hein S, Grüne B. Current European trends in endoscopic imaging and transurethral resection of bladder tumors. *J Endourol.* 2020;34(3):312–321. doi:10.1089/end.2019.0651
127. Suarez-Ibarrola R, Hein S, Farin E. Current standards in the endoscopic management of bladder cancer: a survey evaluation among urologists in German-speaking countries. *Urologia Internationalis.* 2020;104(5–6):410–416. doi:10.1159/000506653
128. Yao Q, Jiang H, Niu H, Hu G, Liu X, Xue B. Prospective learning curve analysis of en bloc resection of bladder tumor using an ex vivo porcine model. *BMC Surg.* 2024;24:65 doi: 10.1186/s12893-024-02355-w.
129. Long G, Zhang Y, Sun G, Ouyang W, Liu Z, Li H. Safety and efficacy of thulium laser resection of bladder tumors versus transurethral resection of bladder tumors: a systematic review and meta-analysis. *Lasers Med Sci.* 2021;36(9):1807–1816. doi:10.1007/s10103-021-03272-7
130. Li C, Gao L, Zhang J, Yang X, Liu C. The effect of holmium laser resection versus standard transurethral resection on non-muscle-invasive bladder cancer: a systematic review and meta-analysis. *Lasers Med Sci.* 2020;35:1025–1034 doi: 10.1007/s10103-020-02972-w.
131. Xu J, Wang C, Ouyang J, Sun J, Hu C. Efficacy and safety of transurethral laser surgery versus transurethral resection for non-muscle-invasive bladder cancer: a meta-analysis and systematic review. *Urol Int.* 2020;104(9–10):810–823. doi:10.1159/000506655
132. Bolat D, Yarimoglu S, Aydin ME. Monopolar versus bipolar transurethral resection of lateral wall-located bladder cancer under obturator nerve block: a single center prospective randomized study. *Int Braz J Urol.* 2021;47(3):584–593. doi:10.1590/s1677-5538.ibju.2020.0568
133. Balci M, Tuncel A, Ketten T. Comparison of monopolar and bipolar transurethral resection of non-muscle invasive bladder cancer. *Urol Int.* 2018;100(1):100–104. doi:10.1159/000467397
134. Liem EIML, McCormack M, Chan ESY. Monopolar vs. bipolar transurethral resection for non-muscle invasive bladder carcinoma: a post-hoc analysis from a randomized controlled trial. *Urol Oncol.* 2018;36(7):338.e1–338.e11. doi:10.1016/j.urolonc.2018.03.015
135. Yılmaz Y, Kahya MC, Dilek FH. Can tumor recurrence be reduced with plasma-kinetic vaporization of the area around the tumor in nonmuscle invasive bladder cancer? *Investigative Clin Urol.* 2018;59(4):223–231. doi:10.4111/icu.2018.59.4.223
136. Ma Y, Sun L, Lin X, Zhang W, Wang D. Efficacy and safety of bipolar versus monopolar transurethral resection of bladder tumors: a meta-analysis of randomized controlled trials. *J Cancer Res Ther.* 2020;16(7):1588–1595. doi:10.4103/jcrt.JCRT\_539\_20
137. Sharma G, Sharma AP, Mavuduru RS. Safety and efficacy of bipolar versus monopolar transurethral resection of bladder tumor: a systematic review and meta-analysis. *World J Urol.* 2021;39(2):377–387. doi:10.1007/s00345-020-03201-3
138. Tzelves L, Mourmouris P, Skolarikos A. Does bipolar energy provide any advantage over monopolar surgery in transurethral resection of non-muscle invasive bladder tumors? A systematic review and meta-analysis. *World J Urol.* 2021;39(4):1093–1105. doi:10.1007/s00345-020-03313-w
139. Krajewski W, Nowak L, Moschini M. Systematic review and meta-analysis on bipolar versus monopolar transurethral resection of bladder tumors. *Transl Androl Urol.* 2021;10(1):37–48. doi:10.21037/tau-20-749
140. Mao X, Zhou Z, Cui Y, Zhang Y, Yang M. Outcomes and complications of bipolar vs. monopolar energy for transurethral resection of bladder tumors: a systematic review and meta-analysis of randomized controlled trials. *Front Surg.* 2021;8:583806. doi:10.3389/fsurg.2021.583806
141. Xie K, Cao D, Wei Q. Bipolar versus monopolar transurethral resection of non-muscle-invasive bladder cancer: a systematic review and meta-analysis of randomized controlled trials. *World J Urol.* 2021;39(4):1177–1186. doi:10.1007/s00345-020-03271-3
142. Wong CH-M, Lim J-Y-Y, Ko IC-H. Monopolar versus bipolar transurethral resection of bladder Tumour: post-hoc analysis of a prospective trial. *World J Urol.* 2024;42(1):466. doi:10.1007/s00345-024-05124-9
143. Mahmoud MA, Tawfik A, Mostafa DE. Can bipolar energy serve as an alternative to monopolar energy in the management of large bladder tumours >3 cm? A prospective randomised study. *Arab J Urol.* 2019;17(2):125–131. doi:10.1080/2090598X.2019.1590517
144. Cornu J-N, Ahyai S, Bachmann A. A systematic review and meta-analysis of functional outcomes and complications following transurethral procedures for lower urinary tract symptoms resulting from benign prostatic obstruction: an update. *Europ urol.* 2015;67(6):1066–1096. doi:10.1016/j.eururo.2014.06.017
145. Deacon NN, Nielsen NK, Jensen JB. Patient-reported outcomes after laser ablation for bladder tumours compared to transurethral resection—a prospective study. *Cancers.* 2024;16(9):1630. doi:10.3390/cancers16091630
146. O'Sullivan NJ, MacCraith E, Temperley HC, Naughton A, Davis NF. Standard transurethral resection vs transurethral laser surgery for bladder cancer: a systematic review and meta-analysis comparing clinical outcomes and complications. *J Endourol.* 2023;37(3):304–315. doi:10.1089/end.2022.0328
147. Gu J, He Z, Chen Z, Wu H, Ding M. Efficacy and safety of 2-micron laser versus conventional trans-urethral resection of bladder tumor for non-muscle-invasive bladder tumor: a systematic review and meta-analysis. *J Cancer Res Ther.* 2022;18(7):1894–1902. doi:10.4103/jcrt.jcrt\_608\_22
148. Di Y, Li H, He C, Peng H. En-bloc transurethral resection vs. conventional transurethral resection for primary non-muscle invasive bladder cancer: a meta-analysis. *Actas Urol Esp.* 2023;47(5):309–316. doi:10.1016/j.acuro.2022.04.008
149. Oswald D, Pallau P, Deininger S. Safety and efficacy of en bloc vs. conventional transurethral resection of bladder tumors: a meta-analysis and systematic review. *Urologie.* 2022;61(6):644–652. doi:10.1007/s00120-022-01765-z
150. Allameh F, Sangian A, Razaghi M, Razzaghi S, Alahyari S, Amini A. Comparison of various types of lasers and transurethral resection in the treatment of bladder tumors: a systematic review and meta-analysis. *Lasers Med Sci.* 2020;37:95–101. doi: 10.1007/s10103-021-03479-8.
151. Bochenek K, Aebischer D, Międzybrodzka A, Cieślak G, Kawczyk-Krupka A. Methods for bladder cancer diagnosis - The role of autofluorescence and photodynamic diagnosis. *Photodiagnosis Photodyn Ther.* 2019;27:141–148. doi:10.1016/j.pdpdt.2019.05.036
152. Mulawkar PM, Sharma G, Tamhankar A, Shah U, Raheem R. Role of macroscopic image enhancement in diagnosis of non-muscle-invasive bladder cancer: an analytical review. *Front Surg.* 2022;9:.. doi:10.3389/fsurg.2022.762027
153. Grossman HB, Gomella L, Fradet Y. A Phase III, multicenter comparison of hexaminolevulinate fluorescence cystoscopy and white light cystoscopy for the detection of superficial papillary lesions in patients with bladder cancer. *J Urol.* 2007;178(1):62–67. doi:10.1016/j.juro.2007.03.034

154. Hoogeveen F, Blanker MH, Cauberg E, Steffens MG. Recurrence of non-muscle invasive bladder carcinoma after transurethral resection with hexaminolevulinate photodynamic diagnosis or regular cystoscopy. *Scand J Urol.* **2023**;58:120–125. doi:10.2340/sju.v58.10160
155. Russo GI, Sholkapper TN, Cocci A. Performance of narrow band imaging (NBI) and photodynamic diagnosis (PDD) fluorescence imaging compared to white light cystoscopy (WLC) in detecting non-muscle invasive bladder cancer: a systematic review and lesion-level diagnostic meta-analysis. *Cancers.* **2021**;13(17):4378. doi:10.3390/cancers13174378
156. Capece M, Spirito L, La Rocca R, et al. Hexaminolevulinate blue light cystoscopy (Hal) assisted transurethral resection of the bladder tumour vs white light transurethral resection of the bladder tumour in non-muscle invasive bladder cancer (NMIBC): a retrospective analysis. *Archivio Italiano di Urologia e Andrologia.* **2020**;92(1):17–20.
157. Matsushita Y, Miyake M, Nishimura N. Comparative assessment of disease recurrence after transurethral resection of non-muscle-invasive bladder cancer with and without a photodynamic diagnosis using 5-aminolevulinic acid: a propensity score-matching analysis. *Int J Clin Oncol.* **2024**;29(2):205–212. doi:10.1007/s10147-023-02447-2
158. Kawai T, Matsuyama H, Kobayashi K. Photodynamic diagnosis-assisted transurethral resection of bladder tumor for high-risk non-muscle invasive bladder cancer improves intravesical recurrence-free survival (BRIGHT study). *Int J Urol.* **2024**;31(8):906–912. doi:10.1111/iju.15483
159. Rink M, Babjuk M, Catto JWF. Hexyl aminolevulinate–guided fluorescence cystoscopy in the diagnosis and follow-up of patients with non-muscle-invasive bladder cancer: a critical review of the current literature. *Europ urol.* **2013**;64(4):624–638. doi:10.1016/j.eururo.2013.07.007
160. Miyakawa J, Yamada Y, Hakozaki Y. Comparison of PDD-TURBT alone versus white light TURBT plus intravesical BCG therapy: a propensity-score matching study. *Photodiagnosis Photodyn Ther.* **2024**;48:104254. doi:10.1016/j.pdpdt.2024.104254
161. Bryan RT, Billingham LJ, Wallace DMA. Narrow-band imaging flexible cystoscopy in the detection of recurrent urothelial cancer of the bladder. *BJU Int.* **2008**;101(6):702–706. doi:10.1111/j.1464-410X.2007.07317.x
162. Barbeiro S, Libânio D, Castro R, Dinis-Ribeiro M, Pimentel-Nunes P. Narrow-band imaging: clinical application in gastrointestinal endoscopy. *GE Port J Gastroenterol.* **2018**;26(1):40–53. doi:10.1159/000487470
163. Drejer D, Béji S, Oezke R. Comparison of white light, photodynamic diagnosis, and narrow-band imaging in detection of carcinoma in situ or flat dysplasia at transurethral resection of the bladder: the DaBlaCa-8 study. *Urology.* **2017**;102:138–142. doi:10.1016/j.urology.2016.11.032
164. Kim SB, Yoon SG, Tae J. Detection and recurrence rate of transurethral resection of bladder tumors by narrow-band imaging: prospective, randomized comparison with white light cystoscopy. *Investig Clin Urol.* **2018**;59(2):98–105. doi:10.4111/icu.2018.59.2.98
165. Cauberg ECC, Kloen S, Visser M. Narrow band imaging cystoscopy improves the detection of non-muscle-invasive bladder cancer. *Urology.* **2009**;76:658–663 doi: 10.1016/j.urology.2009.11.075.
166. Mukherjee P, George AJP, Yadav BK. The impact of narrow band imaging in the detection and resection of bladder tumor in transitional cell carcinoma of the bladder: a prospective, blinded, sequential intervention randomized controlled trial. *Urology.* **2019**;128:55–61. doi:10.1016/j.urology.2019.01.039
167. Dalgaard LP, Zare R, Gaya JM. Prospective evaluation of the performances of narrow-band imaging flexible videoscopes relative to white-light imaging flexible videoscopes, in patients scheduled for transurethral resection of a primary NMIBC. *World J Urol.* **2019**;37(8):1615–1621. doi:10.1007/s00345-018-2537-7
168. Zheng C, Lv Y, Zhong Q, Wang R, Jiang Q. Narrow band imaging diagnosis of bladder cancer: systematic review and meta-analysis. *BJU Int.* **2012**;110(11b):E680–7. doi:10.1111/j.1464-410X.2012.11500.x
169. Xiong Y, Li J, Ma S. A meta-analysis of narrow band imaging for the diagnosis and therapeutic outcome of non-muscle invasive bladder cancer. *PLoS One.* **2017**;12(2):e0170819. doi:10.1371/journal.pone.0170819
170. Soorojebally Y, Neuzillet Y, Lebre T. Photodynamic cystoscopy for bladder cancer diagnosis and for NMIBC follow-up: an overview of systematic reviews and meta-analyses. *Progrès en Urologie.* **2023**;33(6):307–318. doi:10.1016/j.purol.2023.03.003
171. Fan Z, Shi H, Luo J. Diagnostic and therapeutic effects of fluorescence cystoscopy and narrow-band imaging in bladder cancer: a systematic review and network meta-analysis. *Int J Surg.* **2023**;109(10):3169–3177. doi:10.1097/JS9.0000000000000592
172. Lai LY, Tafuri SM, Ginier EC, et al. Narrow band imaging versus white light cystoscopy alone for transurethral resection of non-muscle invasive bladder cancer. *Cochrane Database Syst Rev.* **2022**;2022(4):CD014887.
173. Cauberg ECC, Mamoulakis C, de la Rosette JJMCH, de Reijke TM. Narrow band imaging-assisted transurethral resection for non-muscle invasive bladder cancer significantly reduces residual tumour rate. *World J Urol.* **2011**;29(4):503–509. doi:10.1007/s00345-011-0659-2
174. Naito S, Algaba F, Babjuk M. The clinical research office of the endourological society (CROES) multicentre randomised trial of narrow band imaging–assisted transurethral resection of bladder tumour (TURBT) versus conventional white light imaging–assisted turbt in primary non-muscle-invasive bladder cancer patients: trial protocol and 1-year results. *Europ urol.* **2016**;70(3):506–515. doi:10.1016/j.eururo.2016.03.053
175. Sari Motlagh R, Mori K, Laukhtina E. Impact of enhanced optical techniques at time of transurethral resection of bladder tumour, with or without single immediate intravesical chemotherapy, on recurrence rate of non-muscle-invasive bladder cancer: a systematic review and network meta-analysis of randomized trials. *BJU Int.* **2021**;128(3):280–289. doi:10.1111/bju.15383
176. Gravestock P, Coulthard N, Veeratterapillay R, Heer R. Systematic review and meta-analysis of narrow band imaging for non-muscle-invasive bladder cancer. *Int J Urol.* **2021**;28(12):1212–1217. doi:10.1111/iju.14671
177. Lee JY, Cho KS, Kang DH. A network meta-analysis of therapeutic outcomes after new image technology-assisted transurethral resection for non-muscle invasive bladder cancer: 5-aminolaevulinic acid fluorescence vs hexylaminolevulinate fluorescence vs narrow band imaging. *BMC Cancer.* **2015**;15:566. doi:10.1186/s12885-015-1571-8
178. Remmelink MJ, Rip Y, Nieuwenhuijzen JA, et al. Advanced optical imaging techniques for bladder cancer detection and diagnosis: a systematic review. *BJU Int.* **2024**; 134(6):890–905.
179. Chen C, Huang H, Zhao Y. Diagnostic performance of image technique based transurethral resection for non-muscle invasive bladder cancer: systematic review and diagnostic meta-analysis. *BMJ Open.* **2019**;9(10):e028173. doi:10.1136/bmjopen-2018-028173
180. Hagimoto H, Makita N, Mine Y. Comparison between 5-aminolevulinic acid photodynamic diagnosis and narrow-band imaging for bladder cancer detection. *BMC Urol.* **2021**;21:180. doi:10.1186/s12894-021-00946-w
181. Ontario Health (Quality). Enhanced visualization methods for first transurethral resection of bladder tumour in suspected non-muscle-invasive bladder cancer: a health technology assessment. *Ont Health Technol Assess Ser.* **2021**, Aug 12;21(12):1–123. PMID: 34484486; PMCID: PMC8382283.

182. Grimbergen MCM, van Swol CFP, Jonges TGN, Boon TA, van Moorselaar RJA. Reduced specificity of 5-ALA induced fluorescence in photodynamic diagnosis of transitional cell carcinoma after previous intravesical therapy. *Europ urol*. 2003;44(1):51–56. doi:10.1016/S0302-2838(03)00210-0
183. Teoh JYC, Kamat AM, Black PC, Grivas P, Shariat SF, Babjuk M. Recurrence mechanisms of non-muscle-invasive bladder cancer — a clinical perspective. *Nat Rev Urol*. 2022;19(5):280–294. doi:10.1038/s41585-022-00578-1
184. Howard JM, Woldu SL, Daneshmand S, Lotan Y. Enhanced endoscopy with IMAGE1 S CHROMA improves detection of nonmuscle invasive bladder cancer during transurethral resection. *J Endourol*. 2021;35(5):647–651. doi:10.1089/end.2020.0821
185. Mulawkar P, Sharma G, Garge P. Evaluation of spectra A and B modes in diagnosis of suspicious bladder lesions. *J Endourol*. 2021;35(8):1184–1189. doi:10.1089/end.2020.0291
186. de la Rosette J, Martov A, Hurler R. Conventional white light imaging-assisted transurethral resection of bladder tumour (TURBT) versus IMAGE1S-assisted TURBT in non-muscle-invasive bladder cancer patients: trial protocol and 18 months results. *World J Urol*. 2022;40(3):727–738. doi:10.1007/s00345-021-03866-4
187. Trelles Guzmán CR, Linares Espinós E, Ríos González E. Randomized clinical trial on the use of IMAGE1 S LIGHT (SPIES) vs. white light in the prevention of recurrence during transurethral resection of bladder tumors: analysis after 12-month follow-up. *Actas Urol Esp*. 2024;48(7):512–520. doi:10.1016/j.acuroe.2023.12.005
188. Freitas NR, Vieira PM, Lima E, Lima CS. Automatic T1 bladder tumor detection by using wavelet analysis in cystoscopy images. *Phys Med Biol*. 2018;63:035031 doi: 10.1088/1361-6560/aaa3af.
189. Mutaguchi J, Morooka K, Kobayashi S. Artificial intelligence for segmentation of bladder tumor cystoscopic images performed by U-net with dilated convolution. *J Endourol*. 2022;36(6):827–834. doi:10.1089/end.2021.0483
190. Jia X, Shkolyar E, Laurie MA, Eminaga O, Liao JC, Xing L. Tumor detection under cystoscopy with transformer-augmented deep learning algorithm. *Phys Med Biol*. 2023;68:165013 doi: 10.1088/1361-6560/ace499.
191. Wu S, Chen X, Pan J. An artificial intelligence system for the detection of bladder cancer via cystoscopy: a multicenter diagnostic study. *J Natl Cancer Inst*. 2022;114(2):220–227. doi:10.1093/jnci/djab179
192. Guo Y, Li C, Zhang S. U-net-based assistive identification of bladder cancer: a promising approach for improved diagnosis. *Urol Int*. 2024;108(2):100–107. doi:10.1159/000535652
193. O'Sullivan S, Janssen M, Holzinger A. Explainable artificial intelligence (XAI): closing the gap between image analysis and navigation in complex invasive diagnostic procedures. *World J Urol*. 2022;40(5):1125–1134. doi:10.1007/s00345-022-03930-7
194. Sokolov I, Dokukin ME, Kalaparthi V. Noninvasive diagnostic imaging using machine-learning analysis of nanoresolution images of cell surfaces: detection of bladder cancer. *Proc Natl Acad Sci U S A*. 2018;115(51):12920–12925. doi:10.1073/pnas.1816459115
195. Tsuji K, Kaneko M, Harada Y. A fully automated artificial intelligence system to assist pathologists' diagnosis to predict histologically high-grade urothelial carcinoma from digitized urine cytology slides using deep learning. *Eur Urol Oncol*. 2024;7(2):258–265. doi:10.1016/j.euo.2023.11.009
196. Abuhaseinein S, Edenbrandt L, Enqvist O. A novel model of artificial intelligence based automated image analysis of CT urography to identify bladder cancer in patients investigated for macroscopic hematuria. *Scand J Urol*. 2024;59:90–97. doi:10.2340/sju.v59.39930
197. Qureshi TA, Chen X, Xie Y. MRI/RNA-seq-based radiogenomics and artificial intelligence for more accurate staging of muscle-invasive bladder cancer. *Int J mol Sci*. 2023;25:88 doi: 10.3390/ijms25010088.
198. Tokuyama N, Saito A, Muraoka R. Prediction of non-muscle invasive bladder cancer recurrence using machine learning of quantitative nuclear features. *Mod Pathol*. 2022;35(4):533–538. doi:10.1038/s41379-021-00955-y
199. Ślusarczyk A, Zapala P, Olszewska-Ślusarczyk Z, Radziszewski P. The prediction of cancer-specific mortality in T1 non-muscle-invasive bladder cancer: comparison of logistic regression and artificial neural network: a SEER population-based study. *Int Urol Nephrol*. 2023;55(9):2205–2213. doi:10.1007/s11255-023-03655-5
200. Lucas M, Jansen I, Van leeuwen TG, Oddens JR, de Bruin DM, Marquering HA. Deep learning-based recurrence prediction in patients with non-muscle-invasive bladder cancer. *Eur Urol Focus*. 2022;8(1):165–172. doi:10.1016/j.euf.2020.12.008
201. Singer G, Ramakrishnan VM, Rogel U. The role of new technologies in the diagnosis and surveillance of non-muscle invasive bladder carcinoma: a prospective, double-blinded, monocentric study of the xpert© bladder cancer monitor and narrow band imaging© cystoscopy. *Cancers*. 2022;14(3):618. doi:10.3390/cancers14030618
202. Parrao D, Lizana N, Saavedra C. Active surveillance in non-muscle invasive bladder cancer, the potential role of biomarkers: a systematic review. *Curr Oncol*. 2024;31(4):2201–2220. doi:10.3390/curroncol31040163
203. Soloway MS, Masters S. Urothelial susceptibility to tumor cell implantation: influence of cauterization. *Cancer*. 1980;46(5):1158–1163. doi:10.1002/1097-0142(19800901)46:5<1158::AID-CNCR2820460514>3.0.CO;2-E

## Research and Reports in Urology

## Publish your work in this journal

Research and Reports in Urology is an international, peer-reviewed, open access journal publishing original research, reports, editorials, reviews and commentaries on all aspects of adult and pediatric urology in the clinic and laboratory including the following topics: Pathology, pathophysiology of urological disease; Investigation and treatment of urological disease; Pharmacology of drugs used for the treatment of urological disease. The manuscript management system is completely online and includes a very quick and fair peer-review system, which is all easy to use. Visit <http://www.dovepress.com/testimonials.php> to read real quotes from published authors.

Submit your manuscript here: <https://www.dovepress.com/research-and-reports-in-urology-journal>

**Dovepress**  
Taylor & Francis Group