

# Unilateral Oral Herpes Zoster in an Elderly Female: A Case Report and Review of the Literature

Ahlam Ali AlZahrani<sup>1</sup>, Abdulrahman Esam Azhar<sup>2</sup>, Saif Yaseer Ashram<sup>3</sup>, Abdulmajeed Osama Alhindi<sup>2</sup>

<sup>1</sup>King Fahad General Hospital, Jeddah, Saudi Arabia; <sup>2</sup>King Abdulaziz University, Jeddah, Saudi Arabia; <sup>3</sup>King Abdulaziz Specialist Hospital, Taif, Saudi Arabia

Correspondence: Ahlam Ali AlZahrani, King Fahad General Hospital, Jeddah, Saudi Arabia, Tel +966 55 735 2275, Email Ahlamzahrani.1@gmail.com

**Abstract:** Herpes zoster, caused by the reactivation of varicella-zoster virus, typically presents with a unilateral, dermatomal rash. This case report describes a presentation of oral herpes zoster in a 64-year-old female patient. The patient presented with painful mouth ulcers confined to the right half of the posterior two-thirds of the hard palate, not crossing the midline. The diagnosis was based on clinical presentation, and treatment included systemic oral acyclovir and pain management with paracetamol. The patient showed substantial improvement with complete healing of the ulcers. This case highlights the importance of recognizing various presentations of herpes zoster, particularly in the oral cavity. It emphasizes the effectiveness of prompt antiviral therapy and appropriate pain management in treating oral herpes zoster. The report also underscores the potential role of risk factors such as advanced age and chronic conditions in herpes zoster susceptibility. This case contributes to the literature on oral manifestations of herpes zoster and stresses the need for clinical vigilance in diagnosing and managing such cases.

**Keywords:** herpes zoster, varicella-zoster virus, oral lesion, unilateral lesion, clinical diagnosis, acyclovir treatment, antiviral therapy

## Introduction

Herpes zoster is a viral syndrome caused by the reactivation of dormant varicella-zoster virus in the sensory ganglia of cranial nerves or dorsal root ganglia after a previous varicella infection.<sup>1</sup> It is strongly correlated with a weakened immune system, which fails to control the latent replication of the virus. The estimated incidence of herpes zoster is 1.2 to 3.4 per 1000 persons per year among healthy individuals. However, individuals older than 65 years have a higher incidence of 3.9 to 11.8% per 1000 persons per year.<sup>2</sup> The disease typically presents with prodromal symptoms like fever, arthralgia, and pain, followed by the appearance of painful grouped vesicles on an erythematous base along a dermatomal distribution that does not cross the midline, giving it the name “zoster” or girdle due to its segmental arrangement.<sup>3,4</sup> Herpes zoster can affect the oral cavity alone or in combination with skin lesions, typically occurring on one side, which helps distinguish it from other blistering conditions of the oral cavity.<sup>2,5</sup> Oral herpes zoster cases may present initially as toothache.<sup>2</sup> The vesicles ulcerate and heal within 10–14 days.<sup>5</sup>

Herpes zoster is generally recognized based on characteristic dermatomal rash, often preceded by pain and followed by the emergence of vesicles that later crust over. However, clinicians must be aware that herpes zoster can present in atypical forms, including instances where cutaneous manifestations are absent.<sup>6</sup> These atypical presentations pose a significant diagnostic challenge and may lead to delays in initiating appropriate antiviral therapy. Furthermore, it can lead to misdiagnosis as other conditions such as aphthous ulcers, herpetic gingivostomatitis, or other vesiculobullous disorders that also affect the oral mucosa.<sup>7,8</sup> Early administration of antiviral therapy, ideally within 72 hours of symptom onset, is crucial in limiting viral replication and reducing the risk of complications.<sup>9</sup>

As nerves are along the vessels, it may induce vasculitis, resulting in complications such as osteonecrosis, tooth loss, and pulp necrosis.<sup>2,10</sup> The infection has 3 phases; pre-eruptive- with malaise and pain sensations in the affected dermatome, acute eruptive phase- with painful vesicular skin rash, and chronic infection phase characterized by recurrent pain lasting

more than 4 weeks.<sup>11</sup> Diagnosis is primarily based on typical clinical symptoms and pathognomonic rash. The diagnosis can be confirmed by polymerase chain reaction (PCR), viral culture, Tzanck smear, and direct fluorescent antibody (DFA) testing of vesicular fluid.<sup>12</sup> PCR is the investigation of choice.<sup>12</sup> DFA is complex and may give false-negative results, as it requires aggressive lesion sampling to include cells.<sup>12</sup> The management of herpes zoster primarily includes antiviral therapy, pain management, and supportive care. Antiviral agents such as acyclovir, valacyclovir, and famciclovir are the most effective when started within the first 72 hours after the rash appears, as they help reduce the severity and duration of the disease.<sup>9</sup> The complications of herpes zoster include postherpetic neuralgia, herpes zoster Ophthalmicus, and secondary bacterial infections.<sup>2</sup> Rarely, it may cause neurological complications such as meningitis and encephalitis.<sup>13</sup>

## Case Presentation

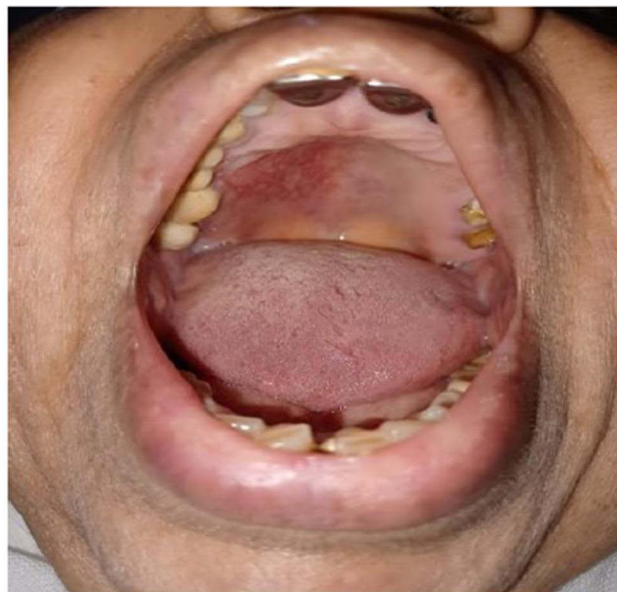
A 64-year-old female patient presented to Dermatology clinic with a chief complaint of painful mouth ulcers persisting for three days. The patient's medical history was significant for osteoporosis and obesity, for which she was taking a daily calcium supplement of 600 mg. The primary complaint was accompanied by fever of one-day duration and difficulty eating and drinking.

Upon oral examination, grouped white ulcerations with erythematous halos were observed on the right half of the posterior two-thirds of the hard palate. Notably, these ulcerations did not cross the midline of the hard palate (**Figure 1**). Based on the clinical presentation, the patient was diagnosed with oral herpes zoster.

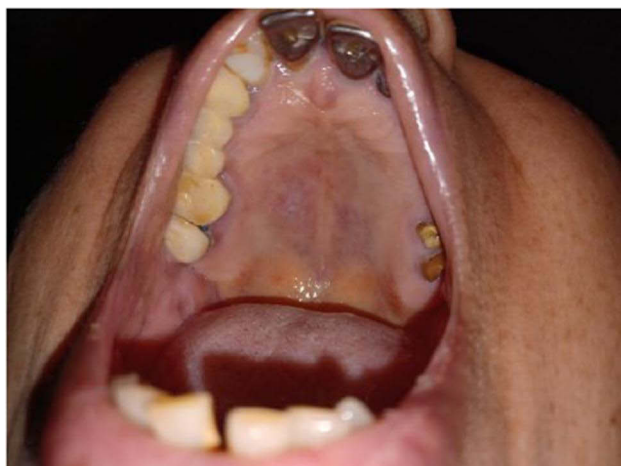The treatment plan consisted of both pharmacological interventions and supportive measures. The patient was prescribed systemic oral Acyclovir at a dose of 800 mg every 4 hours for 10 days, along with oral Paracetamol 1000 mg every 6 hours for pain management. Additionally, the patient was advised to maintain a soft diet to minimize discomfort during eating. Given the infectious nature of the condition, home isolation was recommended, with specific instructions to wear an N95 mask and avoid contact with family members to prevent transmission.

The patient responded favorably to the prescribed treatment regimen. There was a notable reduction in pain and significant improvement in the ulcerations, as evidenced in the follow-up examination (**Figure 2**). Complete healing of the mouth ulcers was observed, demonstrating the efficacy of the chosen treatment approach.

It is worth noting that the patient had not received the zoster vaccine prior to this incident, which may have contributed to her susceptibility to herpes zoster infection. This case underscores the importance of considering zoster vaccination in eligible individuals, particularly those with risk factors such as advanced age and chronic conditions.



**Figure 1** Grouped white ulcerations with erythematous halos on the right half of the posterior two-thirds of the hard palate, not crossing the midline.



**Figure 2** Follow-up examination showing significant improvement and healing of the oral herpes zoster lesions following treatment.

## Discussion and Review of the Literature

Oral herpes zoster is a rare manifestation of the varicella-zoster virus reactivation. When searched in PubMed, approximately 1900 results for ocular herpes zoster were identified. While herpes zoster typically involves a dermatomal rash, cases limited to the oral cavity, especially without concurrent skin lesions are seldom reported in the literature.<sup>14,15</sup> Our patient presented with painful ulcerations and erythematous halos over the hard palate, similar to the case presented by Nagakeerthana et al, where an old age female patient presented with severe burning painful white lesions on the hard palate.<sup>14</sup> Gurung et al reported another case in which the patient had vesicles on the upper lip and intra-orally on the right side of the palate region.<sup>15</sup>

The incidence of herpes zoster is higher in women, with a median age of presentation around 56 years, and a decreasing incidence after 60 years of age.<sup>16</sup> However, our patient was a 64-year-old woman with osteoporosis and obesity. Obesity may contribute to immune system dysregulation.<sup>17</sup> While it was previously believed that immunocompromised patients were more prone to develop herpes zoster, a study by Thompson et al revealed that 90% of affected individuals are not immunocompromised.<sup>16</sup> Herpes zoster is a painful, blistering eruption in a dermatomal distribution, most commonly affecting the sensory components of the thoracic nerves and the ophthalmic division of the trigeminal nerve.<sup>18</sup> Herpes zoster involving only the mandibular branch of the trigeminal nerve is rare.<sup>19</sup> As observed in both cases, the distribution pattern along the maxillary branch of the trigeminal nerve highlights the importance of recognizing nerve distribution in diagnosing oral herpes zoster. Few other case studies involving the trigeminal nerve have been mentioned in Table 1.

Physical examination of herpes zoster may reveal vesicles, ulcerations, or erythematous halos. During the acute eruptive phase, lesions present as macules and rapidly transform into painful vesicles which often rupture and ulcerate, eventually forming crusts as seen on examination of our patient.<sup>2</sup> The rash of herpes zoster is typically dermatomal and unilateral,

**Table 1** Summary of Case Reports on Oral and Facial Varicella Zoster Virus (VZV)

Case Report	Age/ Gender; Involved Region	Presenting Symptoms	Diagnostic Method	Treatment	Outcome
Lewis et al <sup>14</sup>	80y/ M; Mandibular (V3)	Painful skin lesions, Nausea, and Vomiting	Anti-VZV antibodies	Oxycodone, Glucocorticoids	Improved
Polvino et al <sup>17</sup>	65y/ M; Oral Cavity/ Hard Palate (V2)	Painful vesicular lesion on hard palate	Clinical	Ketorolac (Intramuscular), Valacyclovir	Referred to Dermatology but did not seek follow-up care

(Continued)

**Table 1** (Continued).

Case Report	Age/ Gender; Involved Region	Presenting Symptoms	Diagnostic Method	Treatment	Outcome
Tsai et al <sup>18</sup>	33y/ M; Oral Cavity/ Hard Palate (V2)	Painful ulcerations on hard palate, fever, fatigue	Clinical	Acyclovir, Acetaminophen, Folic-acid, Vitamin B12	Healing of ulceration, no recurrence, or complication noted on follow-up
Hagiya et al <sup>19</sup>	70y/ M; Oral Cavity/ Tooth (V2)	Toothache, facial tenderness, tingling sensation in the mouth, erosions on the hard palate	Clinical+ Varicella zoster virus IgG antibodies	Intravenous Acyclovir	Post-herpetic neuralgia
Chhimwal et al <sup>20</sup>	42y/ M; Face, upper lip, and oral cavity/ hard palate (V2)	Fever, Painful mouth ulcers, fluid-filled blisters over the left half of the face	Clinical+ Cytological examination of smear from lesion	Aceclofenac, Acyclovir	Lesions healed with scarring but no post-herpetic neuralgia
Pelloni et al <sup>21</sup>	71y/ M; Forehead, face, nose, hard/soft palate (V1, V2)	Vesicular lesions on the left half of the face, and hard/soft palate	PCR for VZV DNA	Valaciclovir, acetaminophen, topical fusidic acid ointment, and hyaluronic acid eye drops	Complete recovery
Akinbade et al <sup>22</sup>	60/F; Lip, tongue, cheek, and floor of the mouth (V3)	Pain on the left side of the tongue and floor of the mouth (Post-herpetic neuralgia), peri-oral rashes, and ulceration	Clinical	Gabapentin, Celecoxib, Methylcobalamin, Vitamin-C	Clinically improved, perioral rashes and ulceration resolved

**Abbreviations:** VZV, Varicella Zoster Virus; PCR, Polymerase Chain Reaction; M/F, Male/Female; V1, V2, V3, Branches of the trigeminal nerve.

a feature consistent with reactivation from single dorsal root ganglia.<sup>20</sup> This characteristic aligns with the findings in our case. In immunocompromised patients, the zoster rash can also appear as multi-dermatomal (lesions in 2–3 adjacent dermatomes) or disseminated (more than 20 vesicles beyond the primary area or involving organs).<sup>21</sup> We established the diagnosis of herpes zoster on a clinical basis as supported by literature.<sup>21</sup> Although PCR testing is the preferred confirmatory diagnostic tool for herpes zoster, it was not performed in this case due to the classical clinical presentation and the immediate need for treatment. In settings where resources permit, PCR is recommended to further confirm diagnosis.<sup>21</sup>

The differential diagnosis of herpes zoster is very important, particularly with conditions like major aphthous ulcers, erythema multiforme, primary herpetic stomatitis, and atrophic candidiasis. Aphthous ulcers can be differentiated from herpes zoster based on development of ulcer as no vesicular stage is observed, whereas herpes zoster lesions often begin as vesicles before ulcerating.<sup>22</sup> Similarly, erythema multiforme lesions tend to be more diffuse and symmetric, whereas herpes zoster follows a unilateral, dermatomal pattern. However, PCR can be useful if diagnosis is difficult to establish.<sup>23</sup> Candidiasis lacks vesicles and ulcers, whereas herpes zoster begins as vesicles that ulcerate. Furthermore, it also responds to antifungal treatment.

The treatment plan for our patient included both pharmacological interventions and supportive measures. Systemic oral acyclovir was prescribed as one of the recommended antivirals (acyclovir, valacyclovir, and famciclovir).<sup>24</sup> The antiviral therapy when initiated within 72 hours can reduce viral replication and minimize the risk of postherpetic neuralgia (PHN).<sup>24</sup> Pain management is a critical component of management, controlled with paracetamol in our case, but in severe cases may require a combination of analgesics, including opioids, tricyclic antidepressants, and gabapentin.<sup>24,25</sup> Although no specific dietary changes are generally recommended for herpes zoster, the patient was advised on a soft diet to minimize discomfort during swallowing.

According to the center of disease control (CDC), shingles can spread through unprotected contact with the patient, their secretions, or airborne infectious particles.<sup>26</sup> This aligns with our preventive measures, including isolation, limited

contact with family members, and the use of masks. The prognosis of herpes zoster is generally good with early antiviral therapy, as demonstrated in our case with complete healing of the ulcers. However, complications such as post-herpetic neuralgia, super-imposed bacterial infections, and nervous system involvement leading to polyneuritis, myelitis, aseptic meningitis, or facial paralysis can occur.<sup>26</sup> A study on healthy aging demonstrated that herpes zoster is common, with a lifetime risk of one-third.<sup>27</sup> In most cases, herpes zoster does not require long term follow up. However, some studies have reported that herpes zoster can result in cognitive decline and increase risk of stroke.<sup>28</sup> Furthermore, postherpetic neuralgia remains one of the most concerning complications following herpes zoster. It is characterized by persistent, often severe, nerve pain that can last for months or even years after the initial rash and blisters of shingles have healed.<sup>29</sup>

Herpes zoster significantly affects quality of life and is preventable through vaccination. Studies revealed that it is associated with prolonged pain, cardiovascular disease, and stroke.<sup>30</sup> The CDC recommends recombinant zoster vaccine (Shingrix) for adults aged 50 and older and for immunocompromised individuals aged 19 and older.<sup>31</sup> In adults aged 50 years and above, vaccination can help prevent the disease and its complications such as post-herpetic neuralgia in 90% individuals.<sup>27,32</sup> Furthermore, vaccination in individuals aged 60 years and above can help prevent herpes zoster infection in 54% of cases and 67.1% in individuals aged 60–69 years.<sup>33</sup> However, our patient had not received the vaccination which may have contributed to susceptibility.

## Conclusion

Our report details an unusual instance of one-sided oral herpes zoster in a 64-year-old female patient, with sores limited to the right side of the back two-thirds of the hard palate. The patient showed good progress with systemic antiviral treatment and pain relief, leading to full recovery. This case underscores the need to identify uncommon forms of herpes zoster confined to the mouth and the benefits of swift antiviral intervention. We urge doctors to be alert for herpes zoster in older patients with one-sided mouth sores. We suggest quick antiviral treatment, pain management, teaching patients about preventing spread, and thinking about zoster shots for high-risk individuals. Our findings add to the understanding of mouth-related herpes zoster signs and stress the importance of clinical alertness for early detection and proper care. Future studies should aim to enhance prevention methods and improve ways to spot atypical cases.

## Consent for Publication

The patient provided informed consent for the publication of this case report, including the accompanying images.

## Patient Consent for Publication

Informed consent was obtained from the patient, who acknowledged and agreed to the use of clinical photographs for research purposes, as well as the inclusion of his perspective on the effectiveness and experience of treatment with Acyclovir.

## Institutional Approval

As this is a case report, formal institutional review board approval was not required.

## Funding

No funding was received for this research.

## Disclosure

The authors declare no conflicts of interest related to this publication. No financial, personal, or professional relationships influenced the development, writing, or conclusions of this case report on oral herpes zoster.

## References

1. Sejvar J. Vaccines and viral/toxin-associated neurologic infections. *Handbook Clin Neurol*. 2014;123:719–744.
2. Nair P, Patel B. *StatPearls*. Treasure Island (FL): StatPearls Publishing; 2018.
3. Burns T, Breathnach SM, Cox N, Griffiths C. *Rook's Textbook of Dermatology*. John Wiley & Sons; 2008.



4. Sinha R, Kumari P, Pallavi UK, Sarkar S. Clinical and Epidemiological Profile of Herpes Zoster and Its Complications in a Tertiary Care Center of Bihar: a Prospective Study. *Cureus*. 2023;15(8):e43560. doi:10.7759/cureus.43560
5. Mortazavi H, Safi Y, Baharvand M, Rahmani S. Diagnostic Features of Common Oral Ulcerative Lesions: an Updated Decision Tree. *Int J Dent*. 2016;2016:7278925. doi:10.1155/2016/7278925
6. Rao K, Gogineni S, Castelino R, et al. Manifestation of intra-oral Herpes zoster in hard palate without cutaneous involvement. *Cukurova Med J*. 2018;43:770–771. doi:10.17826/cumj.396952
7. Chiang Y-T, Hwang M-J, Lee Y-P, Chiang C-P. Differential diagnosis between herpetic gingivostomatitis and herpetiform aphthous ulcerations. *J Dent Sci*. 2020;15(3):386. doi:10.1016/j.jds.2020.06.001
8. Tsai YC, Lee YP, Hwang MJ, Chiang CP. Oral herpes zoster - Case report. *J Dent Sci*. 2021;16(1):563–564. doi:10.1016/j.jds.2020.10.001
9. Yeh CH, Chang KS, Huang SS, Tsay SL, Tsai JM, Wang YJ. Comparing Prodrugs with Acyclovir for Treating Postherpetic Neuralgia among Herpes Zoster Patients: a Systematic Review and Meta-Analysis. *Healthcare*. 2022;10(7):1181. doi:10.3390/healthcare10071181
10. Park KS. Maxillary Osteonecrosis Related with Herpes Zoster: a Case Report and Review of the Literature. *Medicina*. 2024;60(6):883. doi:10.3390/medicina60060883
11. Patil A, Goldust M, Wollina U. Herpes zoster: a Review of Clinical Manifestations and Management. *Viruses*. 2022;14(2):192. doi:10.3390/v14020192
12. Dollard S, Chen MH, Lindstrom S, Marin M, Rota PA. Diagnostic and Immunologic Testing for Varicella in the Era of High-Impact Varicella Vaccination: an Evolving Problem. *J Infect Dis*. 2022;226(Suppl 4):S450–S455. doi:10.1093/infdis/jiac363
13. Alvarez JC, Alvarez J, Tinoco J, et al. Varicella-Zoster Virus Meningitis and Encephalitis: an Understated Cause of Central Nervous System Infections. *Cureus*. 2020;12(11):e11583. doi:10.7759/cureus.11583
14. Nagakeerthana S, Rangaraj M. Oral sores: a rare presentation of Herpes zoster. *Geriatric Care*. 2016;2(2). doi:10.4081/gc.2016.5964
15. Gurung D, Joshi U, Chaudhary B. Orofacial Herpes Zoster Infection in Dental practice: a Case Report. *J Nepal Med Assoc*. 2020;58(231):941–944. doi:10.31729/jnma.5310
16. Thompson RR, Kong CL, Porco TC, Kim E, Ebert CD, Acharya NR. Herpes Zoster and Postherpetic Neuralgia: changing Incidence Rates From 1994 to 2018 in the United States. *Clin Infect Dis*. 2021;73(9):e3210–e3217. doi:10.1093/cid/ciaa1185
17. CDC. Obesity, Race/Ethnicity, and COVID-19. Available from: <https://www.cdc.gov/obesity/data/obesity-and-covid-19.html>. Accessed September 22, 2024.
18. Sampathkumar P, Drage LA, Martin DP. Herpes zoster (shingles) and postherpetic neuralgia. *Mayo Clin Proc*. 2009;84(3):274–280. doi:10.4065/84.3.274
19. Lewis ME, Warren KG. Herpes zoster mandibularis. *Can J Neurol Sci*. 1980;7(2):153–155. doi:10.1017/s0317167100023532
20. Cohen JI. Herpes Zoster. *N Engl J Med*. 2013;369(3):255–263. doi:10.1056/NEJMcp1302674
21. Lim DZJ, Tey HL, Salada BMA, et al. Herpes Zoster and Post-Herpetic Neuralgia-Diagnosis, Treatment, and Vaccination Strategies. *Pathogens*. 2024;13(7):596. doi:10.3390/pathogens13070596
22. Tilliss T, McDowell JD. Differential diagnosis: is it herpes or aphthous. *J Contemp Dent Pract*. 2002;3(1):1–15. doi:10.5005/jcdp-3-1-16
23. Kasuya A, Sakabe J-I, Kageyama R, Ikeya S, Fujiyama T, Tokura Y. Successful differentiation of herpes zoster-associated erythema multiforme from generalized extension of herpes by rapid polymerase chain reaction analysis. *J Dermatol*. 2014;41(6):542–544. doi:10.1111/1346-8138.12479
24. CKJ. Herpes Zoster Treatment & Management. Available from: <https://emedicine.medscape.com/article/1132465-treatment?form=fpf>. Accessed April 28, 2025.
25. Hempenstall K, Nurmikko TJ, Johnson RW, A'Hern RP, Rice AS. Analgesic therapy in postherpetic neuralgia: a quantitative systematic review. *PLoS Med*. 2005;2(7):e164. doi:10.1371/journal.pmed.0020164
26. CDC. Varicella-Zoster Virus. Available from: <https://www.cdc.gov/infection-control/hcp/healthcare-personnel-epidemiology-control/varicella.html>. Accessed September 24, 2024.
27. Curran D, Doherty TM, Lecrenier N, Breuer T. Healthy ageing: herpes zoster infection and the role of zoster vaccination. *Npj Vaccines*. 2023;8(1):184. doi:10.1038/s41541-023-00757-0
28. Yeh T-S, Curhan GC, Yawn BP, Willett WC, Curhan SG. Herpes zoster and long-term risk of subjective cognitive decline. *Alzheimer's Res Ther*. 2024;16(1):180. doi:10.1186/s13195-024-01511-x
29. Gruver C, Guthmiller KB. *Postherpetic Neuralgia*. StatPearls Publishing; 2025.
30. Yamaoka-Tojo M, Tojo T. Herpes Zoster and Cardiovascular Disease: exploring Associations and Preventive Measures through Vaccination. *Vaccines*. 2024;12(3):252. doi:10.3390/vaccines12030252
31. CDC. Shingles Vaccine Recommendations. Available from: <https://www.cdc.gov/shingles/hcp/vaccine-considerations/index.html>. Accessed September 29, 2024.
32. CDC. Shingles Vaccination. Available from: <https://www.cdc.gov/shingles/vaccines/index.html>. Accessed September 29, 2024.
33. Gabutti G, Bonanni P, Conversano M, et al. Prevention of Herpes Zoster and its complications: from clinical evidence to real life experience. *Hum Vaccin Immunother*. 2017;13(2):391–398. doi:10.1080/21645515.2017.1264831

## Clinical, Cosmetic and Investigational Dermatology

### Publish your work in this journal

Clinical, Cosmetic and Investigational Dermatology is an international, peer-reviewed, open access, online journal that focuses on the latest clinical and experimental research in all aspects of skin disease and cosmetic interventions. This journal is indexed on CAS. The manuscript management system is completely online and includes a very quick and fair peer-review system, which is all easy to use. Visit <http://www.dovepress.com/testimonials.php> to read real quotes from published authors.

Submit your manuscript here: <https://www.dovepress.com/clinical-cosmetic-and-investigational-dermatology-journal>

**Dovepress**  
Taylor & Francis Group