

# Ultrasound-Guided the Prevertebral Fascia Incise and the C5 Root Hydrodissection for the Treatment of Neurogenic Thoracic Outlet Syndrome: an Application Study

Zhenlan Liao<sup>1,\*</sup>, Yajing Zhou<sup>2,\*</sup>, Wen Cao<sup>3</sup>

<sup>1</sup>Department of Ultrasound, The First People's Hospital of Neijiang, Neijiang, People's Republic of China; <sup>2</sup>Department of Ultrasound Medicine, TongRen Hospital, Capital Medical University, Beijing, People's Republic of China; <sup>3</sup>Department of Ultrasound Medicine, Beijing Chao-Yang Hospital, Capital Medical University, Beijing, People's Republic of China

\*These authors contributed equally to this work

Correspondence: Wen Cao, The Department of Ultrasound Medicine, Beijing Chao-Yang Hospital, Capital Medical University, No. 8 Gongren Tiyuchang Nanlu, Chaoyang District, Beijing, 100020, People's Republic of China, Tel +86 (010) 85231030, Email caowenemail@126.com

**Objective:** The aim of this retrospective study was to evaluate the effectiveness of ultrasound-guided hydrodissection of the C5 nerve root, in combination with prevertebral fascia incision, as a treatment for neurogenic thoracic outlet syndrome (NTOS).

**Methods:** Between January 2023 and January 2024, a total of 34 patients diagnosed with NTOS were enrolled in the treatment group, all of whom underwent ultrasound-guided hydrodissection of the C5 nerve root and prevertebral fascia incision. A control group consisting of 34 healthy participants was also included for comparative purposes. Preoperative and postoperative ultrasound measurements were taken at 1 and 6 weeks, including the thickness of the prevertebral fascia, the distance between the C5 nerve root and fascia, and the cross-sectional area (CSA) of the C5 nerve root. Pain intensity and functional status were assessed using the Visual Analog Scale (VAS) and Disabilities of the Arm, Shoulder, and Hand (DASH) scores.

**Results:** Preoperative measurements in the NTOS group showed increased prevertebral fascia thickness (median: 0.1 mm [IQR 0.08–0.12]), reduced distance between the C5 nerve root and the fascia (median: 0.13 mm [IQR 0.10–0.16]), and a larger CSA of the C5 nerve root (median: 0.08 mm<sup>2</sup> [IQR 0.06–0.10]). Post-treatment, VAS scores significantly improved from a median of 7 (IQR 6–8) to 2 (IQR 2–3) at 1 week and remained stable at 6 weeks, while DASH scores improved from 85 (IQR 82–89) to 34 (IQR 31–36) at 1 week and 33 at 6 weeks.

**Conclusion:** Ultrasound-guided hydrodissection of the C5 nerve root, along with prevertebral fascia incision, is an effective, minimally invasive treatment for NTOS.

**Keywords:** ultrasound guidance, hydrodissection, thoracic outlet syndrome, c5 nerve root, minimally invasive treatment

## Introduction

Thoracic Outlet Syndrome (TOS) represents a complex and multifaceted clinical challenge, marked by the compression of neurovascular bundles and blood vessels as they traverse from the cervical region to the upper extremity. With an estimated incidence of 1 to 3 cases per 100,000 individuals, TOS has emerged as a significant focus of clinical and research interest due to its profound impact on patients' functional abilities and quality of life.<sup>1–3</sup> Among its subtypes, neurogenic thoracic outlet syndrome (NTOS) dominates the clinical landscape, constituting 80–90% of all TOS cases.<sup>4</sup> Despite its prevalence, NTOS diagnosis and treatment remains complex, requiring a meticulous synthesis of patient history, detailed clinical examination, and the integration of advanced imaging modalities.<sup>1,5</sup>

One of the most pressing scientific hurdles in TOS management lies in its heterogeneous clinical presentation, which not only complicates accurate diagnosis but also delays the initiation of timely and effective interventions. While ultrasound imaging has gained traction for its ability to provide real-time, dynamic visualization of anatomical structures,

its precise role in managing NTOS remains an area of active exploration.<sup>6,7</sup> Subtle yet critical alterations in nerve roots and surrounding fascial tissues, which are pivotal for accurate diagnosis, often elude detection by conventional imaging techniques.<sup>4</sup> Compounding this challenge is the lack of standardized criteria, which frequently results in diagnostic ambiguity and therapeutic delays.<sup>8</sup>

The morbidity associated with acute NTOS underscores the urgent need for innovative and targeted treatment strategies.<sup>9</sup> Although conservative measures such as physical therapy and analgesics are commonly employed, they often fall short in providing meaningful relief for patients with true neurogenic NTOS,<sup>10</sup> highlighting the demand for alternative therapeutic approaches.<sup>11</sup> Emerging evidence, though still limited, points to ultrasound-guided hydrodissection of the nerve root as a promising intervention. This minimally invasive technique has the potential to not only accelerate symptom relief but also deliver sustained improvements in clinical outcomes, offering a paradigm shift in NTOS management.<sup>12</sup>

This study aims to assess the safety, effectiveness, and long-term benefits of ultrasound-guided hydrodissection for NTOS, providing valuable insights into its potential as a new and effective treatment option.

## Materials and Methods

### Participants and Study Design

Patients presenting with unilateral shoulder and upper limb pain persisting for more than six months, along with a positive percussion test at the interscalene groove, were enrolled from the Orthopedics Department at Beijing Chaoyang Hospital between January 2023 and September 2024. The study was conducted in accordance with the procedure outlined below (Figure 1).

**Inclusion Criteria:** Participants were diagnosed with NTOS based on the following established criteria:<sup>13</sup>

1. Local Symptoms: Patients exhibited localized symptoms in areas typically affected by compression, such as the chest wall, trapezius, and neck, confirmed by pain on palpation in these specific regions.
2. Peripheral Findings: There were documented symptoms in the arm or hand, substantiated by patient history and confirmed through provocative maneuvers that reproduced or exacerbated the symptoms.
3. Exclusion of Other Diagnoses: Patients were required to have no other reasonable or likely diagnoses, ruling out conditions such as cervical spine disorders, shoulder pathologies, or peripheral nerve injuries.

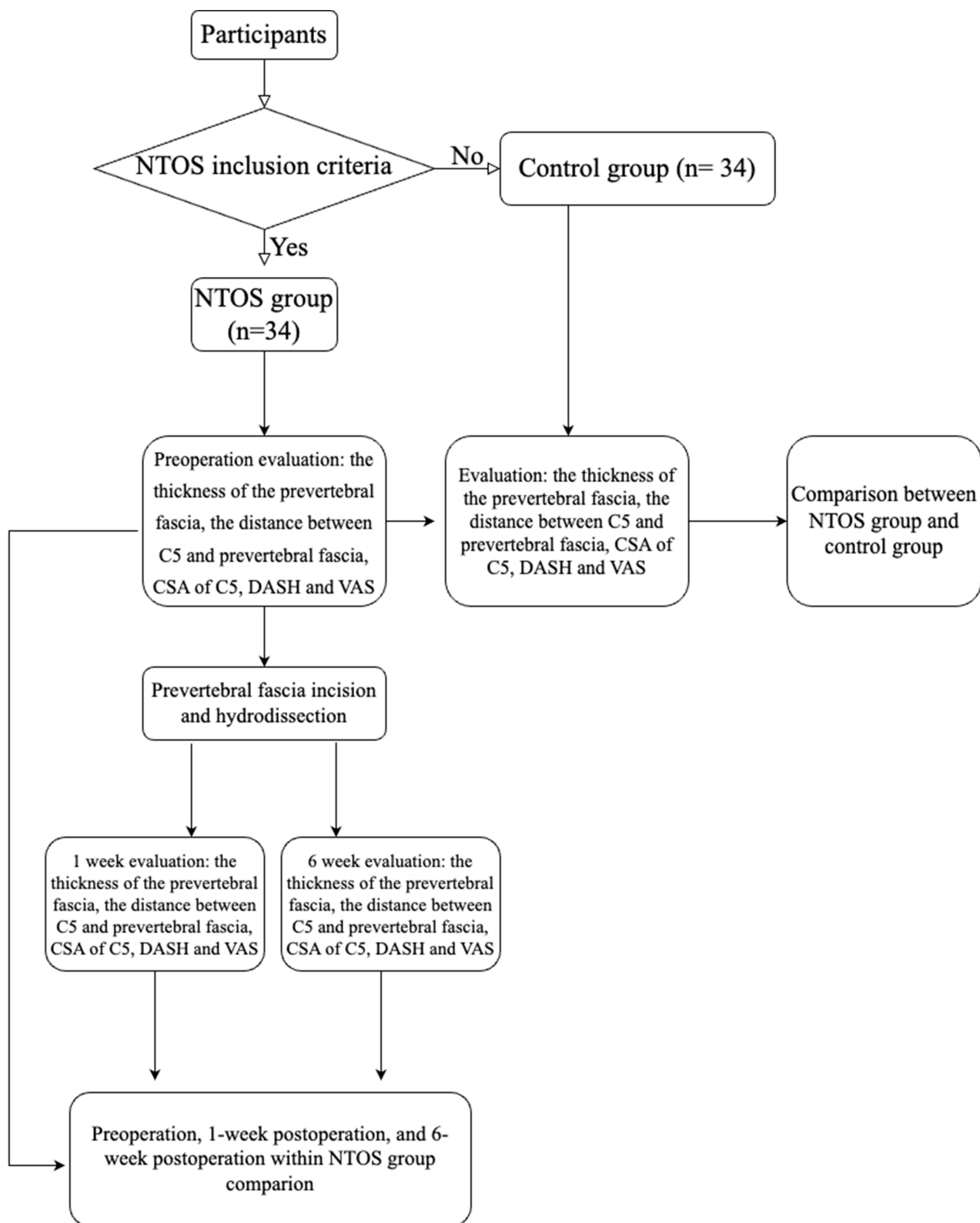
**Exclusion criteria:** Patients with prior neck surgery, cervical radiculopathy, cervical rib, infections, or significant comorbidities.

Data on demographics and outcomes will be collected, allowing for an analysis of the characteristics and management of NTOS. Eventually, we enrolled 34 unilateral NTOS cases in the NTOS group, and 34 normal participants in the control group retrospectively. The study was approved by the Ethics Committee of the First People's Hospital of Neijiang (Approval No. 2024–60). The research complies with the ethical principles outlined in the Declaration of Helsinki. All patients were well informed and signed all necessary consents.

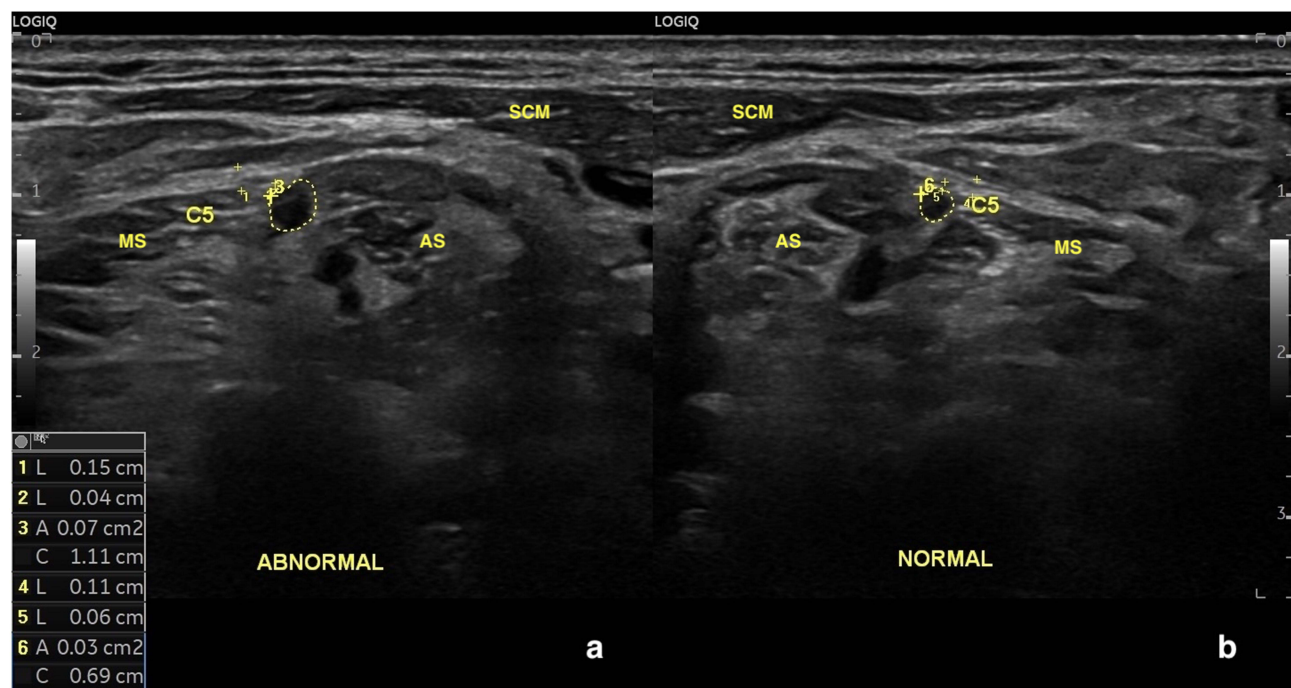
## Procedure

### Ultrasonography

A diagnostic ultrasound system (E10s, LOGIQ; General Electric, Boston, USA) equipped with a 15 MHz probe (15L6; GE) was used. The supraclavicular portion of the brachial plexus on the symptomatic side was examined in the supine position, based on the examiner's preference, with the patient's head turned toward the opposite side. Standard scanning techniques and anatomical landmarks were followed. The scan began at the supraclavicular fossa, where the lower trunk of the brachial plexus is located just lateral to the subclavian artery. The scan was then moved cranially through the interscalene region, continuing up to the C5 root at the foraminal level. The upper trunk and its surrounding structures were closely examined.<sup>14</sup> The thickness of the prevertebral fascia and the distance between the C5 nerve root and the prevertebral fascia were measured and documented for subsequent analysis. (Figure 2a and b) The cross-sectional area (CSA) of C5 nerve root was recorded in the same side. These measurements were performed along the vertebral axis,

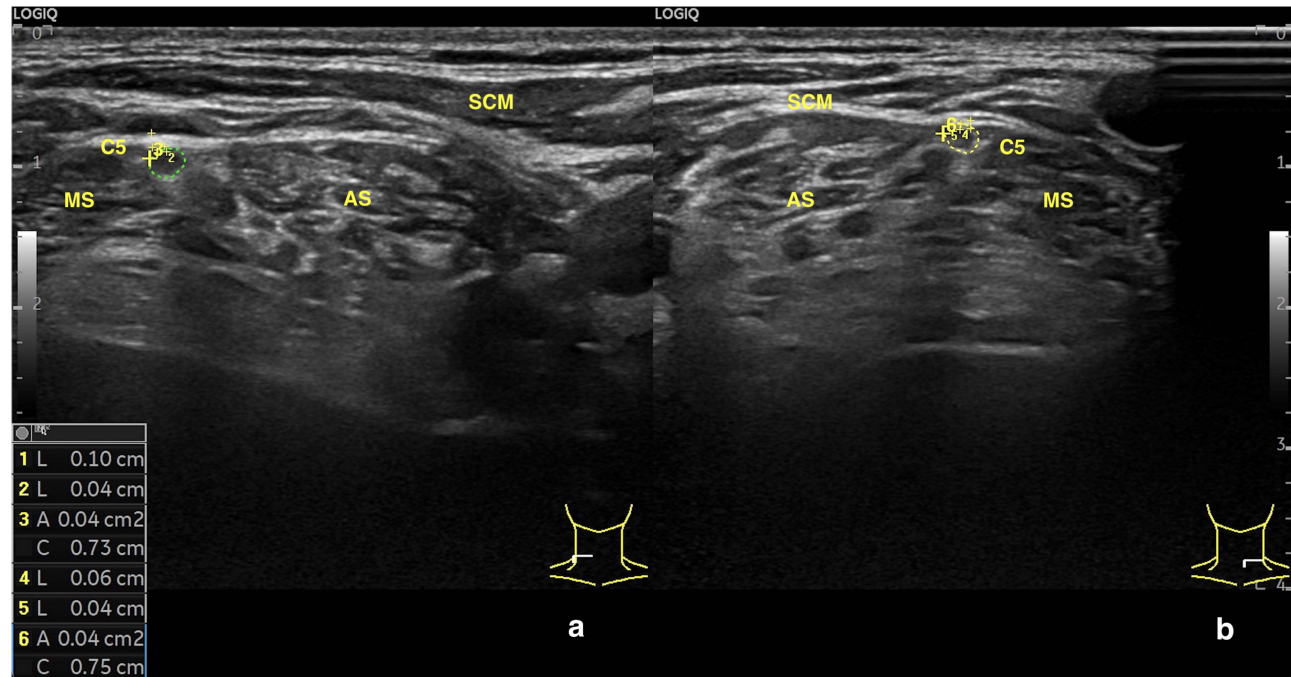


**Figure 1** Flowchart of the trial procedure.



**Figure 2** Preoperative comparison between the NTOS-affected side and the contralateral normal side in the same participant. (a) The thicker prevertebral fascia, the shorter distance between the C5 nerve root and the fascia, and the larger cross-sectional area of the C5 nerve root on the NTOS-affected side; (b) The normal side; C5: the C5 nerve root. Measurements included prevertebral fascia thickness and the distance between the C5 nerve root and the fascia (+); additionally, the C5 nerve root diameter and area were measured (-). **Abbreviations:** AS, the anterior scalene muscle; MS, the middle scalene muscle; SCM, sternocleidomastoid muscle.

with the prevertebral fascia thickness and the distance between the C5 nerve root and the fascia assessed in the longitudinal direction, in alignment with the cervical vertebrae. The normal sides of the NTOS group were measured in the same way. (Figure 3a and b) To affirm localization and consistent evaluation, the measurements were taken relative to the vertebral body.



**Figure 3** The bilateral sides in the same participant from the control group. (a) The right side of the control group; (b) The left side of the control group; C5: the C5 nerve root. Measurements included prevertebral fascia thickness and the distance between the C5 nerve root and the fascia (+); additionally, the C5 nerve root diameter and area were measured (-). **Abbreviations:** AS, the anterior scalene muscle; MS, the middle scalene muscle; SCM, the sternocleidomastoid muscle.

## Ultrasound-Guided

### Hydrodissection and Prevertebral Fascia Incision: A Three-Stage Procedural Protocol

The ultrasound-guided hydrodissection and prevertebral fascial incision procedure was systematically conducted in three sequential stages ([Figure 4](#)), as outlined below:

### Stage 1: Anatomical Localization and Preoperative Preparation

The patient was placed in a supine position to identify the interscalene groove, delineated between the anterior and middle scalene muscles, and to localize the C5 and C6 nerve roots. After performing standard cutaneous antisepsis, a 23-gauge needle attached to a sterile disposable syringe was percutaneously inserted under continuous ultrasound guidance. The needle tip was carefully advanced through subcutaneous tissue layers until reaching the prevertebral fascia enveloping the brachial plexus.

### Stage 2: Targeted Hydrodissection and Fascial Incision

In accordance with established protocols,<sup>15</sup> a 10 mL composite solution—containing triamcinolone acetonide (10 mg/mL, 1 mL), 2% lidocaine (1 mL), and normal saline (8 mL)—was administered under ultrasound visualization to achieve precise hydrodissection of the C5 nerve root and adjacent prevertebral fascia. Particular attention was paid to avoiding critical neurovascular structures during injection ([Video 1](#)). Upon successful release of the C5 nerve root, a specialized needle knife (0.4 × 50 mm; Hanzhang Medical Devices, Hebei, China) was introduced to perform controlled incision of the pathologically thickened prevertebral fascia.

### Stage 3: Multi-Level Neural Decompression

Following fascial incision, comprehensive hydrodissection was subsequently applied to the C5, C6, and C7 nerve roots using the 5mL of normal saline. This step ensured complete perineural decompression and separation of adhesions across multiple cervical levels.

### Outcome Assessment

Ultrasound assessments were performed at baseline (preoperatively), as well as 1- and 6-weeks post-treatment. ([Figure 5a and b](#)) Pain intensity and functional status were assessed by a senior clinician using the Visual Analog Scale (VAS) and the Disabilities of the Arm, Shoulder, and Hand (DASH) scores.

### Statistical Analysis

The nonparametric test (Kolmogorov–Smirnov test) was conducted to verify the distribution of data. The data were normally distributed and expressed as the mean ± standard deviation. The data with non-normally distributed expressed as the median. Age and BMI were compared using one-way analysis of variance with subsequent Dunnett's T3 tests. The rest data were compared using *U*-test. Statistical analyses were performed using SPSS 26.0 (SPSS Inc., IL, USA). A *P* value <0.05 indicated a statistically difference.

## Results

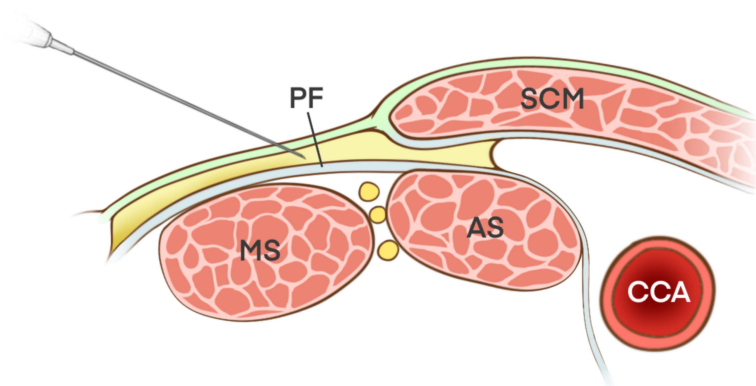
No statistically significant differences were observed between the NTOS group and the healthy control group regarding age, gender, or BMI. Both groups exhibited similar demographic characteristics and baseline data, suggesting that these variables did not confound the comparative analysis of clinical outcomes ([Table 1](#)).

The NTOS group displayed significantly higher DASH scores compared to the healthy control group, indicating a meaningful difference in functional impairment prior to treatment (*p* < 0.05). In addition, the NTOS group presented substantial sensory and motor deficits, which further distinguished them from the control group in terms of functional disability ([Table 1](#)).

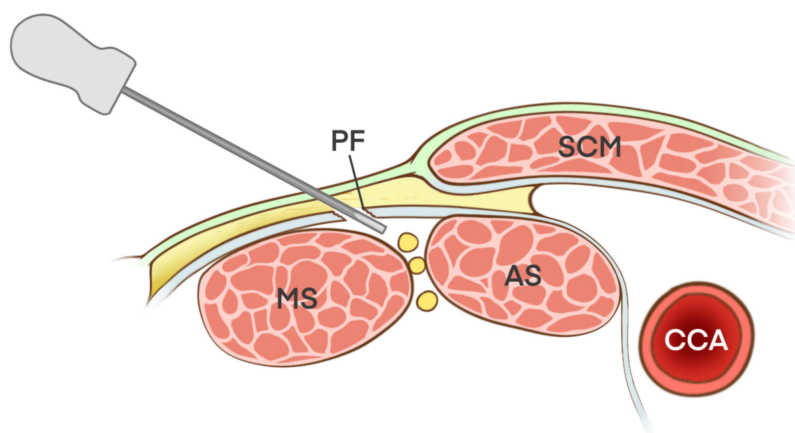
Substantial differences were also identified between the NTOS ([Figure 2](#)) and control ([Figure 3](#)) groups in several ultrasonographic parameters, including the thickness of the prevertebral fascia, the distance between the C5 nerve root and the fascia, and the CSA of the C5 nerve root (*p* < 0.05). Specifically, the NTOS group demonstrated a thicker



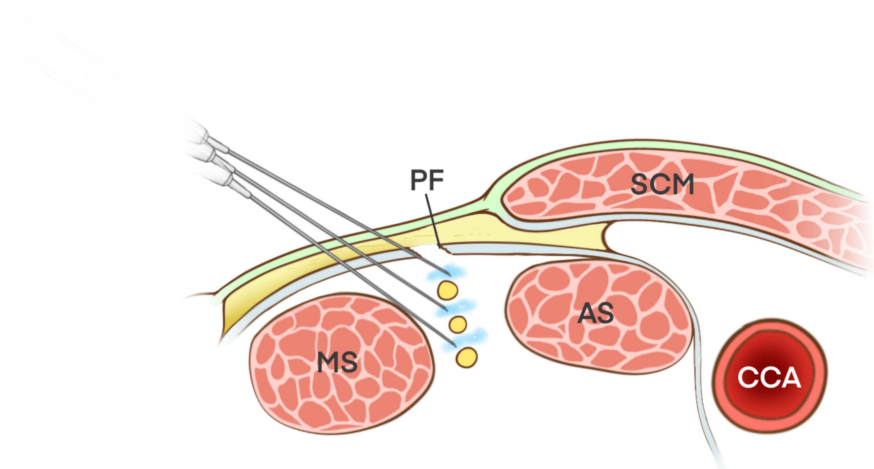
## Step 1



## Step 2

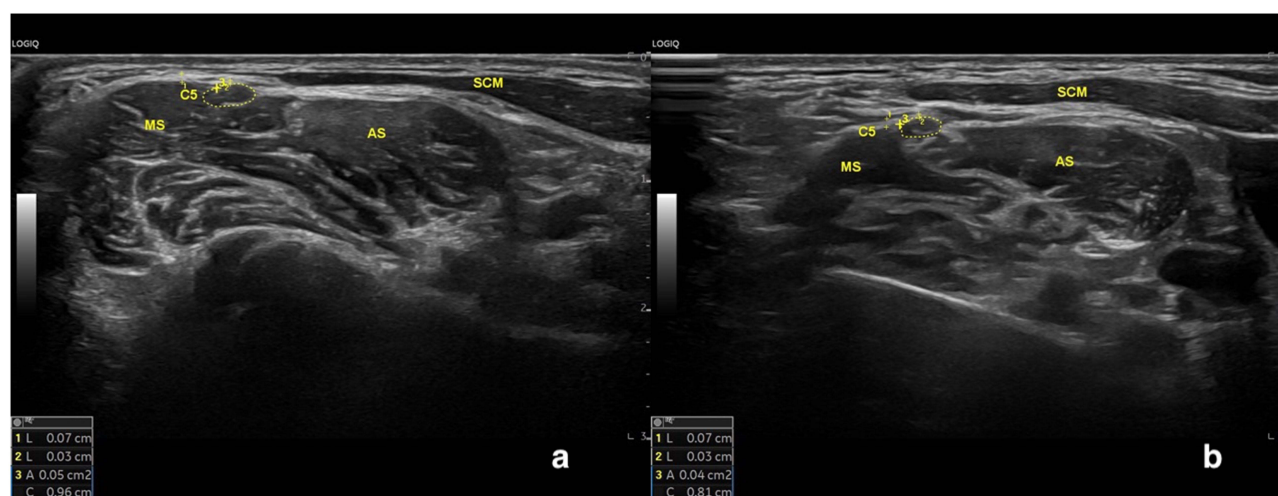


## Step 3



**Figure 4** The ultrasound-guided hydrodissection and prevertebral fascial incision procedure. Step 1: Hydrodissection the prevertebral fascia; Step 2: Fascial incision with needle knife; Step 3: Multi-level neural decompression.

**Abbreviations:** SCM, the sternocleidomastoid muscle; AS, the anterior scalene muscle; MS, the middle scalene muscle; PF, the prevertebral fascia; CCA, the common carotid artery.



**Figure 5** Comparison of the prevertebral fascia, the distance between the C5 nerve root and the fascia, and the cross-sectional area of the C5 nerve root at 1-week and 6-week follow-up in the NTOS group. (a) 1-week follow-up; (b) 6-week follow-up. C5: the C5 nerve root. Measurements included prevertebral fascia thickness and the distance between the C5 nerve root and the fascia (+); additionally, the C5 nerve root diameter and area were measured (-).

**Abbreviations:** AS, the anterior scalene muscle; MS, the middle scalene muscle; SCM, sternocleidomastoid muscle.

prevertebral fascia, a reduced distance between the nerve root and fascia, and a larger CSA of the C5 nerve root. These results indicated the presence of edema in the C5 nerve root among NTOS patients (Figure 2a).

In the NTOS group, both DASH and VAS scores significantly decreased one week postoperatively compared to preoperative values ( $p < 0.05$ ). Moreover, no significant difference was observed between the scores at one week and six weeks postoperatively, indicating sustained improvement throughout the follow-up period (Table 1).

Among the 34 unilateral NTOS patients, all of whom initially presented poor outcomes after standard treatments, subsequent ultrasound-guided hydrodissection resulted in notable improvements in both motor and sensory function, supporting the efficacy of this intervention.

**Table 1** Comparison of Participant Characteristics Between the Neurogenic Thoracic Outlet Syndrome Group and the Normal Control Group, and Across Time Points within the NTOS Group (Pre-Operation, 1 week, and 6 weeks)

Group	NTOS		Controls	
n	34		34	
Gender	Male: 9; Female: 25		Male: 10; Female: 24	
Age (year)	38.24 ± 8.60		36.26 ± 6.04	
BMI (mean ± Sd) (Kg/m <sup>2</sup> )	24.31 ± 2.72		23.63 ± 3.06	
	Pre-operation	1-Week	6-Week	
Thickness of Fascia median (25%, 75%) (mm)	0.10 (0.08, 0.12)*	0.09 (0.07, 0.10) <sup>#</sup>	0.08 (0.07, 0.09) <sup>#</sup>	0.08 (0.07, 0.10)
Distance between C5 and Fascia median (25%, 75%) (mm)	0.13 (0.10, 0.16)*	0.14 (0.10, 0.22)	0.13 (0.10, 0.23)	0.19 (0.14, 0.24)
CSA of C5 median (25%, 75%) (mm <sup>2</sup> )	0.08 (0.06, 0.10)*	0.04 (0.04, 0.05) <sup>#</sup>	0.04 (0.03, 0.05)	0.04 (0.03, 0.05)
DASH	85.00 (82.00, 89.25)*	34.00 (30.75, 36.00) <sup>#</sup>	32.50 (30.00, 36.25) <sup>#</sup>	27.00 (26.00, 30.00)
VAS	7.00 (6.00, 8.00)*	2.00 (2.00, 3.00) <sup>#</sup>	3.00 (2.00, 3.00) <sup>#</sup>	0.00 (0.00, 0.00)

**Notes:** Compared with the control group, \* $P < 0.05$ ; compared with the pre-operation, <sup>#</sup> $P < 0.05$ .

## Discussion

This study assessed the clinical characteristics, diagnostic indicators, and therapeutic outcomes in patients with NTOS, showing substantial functional improvements following ultrasound-guided hydrodissection of the C5 nerve root. The results demonstrate that NTOS patients, in comparison to healthy controls, show an increased thickness of the prevertebral fascia, a reduced distance between the nerve root and the fascia, and a larger CSA of the C5 nerve root. These findings suggest probable nerve compression, which may contribute to the sensory and motor impairments typically seen in NTOS patients.<sup>3</sup>

In alignment with findings from surgical interventions,<sup>16</sup> the significant reduction in DASH and VAS scores observed following treatment supports the efficacy of ultrasound-guided hydrodissection in alleviating pain and functional impairments associated with NTOS. Notably, these improvements were sustained over the 6-week follow-up period, underscoring the potential long-term benefits of this minimally invasive technique.<sup>17</sup> Compared with the transaxillary thoracic outlet decompression (TA-TOD),<sup>9</sup> both procedures specifically target the brachial plexus to alleviate compression, with a focus on the nerve roots, particularly C5 and C6. The TA-TOD method directly addressed the structural causes of nerve compression by resecting ribs and fibrotic tissue around the brachial plexus, while ultrasound-guided hydrodissection indirectly targets the nerve roots by performing hydrodissection of the C5 nerve root and its surrounding fascial structures. In contrast to traditional hydrodissection techniques,<sup>18</sup> this study aimed on the incision of the thickened prevertebral fascia at the C5 level, which may have contributed to a more sustained reduction in the pressure on the brachial plexus nerves within the interscalene groove. Additionally, surgical intervention for TOS was typically considered when conservative management, consisting of 4 to 6 weeks of non-surgical treatment, fails to provide relief and the patient's symptoms worsen.<sup>19</sup> The underlying mechanisms likely include both the mechanical decompression of the C5 nerve root and the anti-inflammatory effects of triamcinolone, which contribute to the reduction in fascial thickness and alleviation of nerve root irritation.<sup>20</sup>

In addition to mechanical decompression, the administration of triamcinolone acetonide, a corticosteroid, enhanced the therapeutic effect through its anti-inflammatory properties. Triamcinolone mitigated local inflammation by inhibiting the production of pro-inflammatory cytokines, including interleukin-1 and tumor necrosis factor- $\alpha$ .<sup>21</sup> In the context of NTOS, where chronic nerve compression induces irritation and inflammation, triamcinolone helped alleviate swelling, reduce fascial thickening, and diminish edema surrounding the nerve root. The anti-inflammatory effects of triamcinolone likely worked synergistically with the mechanical decompression achieved via hydrodissection. By reducing inflammation and edema in the surrounding tissues, triamcinolone contributed to the sustained effectiveness of the decompression, preventing the recurrence of nerve compression. Moreover, the reduction in inflammatory response may have facilitated the healing process, leading to enduring improvements in both sensory and motor functions. Additionally, triamcinolone may have lowered the likelihood of scar tissue formation around the nerve, thus mitigating a potential complication associated with chronic compression.<sup>20</sup>

The notable anatomical differences observed in the NTOS group, presenting the increased thickness of the prevertebral fascia and the reduced distance between the nerve and fascia, underscore the utility of ultrasound as a diagnostic tool for NTOS. The enhanced echogenicity and thickening of the prevertebral fascia, as detected by ultrasound, suggest pathological changes within the paraneural sheath and the surrounding fascial compartments of the brachial plexus cords.<sup>22</sup> These parameters could serve as markers for NTOS, aiding in early diagnosis and appropriate therapeutic decision-making.<sup>6,10</sup> The significant disparities in these ultrasound-measured parameters between NTOS patients and healthy individuals suggest that such measurements could also enhance the specificity of NTOS diagnosis and better delineate the pathophysiology of the syndrome.<sup>7</sup> Compared to the unaffected side, the larger CSA of the C5 nerve root on the symptomatic side suggested edema, a neuropathological change that facilitated the identification of the most likely affected nerve root among the five major trunks of the brachial plexus.<sup>23</sup> Similarly, the involvement of specific fascicles within the affected nerve trunks could be precisely identified by dynamic ultrasonography.<sup>24</sup> Furthermore, the application of ultrasound-guided percussion over the suspected compressed nerve root offers additional diagnostic value, enhancing both the accuracy of TOS diagnosis and the effectiveness of subsequent treatment strategies.



This study has several limitations, including its retrospective design, small sample size, and the reliance on subjective assessment tools, such as the DASH and VAS scores, to evaluate functional outcomes. To enhance the robustness and generalizability of the findings, future research with larger, prospective cohorts is needed to validate the reproducibility of ultrasound-guided hydrodissection results across a broader range of patient populations.<sup>25</sup> Moreover, while the focus of our investigation was primarily on the C5 nerve root, exploring interventions concentrated on additional components of the brachial plexus could offer a extra complete information of treatment efficacy, particularly in NTOS sufferers with multilevel nerve involvement.<sup>26</sup> Importantly, no complications were observed in the cohort undergoing ultrasound-guided hydrodissection of the C5 nerve root, reinforcing the safety and established effectiveness of this technique. Based on these findings, we conclude that ultrasound-guided hydrodissection holds clinical potential for the treatment of NTOS, particularly in cases without associated upper limb atrophy.

In conclusion, ultrasound-guided hydrodissection shows promising efficacy in treating NTOS by reducing pain and improving function, likely through alleviating C5 nerve compression and reducing inflammatory responses. These findings support the integration of targeted ultrasound diagnostics and minimally invasive treatments in the management of NTOS, with ability implications for optimizing clinical outcomes in patients affected by this often-debilitating condition.<sup>25</sup>

## Disclosure

The authors report no conflicts of interest in this work.

## References

- Panther EJ, Reintgen CD, Cueto RJ, Hao KA, Chim H, King JJ. Thoracic outlet syndrome: a review. *J Shoulder Elbow Surg.* 2022;31(11):e545–e561. doi:10.1016/j.jse.2022.06.026
- Illig KA, Rodriguez-Zoppi E, Bland T, Muftah M, Jospitre E. The incidence of thoracic outlet syndrome. *Ann Vasc Surg.* 2021;70:263–272. doi:10.1016/j.avsg.2020.07.029
- Jones MR, Prabhakar A, Viswanath O, et al. Thoracic outlet syndrome: a comprehensive review of pathophysiology, diagnosis, and treatment. *Pain Ther.* 2019;8(1):5–18. doi:10.1007/s40122-019-0124-2
- Tejjink SBJ, Pesser N, Goeteyn J, et al. General overview and diagnostic (imaging) techniques for neurogenic thoracic outlet syndrome. *Diagnostics.* 2023;13(9):1625. doi:10.3390/diagnostics13091625
- Hwang JS, Kim J, Kim S, Bae KJ, Lee Y, Baek GH. Diagnosis of neurogenic thoracic outlet syndrome based on the clinical status. *Ann Vasc Surg.* 2021;76:454–462. doi:10.1016/j.avsg.2021.03.051
- Sabr NS, Abdullah F, Namiq HS, et al. Role of ultrasound in diagnosis of thoracic outlet syndrome: a review article. *Barw Medical Journal.* 2023.
- Jengojan S, Bernathova M, Moritz T, Bodner G, Sorgo P, Kasprian G. High-resolution ultrasound and magnetic resonance imaging of abnormal ligaments in thoracic outlet syndrome in a series of 16 cases. *Front Neurosci.* 2022;15:817337. doi:10.3389/fnins.2021.817337
- Dengler NF, Ferraresi S, Rochkind S, et al. Thoracic outlet syndrome part i: systematic review of the literature and consensus on anatomy, diagnosis, and classification of thoracic outlet syndrome by the European Association of neurosurgical societies' section of peripheral nerve surgery. *Neurosurgery.* 2022;90(6):653–667. doi:10.1227/neu.0000000000001908
- Goeteyn J, Pesser N, Houterman S, et al. Surgery versus continued conservative treatment for neurogenic thoracic outlet syndrome: the first randomised clinical Trial (STOPNTOS Trial). *Eur J Vasc Endovascular Surg.* 2022;64(1):119–127. doi:10.1016/j.ejvs.2022.05.003
- Warrick A, Davis B. Neurogenic thoracic outlet syndrome in athletes — nonsurgical treatment options. *Curr Sports Med Reports.* 2021;20(6):319–326. doi:10.1249/jsr.0000000000000854
- Rochkind S, Ferraresi S, Denisova N, et al. Thoracic outlet syndrome part II: consensus on the management of neurogenic thoracic outlet syndrome by the European Association of neurosurgical societies' section of peripheral nerve surgery. *Neurosurgery.* 2023;92(2):251–257. doi:10.1227/neu.0000000000002232
- Donahue DM, Godoy IR, Gupta R, Donahue JA, Torriani M. Sonographically guided botulinum toxin injections in patients with neurogenic thoracic outlet syndrome: correlation with surgical outcomes. *Skeletal Radiology.* 2020;49:715–722. doi:10.1007/s00256-019-03331-9
- Illig KA, Donahue D, Duncan A, et al. Reporting standards of the society for vascular surgery for thoracic outlet syndrome. *J Vasc Surg.* 2016;64(3):e23–35. doi:10.1016/j.jvs.2016.04.039
- Feigl GC, Litz RJ, Marhofer P. Anatomy of the brachial plexus and its implications for daily clinical practice: regional anesthesia is applied anatomy. *Reg Anesth Pain Med.* 2020;45(8):620–627. doi:10.1136/rapm-2020-101435
- Lam KHS, Hung CY, Chiang YP, et al. Ultrasound-guided nerve hydrodissection for pain management: rationale, methods, current literature, and theoretical mechanisms. *J Pain Res.* 2020;13:1957–1968. doi:10.2147/jpr.S247208
- Blondin M, Garner GL, Hones KM, Nichols DS, Cox EA, Chim H. Considerations for surgical treatment of neurogenic thoracic outlet syndrome: a meta-analysis of patient-reported outcomes. *J Hand Surg.* 2023;48(6):585–594. doi:10.1016/j.jhsa.2023.03.005
- Buntragulpontawee M, Chang KV, Vitoonpong T, et al. The effectiveness and safety of commonly used injectates for ultrasound-guided hydrodissection treatment of peripheral nerve entrapment syndromes: a systematic review. *Front Pharmacol.* 2020;11:621150. doi:10.3389/fphar.2020.621150
- Nicolosi C, Ford J, Meron A. Hydrodissection of peripheral nerve entrapments. *Curr Phys Med Rehabil Rep.* 2023;11(3):265–271. doi:10.1007/s40141-023-00405-7

19. Li N, Dierks G, Vervaeke HE, et al. Thoracic outlet syndrome: a narrative review. *J Clin Med.* 2021;10(5):962. doi:10.3390/jcm10050962
20. Wang J-C, Hsu P-C, Wang KA, Chang K-V. Ultrasound-guided triamcinolone acetone hydrodissection for carpal tunnel syndrome: a randomized controlled trial. *Front Med.* 2021;8:742724. doi:10.3389/fmed.2021.742724
21. Itakura H, Akiyama H, Hagimura N, et al. Triamcinolone acetone suppresses interleukin-1 beta-mediated increase in vascular endothelial growth factor expression in cultured rat Müller cells. *Graefes Arch Clin Exp Ophthalmol.* 2006;244(2):226–231. doi:10.1007/s00417-005-0052-1
22. Areeruk P, Karmakar MK, Reina MA, Mok LYH, Sivakumar RK, Sala-Blanch X. High-definition ultrasound imaging defines the paraneural sheath and fascial compartments surrounding the cords of the brachial plexus at the costoclavicular space and lateral infraclavicular fossa. *Reg Anesth Pain Med.* 2021;46(6):500–506. doi:10.1136/rapm-2020-102304
23. Koneru S, Nguyen VT, Hacquebord JH, Adler RS. Brachial plexus nerve injuries and disorders: mr imaging-ultrasound correlation. *Magnetic Resonance Imaging Clin North Am.* 2023;31(2):255–267. doi:10.1016/j.mric.2023.01.006
24. Lam SKH, Hung C-Y, Clark TB. Loss of the “seesaw sign” of the sciatic nerve in a marathon runner complaining of hamstring cramping. *Pain Med.* 2020;21(2):e247–e248. doi:10.1093/pm/pnz283
25. Dengler NF, Pedro MT, Kretschmer T, Heinen C, Rosahl SK, Antoniadis G. Neurogenic Thoracic Outlet Syndrome. *Dtsch Arztebl Int.* 2022;119(43):735. doi:10.3238/arztebl.m2022.0296
26. Sveva V, Fari G, Fai A, et al. Safety and efficacy of ultrasound-guided perineural hydrodissection as a minimally invasive treatment in carpal tunnel syndrome: a systematic review. *J Personalized Med.* 2024;14(2):154. doi:10.3390/jpm14020154

## Journal of Pain Research

### Publish your work in this journal

The Journal of Pain Research is an international, peer reviewed, open access, online journal that welcomes laboratory and clinical findings in the fields of pain research and the prevention and management of pain. Original research, reviews, symposium reports, hypothesis formation and commentaries are all considered for publication. The manuscript management system is completely online and includes a very quick and fair peer-review system, which is all easy to use. Visit <http://www.dovepress.com/testimonials.php> to read real quotes from published authors.

Submit your manuscript here: <https://www.dovepress.com/journal-of-pain-research-journal>

**Dovepress**  
Taylor & Francis Group