

Graves' thyrotoxicosis following Hashimoto's thyroiditis

A Troisi¹
P Novati¹
L Sali¹
M Colzani¹
G Monti¹
C Cardillo³
M Tesauro²

¹Division of Internal Medicine, Saronno Hospital, Italy; ²Department of Internal Medicine, Tor Vergata Clinical Center, University of Rome, Rome, Italy; ³Department of Internal Medicine, Università Cattolica del Sacro Cuore, Rome, Italy

Abstract: Autoimmune thyroid disease traditionally includes chronic thyroiditis, autoimmune hyperthyroidism (Graves' disease), and primary nongitrous myxedema, and these diseases have a common syndrome-sharing pathophysiology. Here we report a rare case of simultaneous occurrence of thyrotoxicosis linked to Graves' disease and chronic hypothyroidism due to Hashimoto's thyroiditis.

Keywords: Hashimoto's thyroiditis, Graves' disease, autoimmune thyroid disorders

We report a rare case of simultaneous occurrence of thyrotoxicosis linked to Graves' disease and chronic hypothyroidism due to Hashimoto's thyroiditis (HT).

Description

We observed a 55-year-old woman with hypothyroidism of at least 10 years duration as a consequence of HT. She required replacement levothyroxin therapy. She had a typical ultrasound thyroiditic inhomogeneous pattern (Figure 1). No other medical history of autoimmunity was detected. She presented with neck pain, resting tremor of the fingers, sweating, anxiety, heat intolerance, weakness, and light weight loss. Physical examination revealed a heart rate of 120 beats per minute, a diffusely enlarged and tender thyroid gland, and mild tibial edema. Laboratory baseline values were: thyrotrophin < 0.01 mIU/mL (0.30–4.00), free thyroxine > 6.0 ng/dL (nL 0.8–1.70), free triiodothyronine 19.6 pg/mL (nL 1.8–5.0), thyroglobulin antibody 165 IU/mL (nL 0–55), thyroperoxidase antibody 470 IU/mL (nL 0–35), thyroid-stimulating hormone receptor antibody (TSHR) 21.9 IU/L (nL = 0–1), erythrocyte sedimentation rate 37 mm/hour (nL 0–20), and C-reactive protein 0.50 mg/dL (nL 0–0.5). A thyroid ultrasound showed an enlarged homogeneous gland with mild hypervascularity. The thyroid scan (technetium-99 m pertechnetate imaging) showed a diffusely enlarged gland with widespread trapping despite the interference of the levothyroxin replacement therapy (Figure 2). Over the next several weeks, she required high doses of thyrostatic treatment (thiamazole 30 mg/day) with additional small steroid doses (prednisolone 10 mg); she remained on this therapy for at least four months, and then we stopped steroid therapy and reduced thiamazole.

Discussion

Rare cases of severe thyrotoxicosis due to Graves' disease occurring many years after the development of chronic thyroiditis have been reported.¹ We describe a case where a mild thyrotoxicosis associated with high widespread (technetium-99m pertechnetate)

Correspondence: Manfredi Tesauro
Internal Medicine Department,
University of Rome Tor Vergata,
Viale Oxford 81-00133, Rome, Italy
Tel +39 06 2090 2501
Fax +39 06 2090 2679
Email mtesauro@tiscali.it

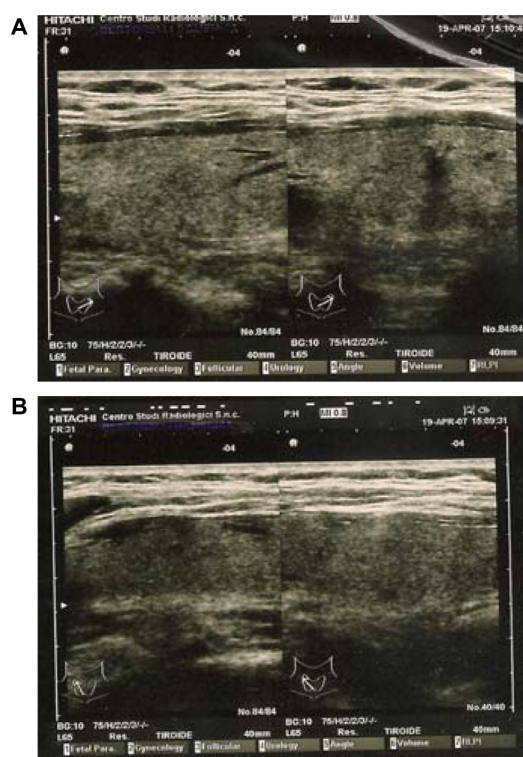


Figure 1 Thyroid ultrasound (during Hashimoto's thyroiditis period). (A) left lobe; (B) right lobe.

Note: We can observe an inhomogeneous ultrasound pattern on both lobes.

trapping developed in a patient on replacement levothyroxin therapy. Although Graves' disease in remission may precede the onset of HT by several years, the development of Graves' disease many years after HT is rare. Autoimmune thyroid disease (AITD) traditionally includes chronic thyroiditis, autoimmune hyperthyroidism (Graves' disease), and primary nongitrous myxedema, and these diseases have a common syndrome-sharing pathophysiology.²

Graves' disease is the result of a complex and abnormal immune response involving TSHR, TSHR-specific T cells,

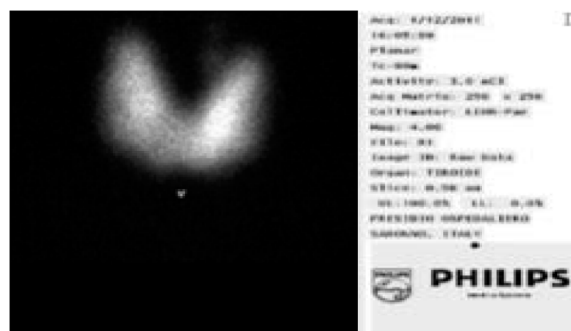

Figure 2 Thyroid scan (technetium-99m pertechnetate imaging) patient under treatment (75 µg replacement levothyroxine therapy).

Note: We observed a diffusing and homogeneous thyroid radiotracer uptake.

and TSHR autoantibodies and is thought to be secondary to an interaction between susceptibility genes and environmental triggers.³ Graves' disease has been known for many years to have familial predisposition. Several genes and loci have been linked or associated with AITD. However, evidence of associating polymorphisms in the most obvious candidate, the TSHR gene, with Graves' disease has been surprisingly weak.

In contrast, major histocompatibility complex, class II DR3 (HLA-DR3) was the first Graves disease susceptibility gene identified. Cytotoxic T-lymphocyte protein 4b (CTLA4b), protein tyrosine phosphatase non receptor type 22 (PTPN22), and CD40 are important co-stimulatory molecules that have been shown to be weakly and functionally associated with autoimmune diseases, including Graves' disease, eumathoid arthritis, systemic erithematoidis lupus, and diabetes mellitus type 1.³ In addition to these immune response-related genes, several studies have shown that the gene encoding thyroglobulin is a major gene involved in TSHR-related autoimmunity.^{3,4}

Important environmental potential risk factors have been implicated in the etiology of AITD, including dietary iodine intake, smoking, stress, pregnancy, exposure to radiation, and infection. It should also be noted that several environmental factors seem involved in the etiology of AITD, including dietary iodine intake, smoking, stress, pregnancy, exposure to radiation, and infection.

Conclusion

Autoimmune thyroid disorders are associated with genetically mediated mechanisms (as seen in patients with HLA typing, combined clusters of gastric and adrenal autoimmunity, and strong family history), but these features were not noted in this patient. We instead propose that triggers that alter the balance between thyroid stimulating and thyroid blocking antibody activities may include novel environmental factors as "thyroid disruptors" (for example, the patient was born in a region polluted with dioxin). This case additionally demonstrates that important changes in autoimmune activity on thyroid cells can occur many years after a previous response.

Disclosure

The authors report no conflicts of interest in this work.

References

1. Takasu N, Yamada T, Sato A, et al. Graves' disease following hypothyroidism due to Hashimoto's disease: studies of eight cases. *Clin Endocrinol (Oxf)*. 1990;33:687–698.

2. Shong YK, Cho BY, Hong SK, Lee HK, Koh CS, Min HK. Pathogenetic role of thyrotropin receptor antibody in the development of hyperthyroidism following primary hypothyroidism. *Korean J Intern Med*. 1989;4(2): 118–124.
3. Davies TF, Ando T, Yi Lin R, Tomer Y, Latif R. Thyroid receptor-associated disease: from adenomata to Graves. *J Clin Invest*. 2005;115: 1972–1983.
4. Collins JE, Heward JM, Carr-Smith J, Daykin J, Franklyn JA, Gough SC. Association of a rare thyroglobulin gene microsatellite variant with autoimmune thyroid disease. *J Clin Endocrinol Metab*. 2003;88(10):5039–5042.

Research and Reports in Endocrine Disorders

Publish your work in this journal

Research and Reports in Endocrine Disorders is an international, peer-reviewed, open access journal publishing original research, reports, reviews and commentaries on all areas of endocrinology, endocrine disorders and therapeutic interventions. The manuscript management system is completely online and includes a very quick and fair

Submit your manuscript here: <http://www.dovepress.com/research-and-reports-in-endocrine-disorders-journal>

peer-review system. Visit <http://www.dovepress.com/testimonials.php> to read real quotes from published authors.

Dovepress