

High expression of HMGA2 predicts poor survival in patients with clear cell renal cell carcinoma

Ning Na^{1,*}
Tujie Si^{2,*}
Zhengyu Huang^{1,*}
Bin Miao¹
Liangqing Hong¹
Heng Li¹
Jiang Qiu²
Jianguang Qiu³

¹Department of Kidney Transplantation, The Third Affiliated Hospital of Sun Yat-sen University, ²Department of Organ Transplant, The First Affiliated Hospital of Sun Yat-sen University, ³Department of Urology, The Third Affiliated Hospital of Sun Yat-sen University, Guangzhou, People's Republic of China

*These authors contributed equally to this work

Abstract: High-mobility group AT-hook 2 (HMGA2) is involved in a wide spectrum of biological processes and is upregulated in several tumors, but its role in renal carcinoma remains unclear. The aim of this study was to examine the expression of HMGA2 and its relationship to the overall survival (OS) of patients with non-metastatic clear cell renal cell carcinoma (ccRCC) following surgery. The expression of HMGA2 was evaluated retrospectively by immunohistochemistry (IHC) in 162 patients with ccRCC who underwent nephrectomy in 2003 and 2004. An IHC analysis revealed that HMGA2 was expressed in the nuclei of tumor cells in 146 (90.1%) patients with ccRCC. The level of HMGA2 was positively correlated with tumor size, lymph node metastasis, and Fuhrman Grade. A Kaplan–Meier analysis with log-rank test found that patients with high HMGA2 expression had a poor outcome and that patients with low HMGA2 expression had better survival. Cox regression analysis showed that HMGA2 expression could serve as an independent prognostic factor for ccRCC patients. The efficacy of the following prognostic models was improved when HMGA2 expression was added: tumor node metastasis stage, UCLA Integrated Scoring System, Mayo Clinic stage, size, grade, and necrosis score. In summary, this study showed that HMGA2 expression is an independent prognostic factor for OS in patients with ccRCC. HMGA2 was found to be a valuable biomarker for ccRCC progression.

Keywords: renal carcinoma, high-mobility group protein A, prognosis

Introduction

Renal cell carcinoma (RCC) is the most common urologic tumor in adults and accounts for approximately 3% of all human malignancies.¹ Clear cell renal cell carcinoma (ccRCC), which is the most common histological subtype of RCC, accounts for 85% to 90% of renal malignancies and has the worst prognosis among RCCs.² Surgery is the preferred treatment for localized ccRCC, but as many as 30% of patients who undergo surgery with curative intent experience local recurrence or distant metastasis, which often leads to a poor prognosis.³ Traditional prognostic factors, such as tumor node metastasis (TNM) stage, presence of necrosis, and ECOG-PS, as well as a combination of these factors provide a useful benchmark to determine prognosis and select a treatment strategy. However, sometimes discrepancies arise between predictions and practical clinical outcomes.⁴ Recent studies have revealed a number of prognostic biomarkers that are associated with different features of RCC biology, and novel models that combine conventional clinicopathological factors with molecular biomarkers have been established to allow for more a precise prediction of clinical outcomes.^{5–8} Therefore, it is of great value to seek molecular markers that will improve the individual therapeutic management and clinical outcome of patients with ccRCC.

Correspondence: Jianguang Qiu
Department of Urology, The Third
Affiliated Hospital of Sun Yat-sen
University, Guangzhou, Guangdong
Province 510630, People's Republic
of China
Tel +86 20 8525 2175
Fax +86 20 8525 3336
Email qiujianguang_sysu@126.com

The high-mobility group A (HMGA) protein family comprises the high-mobility group AT-hook 1 (HMGA1; coded by a gene on chromosome 6p21 through alternative splicing) and high-mobility group AT-hook 2 (HMGA2; coded by a gene on chromosome 12q14-15) proteins, which are characterized by their ability to bind to nucleotide sites rich in adenine and thymine.⁹ The HMGA proteins act as architectural transcription factors by altering the conformation of transcription factors and the chromatin structure, and thus these proteins modulate gene transcription.¹⁰ HMGA proteins are expressed at high levels during embryonic development, whereas their expression is strongly reduced or nearly absent in adult organs.¹¹ The re-expression of both HMGA1 and HMGA2 at high levels in adults is seen in a variety of malignant and benign tumors.^{10,12} It has been generally recognized that both the HMGA1 and HMGA2 proteins play a role in malignant cell transformation and progression of several tumor types. Recent studies have revealed that HMGA1 is overexpressed in RCC and plays a key role in the control of the aggressiveness of renal cancer cells.¹² However, the role of HMGA2 in renal carcinoma is still unknown.

In this study, we examined the expression of HMGA2 by IHC in ccRCC tissues derived from patients who underwent radical surgery. We then aimed to evaluate the association between HMGA2 expression and prognosis and its potential utility as a prognostic marker for ccRCC to develop a better understanding of the role of HMGA2 in ccRCC.

Materials and methods

Patients and samples

The current study included 162 patients with localized or locally advanced ccRCC who presented at The First Affiliated Hospital and The Third Affiliated Hospital of Sun Yat-sen University between 2003 and 2004. The histological type of all specimen sections was determined by experienced pathologists, and all samples were diagnosed as conventional ccRCC. The clinical tumor stages and characteristics were classified according to the TNM classification system. The original inclusion criteria were as follows: 1) patients who received radical nephrectomy by either the open approach or by laparoscopy; 2) confirmation of ccRCC by postoperative histopathologic diagnosis; 3) no radiotherapy or chemotherapy before surgery; and 4) M=0 based on the JCC TNM classification. Patients who died of postoperative complications were excluded. This research is in compliance with the Helsinki Declaration and was approved by the Institutional Ethics Review Committee of Sun Yat-sen University. Written informed consents were obtained from all patients involved in this study.

Immunohistochemistry

IHC was performed on paraffin-embedded samples of the primary carcinomas from 162 patients. The pathological sections were deparaffinized in xylene and rehydrated in a graded series of ethanol, followed by antigen retrieval in a microwave. The sections were incubated with 0.3% hydrogen peroxide for 10 min at room temperature to quench the activity of endogenous peroxidase. The sections were then incubated with a rabbit HMGA2 polyclonal antibody (Abcam; Rabbit polyclonal to HMGA2; ab52039) overnight at 4°C at an optimal working dilution of 1:100. After sufficient rinses in phosphate buffered saline (PBS), the sections were incubated with goat anti-rabbit polymers. The staining was scored by two independent investigators who were blinded to the clinicopathological and prognostic data. The staining intensity (0: negative, 1: weak staining, 2: moderate staining, and 3: strong staining) and staining extent (0–100) were evaluated in ten randomly selected high-power fields. A semiquantitative IHC score was generated by calculating the product of the staining intensity and the percentage of cells stained; final scores that ranged from 0 to 300 for each sample were obtained.

Statistical analysis

SPSS 17.0 statistical software package (SPSS Inc., Chicago, IL, USA) and Stata 12.0 (StataCorp, College Station, TX, USA) were used for all statistical analyses in this study. The frequency distributions were compared by χ^2 test. Continuous variables were compared using Student's *t*-test. The primary outcome measure was the length of survival as measured from the time of the original surgery. Kaplan–Meier survival analysis was used to assess the overall survival (OS), whereas the significant differences between survival curves were determined by the log-rank test. Variables that were found to be significant on univariate analysis at $P \leq 0.05$ were included in multivariate analyses. Cox proportional hazards models were generated for multivariate analyses. All *P*-values < 0.05 were considered statistically significant by a two-tailed test.

Results

Immunohistochemical findings

To evaluate the role of HMGA2 in ccRCC, we first evaluated HMGA2 expression by IHC in 162 specimens from patients with ccRCC. HMGA2 expression was detected in the tumor cell nuclei of 146 (90.1%) cases of ccRCC. Samples from eleven cases showed complete negative staining. Representative immunohistochemical staining results are shown

in Figure 1. A semiquantitative IHC score was adopted as described in “Materials and methods” section, and the schematic diagram of scoring is shown in Figure 2. The specific staining scores with variable staining intensity in the different specimens ranged from 0 to 290. A median score of 106 was adopted as a cutoff to segregate all samples into either the low expression group (0–106) or the high expression group (107–290).

Correlation between patient characteristics and HMGA2 expression

The demographic data and clinicopathological characteristics are summarized in Table 1. The present cohort included 58 male and 104 female patients with a mean age of 52.6 ± 10.6 years. The mean tumor diameter was 4.5 ± 2.5 cm,

and the TNM staging distribution was as follows: stage I, 42 patients; stage II, 72 patients; stage III, 41 patients; and stage IV, 7 patients. In addition, the Fuhrman staging distribution was as follows: grade I, 44 patients; grade II, 60 patients, grade III, 37 patients, and grade IV, 21 patients. Histological necrosis was observed in 36 (22.2%) patients, and microvascular invasion (MVI) was observed in 26 (16.0%) patients. Moreover, lymph node metastasis was present in 29 (17.1%) patients at the time of surgery.

High expression of HMGA2 in the tumor cell nuclei was significantly associated with large tumor size ($P=0.043$), lymph node metastasis ($P=0.027$), and higher Fuhrman grade ($P=0.036$). A borderline significant correlation was observed between HMGA2 nuclear staining and lymph node metastasis ($P=0.027$). However, no significant correlation was observed

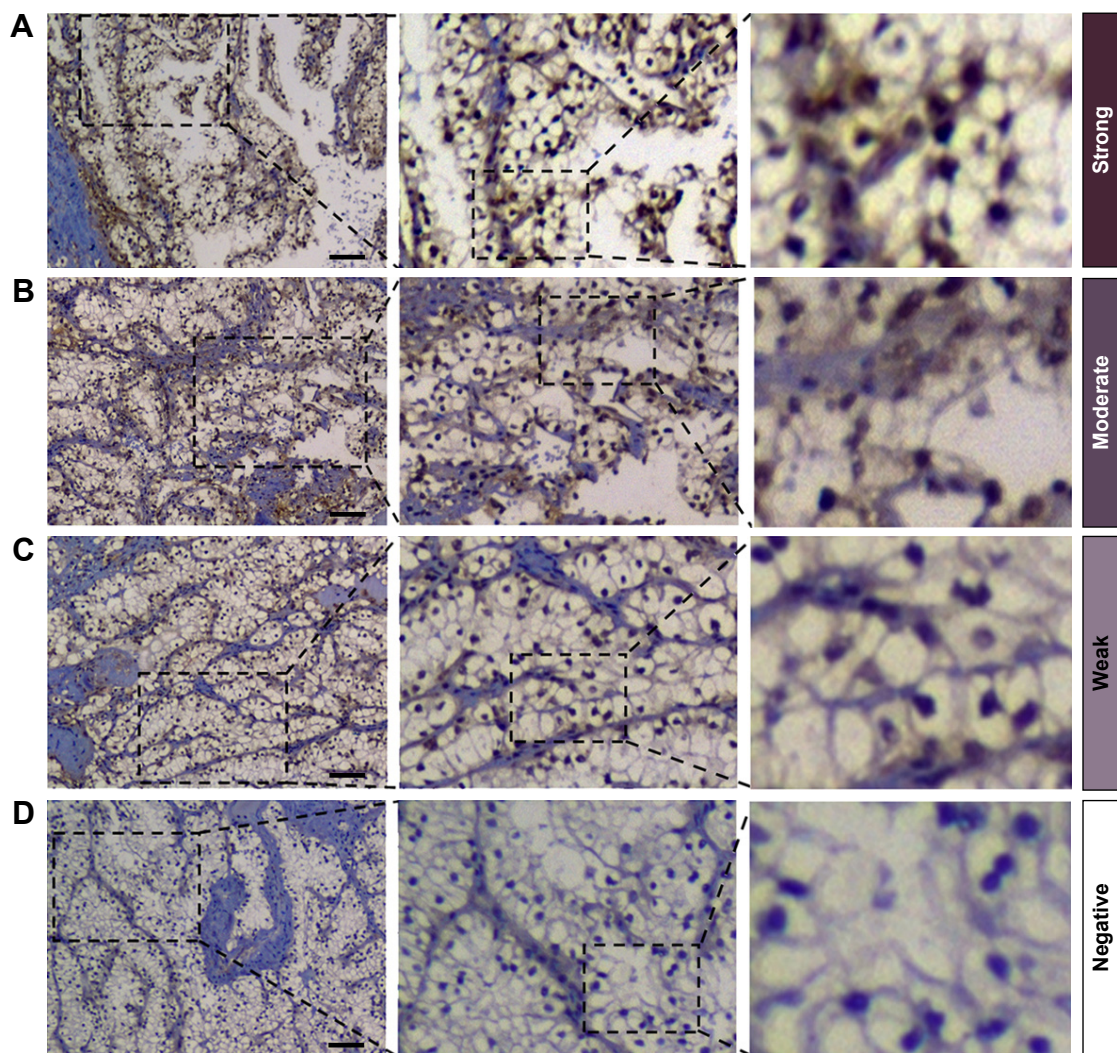


Figure 1 Typical immunohistochemical staining samples and the corresponding staining intensities of HMGA2 in ccRCC tissues.

Notes: (A) Renal carcinoma tissues showed strong nuclear HMGA2 staining. (B) Renal carcinoma tissues showed moderate nuclear HMGA2 staining. (C) Renal carcinoma tissues showed weak HMGA2 staining. (D) Renal carcinoma tissues showed negative HMGA2 staining. Bars: 50 μ m.

Abbreviations: HMGA2, high-mobility group AT-hook 2; ccRCC, clear cell renal cell carcinoma.

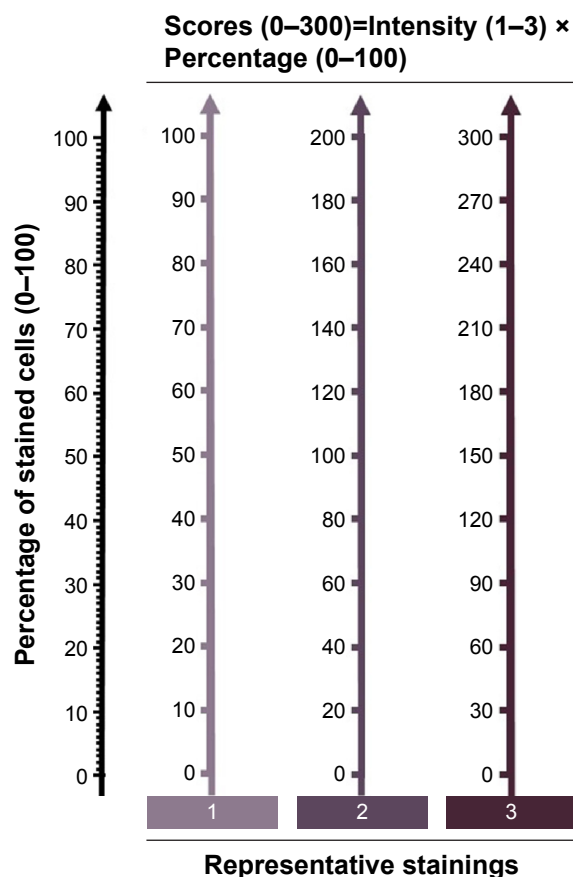


Figure 2 Schematic diagram of scoring.

Notes: The intensity score was obtained based on staining intensity as following: negative, 0; weak, 1; moderate, 2; and strong, 3. Meanwhile, the percentage (1–100) of stained cells was also evaluated in ten randomly selected high-power field. The total score was the product of intensity score and percentage value.

between HMGA2 nuclear staining and patient age, sex, tumor stage, necrosis, or MVI.

Prognostic impact of HMGA2 expression

Based on the IHC scores for HMGA2, a median score of 106 was adopted as a cutoff to classify all samples into the low expression group (0–106, $n=86$) or the high expression group (107–290, $n=76$). Kaplan–Meier curves were constructed to determine whether HMGA2 expression was correlated with OS in these two groups. Sixty-one patients in the cohort died before the last follow-up. A Kaplan–Meier survival analysis showed that high HMGA2 expression was associated with decreased OS ($P<0.001$), as shown in Figure 3.

To identify whether HMGA2 expression was an independent prognostic factor in patients with ccRCC, univariate and multivariate analyses were applied for OS. As presented in Table 2, by univariate analysis, we found that HMGA2 expression (hazard ratio [HR] = 2.815, 95% confidence interval [CI] 1.528–5.186; $P<0.001$), together with tumor size, pT stage, pN stage, Fuhrman grade, and the presence of MVI,

Table 1 Correlation between HMGA2 expression and clinicopathological characters in patients with ccRCC

Variable	Patients n=162	HMGA2 expression		P-value ^b
		Low (n=86)	High (76)	
Age, years (mean ± sd)	52.6±10.6	51.8±10.2	53.5±11.0	
Sex				0.795
Female	58, 37.7%	30, 34.9%	28, 26.8%	
Male	104, 62.3%	56, 65.1%	48, 63.2%	0.043
Tumor size, cm (mean ± sd)	4.5±2.5	4.1±2.5	4.9±2.6	
pT stage^a				0.144
T1	42, 25.9%	25, 29.1%	17, 22.4%	
T2	72, 44.4%	42, 48.8%	30, 39.5%	
T3	41, 25.3%	17, 19.8%	24, 31.6%	
T4	7, 4.3%	2, 2.3%	5, 6.6%	
pN stage^a				0.027
Nx-N0	133, 82.1%	76, 88.4%	57, 75.0%	
N1	29, 17.9%	10, 11.6%	19, 25.0%	
Necrosis				0.239
Absent	126, 77.8%	70, 81.4%	56, 73.7%	
Present	36, 22.2%	16, 18.6%	20, 26.3%	
Fuhrman grade				0.036
1	44, 27.2%	30, 34.9%	14, 18.4%	
2	60, 37.0%	34, 39.5%	26, 34.2%	
3	37, 22.8%	14, 16.3%	23, 30.3%	
4	21, 13.0%	8, 9.3%	13, 17.1%	
MVI				0.439
Absent	136, 84.0%	74, 86.0%	62, 81.6%	
Present	26, 16.0%	12, 14.0%	14, 18.4%	

Notes: ^aThe pT stage and pN stage were classified according to 2010 AJCC TNM classification. ^bStudent's *t*-test for continuous variables and χ^2 test for categorical variables.

Abbreviations: HMGA2, high-mobility group AT-hook 2; ccRCC, clear cell renal cell carcinoma; sd, standard deviation; MVI, microvascular invasion; TNM, tumor node metastasis.

demonstrated a significant association with survival. Further, multivariate Cox regression analysis determined that high HMGA2 expression was a significant negative independent prognostic indicator for patients with ccRCC in an analysis of OS (HR 3.116; 95% CI: 1.643–5.901; $P<0.001$).

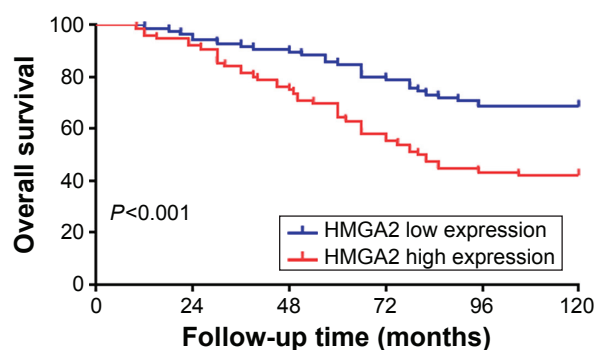


Figure 3 Kaplan–Meier analysis of overall survival of patients with clear cell renal cell carcinoma based on HMGA2 expression.

Note: P-value was calculated by log-rank test.

Abbreviation: HMGA2, high-mobility group AT-hook 2.

Table 2 Univariate and multivariate cox regression analysis identified potential predictors of overall survival in 162 patients with ccRCC

Variable	Univariate			Multivariate		
	HR	95% CI	P-value	HR	95% CI	P-value
Tumor size, cm	1.216	1.011–1.426	0.038	1.172	0.966–1.422	0.108
pT stage						
pT1		Reference				
pT2	2.107	1.126–3.943	0.020	2.266	1.311–3.917	0.003
pT3	3.215	1.017–10.163	0.048	3.346	0.911–12.290	0.069
pT4	4.812	0.512–45.225	0.169	5.011	0.719–34.924	0.103
pN stage						
pNx + pN0		Reference				
pN1	8.912	3.162–25.118	<0.001	6.127	2.176–17.254	<0.001
Fuhrman grade						
1		Reference				
2	1.316	0.911–1.901	0.143	1.255	0.951–1.656	0.109
3	2.431	1.432–4.126	<0.001	2.016	1.036–3.923	0.039
4	5.712	1.491–21.885	0.011	6.112	1.636–22.833	0.007
MVI						
Absent		Reference				
Present	1.423	1.025–2.238	0.037	1.311	0.793–2.167	0.291
HMGA2 expression						
Low expression		Reference				
High expression	2.815	1.528–5.186	<0.001	3.116	1.643–5.901	<0.001

Abbreviations: ccRCC, clear cell renal cell carcinoma; HR, hazard ratio; CI, confidence interval; MVI, microvascular invasion; HMGA2, high-mobility group AT-hook 2.

Expansion of prognostic models for ccRCC patients with the addition of HMGA2 expression

To further evaluate the value of HMGA2 expression in the improvement of the prognostic prediction for ccRCC, HMGA2 expression was integrated into existing prognostic models including the following scoring systems: TNM staging system, the Mayo Clinic stage, size, grade, and necrosis score, and the University of California Los Angeles Integrated Staging System (UISS). We conducted a Harrell concordance index (C-index) and an Akaike information criteria analysis to investigate the prognostic accuracy of each system. As shown in Table 3, the C-index of the TNM staging system, SSIGN, and UISS was 0.671, 0.726, and 0.711,

respectively; after the integration of HMGA2 expression into the aforementioned staging systems, the C-index was improved to 0.719, 0.736, and 0.723, respectively. This suggested that the addition of the HMGA2 expression parameter could improve the prognostic value of all the three models.

Discussion

Abnormal expression of HMGA2 has been found in many types of malignancies, including colon cancer, breast cancer, pancreatic cancer, ovarian cancer, esophageal cancer, and lung cancer.¹³ It seems that HMGA2 overexpression is associated with a highly malignant phenotype, which results in poor prognosis for patients with these cancers. In the present study, we examined the expression of HMGA2 in ccRCC and evaluated its prognostic value. We confirmed that the expression level of HMGA2 was significantly related to tumor size and Fuhrman grade. Moreover, HMGA2 expression was determined to be a valuable prognostic indicator in patients with ccRCC.

HMGA2, which is a member of the HMGA family, binds to DNA sequences to orchestrate transcriptional activity via the modulation of the chromatin structure. HMGA2 might target different downstream genes to maintain the undifferentiated state of cells during the processes of embryogenesis and tumorigenesis.¹⁴ Several studies on human cancers have indicated that HMGA2 is important in the survival, proliferation, migration, and metastasis of cancer cells.^{15–17} In addition,

Table 3 Evaluation the efficacy of prognostic models in predicting the overall survival

Variable	C-index
HMGA2	0.641
TNM stage	0.671
TNM + HMGA2	0.719
SSIGN	0.726
SSIGN + HMGA2	0.736
UISS	0.711
UISS + HMGA2	0.723

Abbreviations: C-index, concordance index; HMGA2, high-mobility group AT-hook 2; TNM, tumor node metastasis; SSIGN, Mayo Clinic stage, size, grade, and necrosis score; UISS, University of California Los Angeles Integrated Staging System.

HMGA2 seems to have oncogenic activities that include the enhancement of self-renewal capability in cancer stem cells and the promotion of tumorigenic capability.^{18–20} As an oncofetal protein, the expression of HMGA2 decreases with the differentiation of tissues, but increases with the dedifferentiation of many malignant tumors.^{21–23} In our present study, we also observed that an increased HMGA2 level was correlated with a higher Fuhrman grade, which suggested a potential role of HMGA2 in tumor dedifferentiation. Consistent with these findings, there were various studies that revealed a positive correlation between HMGA2 expression and tumor grade in a variety of tumor cell types.^{24–26} However, further exploration is needed to clarify the relationship between HMGA2 expression and dedifferentiation. Additionally, our finding that HMGA2 overexpression predicted poor prognosis suggested that HMGA2 overexpression is involved in ccRCC progression, which was consistent with results of previous studies of other types of human cancers.

In the present cohort, the high HMGA2 expression group was more likely to have higher rates of lymph node invasion and vascular invasion than those in the low expression group. Previous studies have reported a strong correlation between HMGA2 expression and tumor cell invasiveness.^{27–29} The ectopic expression of HMGA2 in epithelial cells induces epithelial-mesenchymal transition (EMT), which has been implicated in the acquisition of metastatic characteristics in tumor cells.³⁰ Notably, several studies have reported that HMGA2 plays an important role in EMT during diabetic nephropathy,^{31,32} indicating a potential role of HMGA2 in EMT of renal cancer cells. This may occur through activation of the Wnt/ β -catenin pathway,^{28–30,33} or through the regulation of the transcription factors involved in EMT including Snail, Slug, and Twist.^{30,31} Besides, HMGA2 can also induce EMT through an interaction via the TGF β signaling pathway that has been strongly implicated in EMT induction for a number of cell types both in vitro and in vivo.^{30,34,35} In this respect, HMGA2 plays an important role in tumor invasiveness and metastasis, which supports our findings that HMGA2 overexpression is associated with clinicopathological factors such as lymph node metastasis and MVI.

Although HMGA2 is gradually being recognized as a prognostic biomarker in many malignancies, the prognostic value of HMGA2 in ccRCC remains unclear. In the present study, we found that a high level of HMGA2 expression in ccRCC patients was significantly associated with a poor prognosis. The multivariate analysis showed that HMGA2 expression was an independent prognostic factor for survival. Furthermore, we determined that the addition of HMGA2

expression to existing prognostic prediction models, such as the TNM staging system, could improve their prediction power. Therefore, the detection of the HMGA2 level in ccRCC tissues after surgery might be helpful to further predict the prognosis of those patients. However, this study still has several limitations. The sample size of our cohort was not large enough, and the study was retrospective, which means that our study is not sufficient to achieve greater reliability. Finally, further research on the molecular biological mechanism of HMGA2 in ccRCC is warranted.

Conclusion

In conclusion, our study revealed that HMGA2 expression is an independent prognostic factor for OS in patients with ccRCC. The abnormal expression of HMGA2 may play a role in the carcinogenesis of ccRCC. These results provide a basis for further, more detailed studies on the roles of HMGA2 in ccRCC.

Acknowledgment

This study was supported by the Natural Science Foundation of China (81470977).

Disclosure

The authors report no conflicts of interest in this work.

References

1. Srigley JR, Delahunt B, Eble JN, et al. The International Society of Urological Pathology (ISUP) Vancouver Classification of Renal Neoplasia. *Am J Surg Pathol*. 2013;37(10):1469–1489.
2. Siegel RL, Miller KD, Jemal A. Cancer statistics, 2015. *CA Cancer J Clin*. 2015;65(1):5–29.
3. Battaglia M, Lucarelli G. The role of renal surgery in the era of targeted therapy: the urologist's perspective. *Urologia*. 2015;82(3):137–138.
4. Sun M, Shariat SF, Cheng C, et al. Prognostic factors and predictive models in renal cell carcinoma: a contemporary review. *Eur Urol*. 2011;60(4):644–661.
5. Kim HL, Halabi S, Li P, et al. A molecular model for predicting overall survival in patients with metastatic clear cell renal carcinoma: results from CALGB 90206 (alliance). *EBioMedicine*. 2015;2(11):1814–1820.
6. Chen F, Zhang Y, Şenbabaoğlu Y, et al. Multilevel Genomics-Based Taxonomy of Renal Cell Carcinoma. *Cell Rep*. 2016;14(10):2476–2489.
7. Wang J, Liu Y, Yang Y, et al. High expression of galectin-7 associates with poor overall survival in patients with non-metastatic clear-cell renal cell carcinoma. *Oncotarget*. Epub 2016 May 31.
8. Fu H, Liu Y, Xu L, et al. Low expression of mucin-4 predicts poor prognosis in patients with clear-cell renal cell carcinoma. *Medicine (Baltimore)*. 2016;95(17):e3225.
9. Johnson KR, Lehn DA, Reeves R. Alternative processing of mRNAs encoding mammalian chromosomal high-mobility-group proteins HMGI and HMGI-Y. *Mol Cell Biol*. 1989;9(5):2114–2123.
10. Ozturk N, Singh I, Mehta A, Braun T, Barreto G. HMGA proteins as modulators of chromatin structure during transcriptional activation. *Front Cell Dev Biol*. 2014;2:5.
11. Chiappetta G, Avantaggiato V, Visconti R, et al. High level expression of the HMGI (Y) gene during embryonic development. *Oncogene*. 1996;13(11):2439–2446.

12. Takaha N, Sowa Y, Takeuchi I, Hongo F, Kawauchi A, Miki T. Expression and role of HMGA1 in renal cell carcinoma. *J Urol*. 2012;187(6):2215–2222.
13. Pallante P, Sepe R, Puca F, Fusco A. High mobility group a proteins as tumor markers. *Front Med (Lausanne)*. 2015;2:15.
14. Yu KR, Shin JH, Kim JJ, et al. Rapid and efficient direct conversion of human adult somatic cells into neural stem cells by HMGA2/let-7b. *Cell Rep*. Epub 2015 Jan 15.
15. Shi Z, Wu D, Tang R, et al. Silencing of HMGA2 promotes apoptosis and inhibits migration and invasion of prostate cancer cells. *J Biosci*. 2016;41(2):229–236.
16. Sun M, Song CX, Huang H, et al. HMGA2/TET1/HOXA9 signaling pathway regulates breast cancer growth and metastasis. *Proc Natl Acad Sci U S A*. 2013;110(24):9920–9925.
17. Natarajan S, Hombach-Klonisch S, Droge P, Klonisch T. HMGA2 inhibits apoptosis through interaction with ATR-CHK1 signaling complex in human cancer cells. *Neoplasia*. 2013;15(3):263–280.
18. Kaur H, Ali SZ, Huey L, et al. The transcriptional modulator HMGA2 promotes stemness and tumorigenicity in glioblastoma. *Cancer Lett*. 2016;377(1):55–64.
19. Ikeda K, Ogawa K, Takeishi Y. The role of HMGA2 in the proliferation and expansion of a hematopoietic cell in myeloproliferative neoplasms. *Fukushima J Med Sci*. 2012;58(2):91–100.
20. Madison BB, Jeganathan AN, Mizuno R, et al. Let-7 represses carcinogenesis and a stem cell phenotype in the intestine via regulation of Hmga2. *PLoS Genet*. 2015;11(8):e1005408.
21. Piscuoglio S, Zlobec I, Pallante P, et al. HMGA1 and HMGA2 protein expression correlates with advanced tumour grade and lymph node metastasis in pancreatic adenocarcinoma. *Histopathology*. 2012;60(3):397–404.
22. Mu G, Liu H, Zhou F, et al. Correlation of overexpression of HMGA1 and HMGA2 with poor tumor differentiation, invasion, and proliferation associated with let-7 down-regulation in retinoblastomas. *Hum Pathol*. 2010;41(4):493–502.
23. Parameswaran S, Xia X, Hegde G, Ahmad I. Hmga2 regulates self-renewal of retinal progenitors. *Development*. 2014;141(21):4087–4097.
24. Rogalla P, Drechsler K, Kazmierczak B, Rippe V, Bonk U, Bullerdiek J. Expression of HMGI-C, a member of the high mobility group protein family, in a subset of breast cancers: relationship to histologic grade. *Mol Carcinog*. 1997;19(3):153–156.
25. Wang X, Liu X, Li AY, et al. Overexpression of HMGA2 promotes metastasis and impacts survival of colorectal cancers. *Clin Cancer Res*. 2011;17(8):2570–2580.
26. Miyazawa J, Mitoro A, Kawashiri S, Chada KK, Imai K. Expression of mesenchyme-specific gene HMGA2 in squamous cell carcinomas of the oral cavity. *Cancer Res*. 2004;64(6):2024–2029.
27. Wu J, Wang Y, Xu X, et al. Transcriptional activation of FN1 and IL11 by HMGA2 promotes the malignant behavior of colorectal cancer. *Carcinogenesis*. 2016;37(5):511–521.
28. Yang E, Cisowski J, Nguyen N, et al. Dysregulated protease activated receptor 1 (PAR1) promotes metastatic phenotype in breast cancer through HMGA2. *Oncogene*. 2016;35(12):1529–1540.
29. Xia YY, Yin L, Jiang N, et al. Downregulating HMGA2 attenuates epithelial-mesenchymal transition-induced invasion and migration in nasopharyngeal cancer cells. *Biochem Biophys Res Commun*. 2015;463(3):357–363.
30. Morishita A, Zaidi MR, Mitoro A, et al. HMGA2 is a driver of tumor metastasis. *Cancer Res*. 2013;73(14):4289–4299.
31. Bai YH, Wang JP, Yang M, Zeng Y, Jiang HY. siRNA-HMGA2 weakened AGES-induced epithelial-to-mesenchymal transition in tubular epithelial cells. *Biochem Biophys Res Commun*. 2015;457(4):730–735.
32. Liu H, Wang X, Liu S, et al. Effects and mechanism of miR-23b on glucose-mediated epithelial-to-mesenchymal transition in diabetic nephropathy. *Int J Biochem Cell Biol*. 2016;70:149–160.
33. Zha L, Zhang J, Tang W, et al. HMGA2 elicits EMT by activating the Wnt/beta-catenin pathway in gastric cancer. *Dig Dis Sci*. 2013;58(3):724–733.
34. Lee AW, Ma BB, Ng WT, Chan AT. Management of Nasopharyngeal Carcinoma: Current Practice and Future Perspective. *J Clin Oncol*. 2015;33(29):3356–3364.
35. Chua ML, Wee JT, Hui EP, Chan AT. Nasopharyngeal carcinoma. *Lancet*. 2016;387(10022):1012–1024.

OncoTargets and Therapy

Publish your work in this journal

OncoTargets and Therapy is an international, peer-reviewed, open access journal focusing on the pathological basis of all cancers, potential targets for therapy and treatment protocols employed to improve the management of cancer patients. The journal also focuses on the impact of management programs and new therapeutic agents and protocols on

Submit your manuscript here: <http://www.dovepress.com/oncotargets-and-therapy-journal>

patient perspectives such as quality of life, adherence and satisfaction. The manuscript management system is completely online and includes a very quick and fair peer-review system, which is all easy to use. Visit <http://www.dovepress.com/testimonials.php> to read real quotes from published authors.

Dovepress