

High bone turnover status as a risk factor in symptomatic hypocalcemia following denosumab treatment in a male patient with osteoporosis

Koji Ishikawa¹⁻³
Takashi Nagai¹
Koki Tsuchiya¹
Yusuke Oshita³
Takuma Kuroda¹
Hiroshi Ito¹
Soji Tani¹
Yusuke Dodo¹
Tomoaki Toyone¹
Katsunori Inagaki¹

¹Department of Orthopaedic Surgery, Showa University School of Medicine, Tokyo, Japan; ²Department of Orthopaedic and Spine Surgery, Sanraku Hospital, Tokyo, Japan; ³Department of Orthopaedic Surgery, Yamanashi Red Cross Hospital, Yamanashi, Japan

Correspondence: Koji Ishikawa
Department of Orthopaedic Surgery,
Showa University School of Medicine,
1-5-8 Hatanodai, Shinagawa-ku,
Tokyo 142-8666, Japan
Tel +81 3 3784 8543
Fax +81 3 3784 9005
Email koji.ishikawa@med.showa-u.ac.jp

Abstract: Denosumab is a fully human monoclonal antibody against the receptor activator of nuclear factor- κ B ligand (RANKL) that is used for the treatment of osteoporosis. Denosumab-induced hypocalcemia is a rare but important adverse event, which is usually asymptomatic in patients with osteoporosis. It is also known that hypocalcemia is common in patients with bone metastases and severe renal impairment. Here we report a case of symptomatic hypocalcemia following administration of 60 mg of denosumab in a patient with high bone turnover and no renal impairment (estimated glomerular filtration rate [eGFR], 71 mL/min), despite prophylactic oral vitamin D administration. This report supports our observation that there is a risk of protracted and marked denosumab-induced hypocalcemia in patients with high bone turnover, irrespective of their degree of renal impairment.

Keywords: denosumab, symptomatic hypocalcemia, high bone turnover, no renal impairment

Introduction

Osteoporosis is recognized as one of the most common public health problems, especially in the elderly population.¹ There are many medications available to manage osteoporosis. Denosumab is a novel agent that is approved for the treatment of osteoporosis and for the prevention of skeletal-related events in patients with bone metastases. In men and postmenopausal women with osteoporosis, a single 60 mg dose of denosumab administered subcutaneously every 6 months significantly reduces bone turnover markers, increases bone mineral density (BMD), and reduces the risk of new fractures.² Denosumab is not associated with delayed healing or other complications following fractures.^{3,4} However, it is associated with several serious adverse effects, including hypocalcemia.⁵⁻¹² Hypocalcemia is a rare adverse event associated with denosumab and may present with serious manifestations, including cardiac arrhythmia and death.¹¹⁻¹⁴ In general, most incidents of hypocalcemia are asymptomatic, especially in patients with osteoporosis.^{15,16} Hypocalcemia is most common with the use of denosumab for the prevention of skeletal-related events in patients with bone metastases.¹⁷ The generally recognized risk factors for hypocalcemia are renal impairment and lack of prophylactic administration of calcium and activated vitamin D. We recently reported that high bone turnover was also associated with a higher risk of denosumab-induced hypocalcemia in patients with postmenopausal osteoporosis.¹⁶ However, all cases of hypocalcemia in that series were asymptomatic. Here, we present the case of a male patient with symptomatic hypocalcemia and high bone turnover status induced by a single, 60 mg dose of denosumab, even though

he was receiving prophylactic vitamin D and had normal renal function.

Case presentation

A 68-year-old man presented to our hospital with a 1-week duration of back pain that appeared after he lifted a heavy object while cleaning his house. He underwent an apparently curative laparoscopic distal gastrectomy for gastric cancer 2 years ago. There was no evidence of residual cancer following his operation, and he did not receive any adjuvant treatment in the past year. He was not on any medications for other diseases, including osteoporosis. Plain lateral radiographs of the spine and MRI demonstrated a fresh vertebral fracture at L3 and T12 (Figure 1). Bone metastases were not identified through medical examination. He was treated conservatively, using a rigid brace to stabilize his spine. He also received a single, 60 mg dose of denosumab subcutaneously, and was started on a prophylactic dose of oral eldecalcitol ($0.75 \mu\text{g}/\text{d}$) for osteoporosis (DXA [Dual energy X-ray absorptiometry]: spine BMD, $0.594 \text{ mg}/\text{cm}^2$; femoral neck BMD, $0.445 \text{ mg}/\text{cm}^2$). Prior to the administration of denosumab, the results of his laboratory investigations were as follows: serum corrected calcium, $8.8 \text{ mg}/\text{dL}$ (reference range [RR], $8.7\text{--}10.2 \text{ mg}/\text{dL}$); phosphorus, $3.4 \text{ mg}/\text{dL}$ (RR, $2.5\text{--}4.5 \text{ mg}/\text{dL}$); magnesium, $2.1 \text{ mg}/\text{dL}$ (RR, $1.7\text{--}2.6 \text{ mg}/\text{dL}$), alkaline phosphatase,

$308 \text{ U}/\text{L}$ (RR, $104\text{--}338 \text{ U}/\text{L}$); serum creatinine, $0.83 \text{ mg}/\text{dL}$ (RR, $0.65\text{--}1.09 \text{ mg}/\text{dL}$), estimated glomerular filtration rate (eGFR), $71 \text{ mL}/\text{min}$ (RR, $\geq 60 \text{ mL}/\text{min}$), eGFR level was calculated using the formula developed by the Japanese Society of Nephrology,¹⁸ and $1,25\text{-dihydroxyvitamin D}$ ($1,25[\text{OH}]_2\text{D}$), $43 \text{ pg}/\text{mL}$ (RR, $20\text{--}60 \text{ pg}/\text{mL}$). Further, he was found to have secondary hyperparathyroidism (intact parathyroid hormone [intact PTH], $148 \text{ pg}/\text{mL}$ [RR, $10\text{--}65 \text{ pg}/\text{mL}$]; vitamin D deficiency ($1,25[\text{OH}]_2\text{D}$), $6.6 \text{ ng}/\text{mL}$ [RR, $20\text{--}100 \text{ ng}/\text{mL}$]) and high bone turnover status (total N-terminal propeptide of type 1 procollagen [total P1NP], $94.9 \mu\text{g}/\text{L}$ [RR, $18.1\text{--}74.1 \mu\text{g}/\text{L}$]; tartrate-resistant acid phosphatase type 5 [TRACP-5b], $900 \text{ mU}/\text{dL}$ [RR, $170\text{--}590 \text{ mU}/\text{dL}$]). The patient was due for the next blood test after 14 days.

The patient developed nausea, vomiting, decreased appetite, and paresthesia in the extremities and around the mouth 14 days following denosumab administration. Blood tests identified grade 3 hypocalcemia (corrected calcium, $6.9 \text{ mg}/\text{dL}$) according to the National Cancer Institute's Common Toxicity Criteria for Adverse Events version 4.0. He was found to have phosphate serum levels of $2.9 \text{ mg}/\text{dL}$ and intact PTH of $744 \text{ pg}/\text{mL}$. Electrocardiogram demonstrated normal sinus rhythm without QT prolongation. After a discussion of the risks and benefits, the patient consented to careful calcium homeostasis management as an outpatient. He was supplemented with $3,000 \text{ mg}/\text{dL}$ of oral calcium along with a prophylactic dose ($0.75 \mu\text{g}/\text{dL}$) of oral eldecalcitol, which resolved his symptoms. His serum calcium normalized (corrected calcium, $8.7 \text{ mg}/\text{dL}$) 21 days post denosumab. Subsequently, he was managed on an outpatient basis with close monitoring of calcium homeostasis and bone turnover markers. The patient received three more courses of denosumab, during which he maintained his calcium levels with oral calcium ($3,000\text{--}4,000 \text{ mg}/\text{dL}$) and vitamin D supplementation (Figure 2). During denosumab treatment, there was an immediate reduction in bone turnover markers (Figure 3) and a successful increase in the BMD (DXA: spine BMD, from 0.594 to $0.893 \text{ mg}/\text{cm}^2$; femoral neck BMD, from 0.445 to $0.456 \text{ mg}/\text{cm}^2$). There was a mild deterioration in renal function during the course of his treatment (Figure 3). $1,25(\text{OH})_2\text{D}$ was suppressed, while $25(\text{OH})\text{D}$ increased in summer and autumn and decreased in winter (Figure 4).

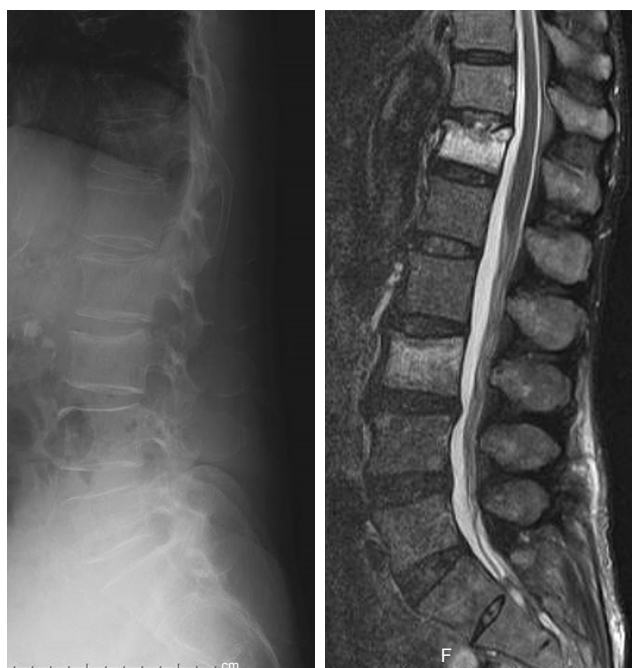

Figure 1 Plain lateral radiographs and MRI demonstrated a fresh vertebral fracture at L3 and T12.

Abbreviations: L, lumbar; T, thoracic.

Consent

Written informed consent was obtained from the patient for the publication of this case report.

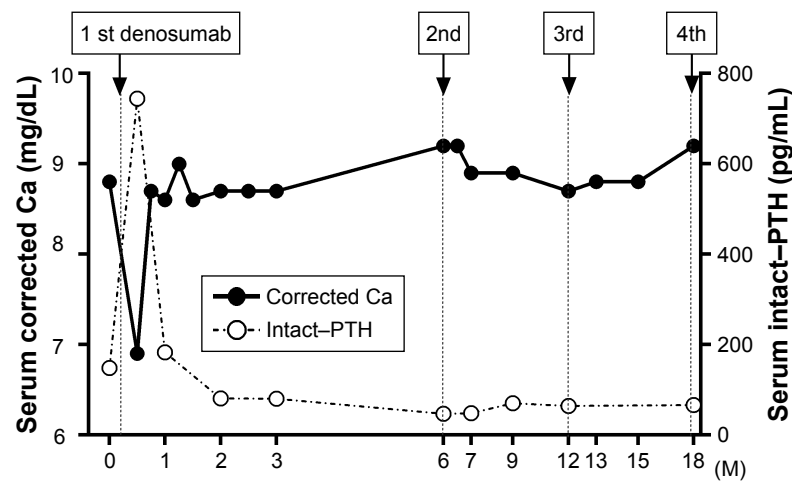


Figure 2 Serum calcium and intact PTH levels.

Notes: After the serum calcium was normalized, it did not change significantly over the three courses of denosumab. PTH continued to be elevated 2 weeks following denosumab administration. Subsequently, PTH was normalized owing to calcium supplementation.

Abbreviations: M, month; Ca, calcium; PTH, parathyroid hormone.

Discussion

In a major clinical trial, there were no reports of hypocalcemia (serum calcium <8.0 mg/dL) among 3,886 women who received denosumab over a 3-year follow-up.¹ However, previous case reports suggested a variable incidence of denosumab-induced symptomatic hypocalcemia in patients with osteoporosis,^{5–12} the majority of whom had renal failure. Consequently, current recommendations suggest monitoring calcium levels in patients with reduced renal function. Our patient developed symptomatic hypocalcemia following

denosumab administration, in the absence of any renal impairment. Although they do not provide the cause of the hypocalcemia, recent case reports suggest that calcium level monitoring may be necessary for any degree of renal failure.¹² These levels may be monitored 1–2 weeks following the administration of denosumab, to correspond to the nadir of its action.¹⁵ In the current case report, it is possible that life-threatening hypocalcemia was mitigated by its early detection on routine monitoring and timely extra oral calcium supplementation.

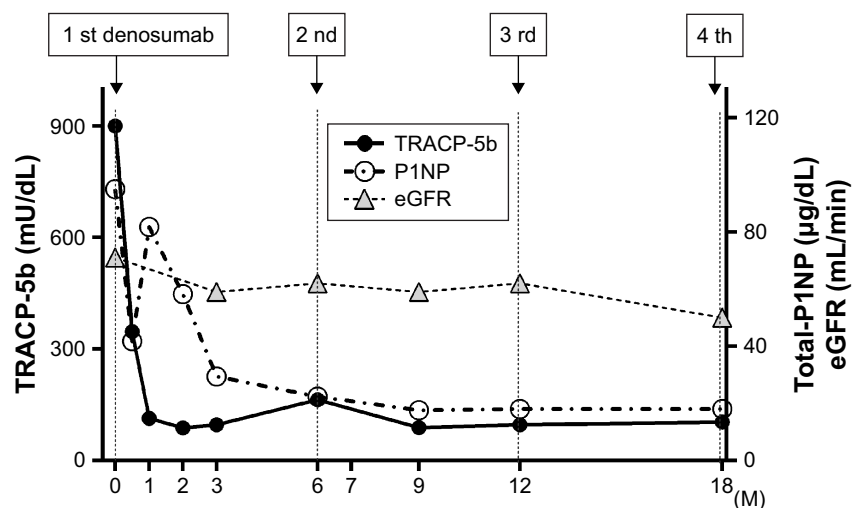


Figure 3 Bone turnover markers (TRACP-5b, total-P1NP) and eGFR levels.

Notes: TRACP-5b and total-P1NP levels decreased immediately following the first course of denosumab treatment. Renal function diminished mildly over the entire course of treatment.

Abbreviations: M, month; TRACP-5b, tartrate-resistant acid phosphatase type 5; total-P1NP, total N-terminal propeptide of type I procollagen; eGFR, estimated glomerular filtration rate.

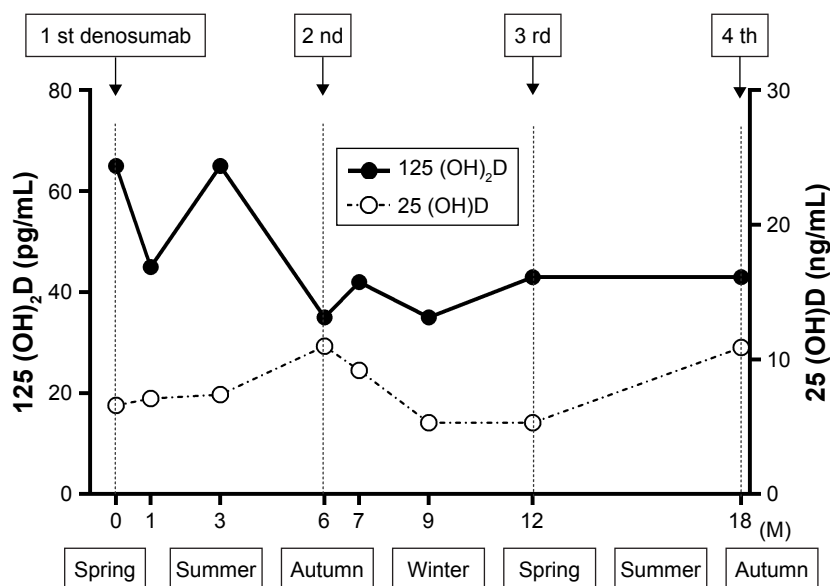


Figure 4 1,25(OH)₂D and 25(OH)D levels.

Notes: 1,25(OH)₂D was suppressed following elcalcitol supplementation. 25(OH)D level is higher in summer and autumn and lower in winter.

Abbreviations: M, month; 1,25(OH)₂D, 1,25-dihydroxyvitamin D; 25(OH)D, 25-hydroxyvitamin.

In general, the risk factors for hypocalcemia include renal impairment, vitamin D deficiency, and lack of prophylactic supplementation.^{12,15} However, increasing attention has been paid to high bone turnover as a risk factor for denosumab-induced hypocalcemia.^{11,16,19} Among these risk factors, our patient had high bone turnover and vitamin D deficiency in the present case. Symptomatic hypocalcemia occurred only once, at 2 weeks following the initial administration, throughout the three courses of denosumab. Interestingly, levels of 25(OH)D remained relatively unaltered during the treatment, and renal function appeared to gradually deteriorate. One factor that changed dramatically was bone turnover (total P1NP: from 94.9 to 41.8 µg/L [from baseline to 2 weeks], TRACP-5b: from 900 to 347 mU/dL), and that change was most significant following the first course of denosumab at almost exactly the same time as the patient exhibited symptomatic hypocalcemia. Therefore, it is our opinion that high bone turnover may be the principal predisposing factor for symptomatic hypocalcemia in our patient, and not vitamin D deficiency. We have previously demonstrated that denosumab administration has a greater impact on serum calcium levels in patients with high bone turnover as maintaining normocalcemia in this group is more dependent on bone resorption.¹⁶ Following our article, one recent study investigated calcium levels after administration of denosumab after switching from the naïve, bisphosphonate, selective estrogen receptor modular or teriparatide therapies.¹⁹ The authors concluded that serum calcium levels of patients

switching from teriparatide therapies to denosumab showed a significant decrease compared with the other groups, meaning that high bone turnover is potentially a risk factor in denosumab-induced hypocalcemia. In particular, they also found that there were no significant correlations between serum 25(OH)D level at baseline and changes in serum calcium level.

The majority of patients in a number of studies, including the patient in the present case, developed hypocalcemia after the first dose of denosumab.^{5,7–12,19} In fact, there were no differences in serum calcium level from the second dose of denosumab to 1 week later.¹⁹ This may be explained by low bone turnover in the majority of patients after the first course of denosumab. Therefore, the risk of hypocalcemia is reduced after the second and subsequent doses of denosumab, as seen in the present case.

The high baseline PTH in the presence of normocalcemia suggests that serum calcium is maintained by the PTH-mediated mobilization of calcium from skeletal stores and by stimulation of bone resorption. It is generally agreed that secondary hyperparathyroidism is associated with a high bone turnover status, implying that patients with secondary hyperparathyroidism are at an increased risk for denosumab-induced hypocalcemia. Elevated PTH following denosumab administration contributes to serum calcium maintenance, and the lack of this elevation may result in inadequate mobilization of bone calcium, and therefore severe hypocalcemia. To the best of our knowledge, this is the first report to measure the PTH levels over the treatment period and

showed a transient acute increase in PTH levels following denosumab administration with a concomitant decrease in serum calcium levels.

Moreover, it is important for vitamin D deficiency to be corrected, if possible, prior to denosumab administration. 1,25(OH)₂D stimulates calcium absorption in the intestines and bone mineralization, and its deficiency has a strong bearing on serum calcium levels. In our case, 1,25(OH)₂D was suppressed by about 33.8% throughout the treatment course with eldecacitol, which is consistent with the observation of a previous study that investigated the time course of change after eldecacitol supplementation.²⁰ 25(OH)D was not altered significantly, and the observed changes corresponded to the expected seasonal variations in its concentration, as its levels are primarily dependent on climate and sun exposure.²¹

Our patient had a history of laparoscopic distal gastrectomy. A previous study reported that gastrectomy did not increase the risk of developing denosumab-induced hypocalcemia in patients with gastric cancer and bone metastases.²² However, gastrectomy is a known risk factor for osteoporosis.²³ After gastrectomy, reduced gastric acid secretion impairs calcium ionization and, in the setting of calcium and vitamin D deficiency, may also cause hypocalcemia.

We are unable to fully explain the pathophysiology of hypocalcemia in our case. However, since the only instance in which hypocalcemia occurred following the first course of denosumab, we hypothesized that it was precipitated by the disruption of the high bone turnover state by denosumab. Furthermore, our case showed that elevated PTH levels following denosumab administration may play an important role in the normalization of calcium levels. Thus, on the basis of our experience, including the previous study, we recommend that a thorough evaluation, including bone turnover markers, renal function, PTH and 25(OH)D levels, is essential in patients slated for denosumab therapy.¹⁶ Moreover, close monitoring of serum calcium following the first course of denosumab is necessary in patients with high bone turnover, irrespective of their degree of renal failure.

Our case report has some limitations. First, our patient presented to our hospital 1 week after he sustained a vertebral fracture, which may have increased the levels of the bone turnover marker. However, since bone turnover markers usually peak several weeks following most fractures,²⁴ this is a remote possibility. Second, although our hypothesis is based on the previous article,^{11,16,19} we experienced symptomatic hypocalcemia in only one case.

In conclusion, this is the first case report of denosumab-induced symptomatic hypocalcemia in a patient with

osteoporosis and absence of renal impairment that clearly documents the role of high bone turnover state as a risk factor. Appropriate preassessment of bone and calcium homeostasis, including bone turnover status, may help in identifying patients at a higher risk for denosumab-induced hypocalcemia. With proactive and careful monitoring, denosumab-induced hypocalcemia can be prevented and managed effectively in patients with osteoporosis. Clinicians should at least consider the possibility of a higher risk of denosumab-induced hypocalcemia in the presence of high bone turnover and identify potentially high-risk patients for early intervention.

Acknowledgment

The authors thank Ayano Oyamada, Tatsuyo Shinohara, Mayumi Otsu, Rikako Ono, Yoko Matsumoto, Takeshi Eguro, Keizo Sakamoto, Shigeo Sano, and Yusuke Nakao for their cooperation with osteoporosis treatment and technical assistance.

Disclosure

The authors report no conflicts of interest in this work.

References

1. McCurry J. Japan will be model for future super-ageing societies. *Lancet*. 2015;386(10003):1523.
2. Cummings SR, San Martin J, et al; FREEDOM Trial. Denosumab for prevention of fractures in postmenopausal women with osteoporosis. *N Engl J Med*. 2009;361(8):756–765.
3. Goldhahn J, Féron JM, Kanis J, et al. Implications for fracture healing of current and new osteoporosis treatments: an ESCEO consensus paper. *Calcif Tissue Int*. 2012;90(5):343–353.
4. Adami S, Libanati C, Boonen S, et al. Denosumab Treatment in Postmenopausal. *J Bone Jt Surgery Incorporated*. 2012;94-A(23):1–7.
5. Smyth B, Ong S. Severe hypocalcaemia and hypophosphataemia following intravenous iron and denosumab: a novel drug interaction. *Intern Med J*. 2016;46(3):360–363.
6. Oiwa H, Mokuda S. Severe hypocalcemia and prolonged QT interval due to denosumab in an elderly woman with rheumatoid arthritis and chronic kidney disease. [letter to the editor] . *Eur J Rheumatol*. 2016; 3(3):144–145.
7. Shafqat H, Alquadan KF, Olszewski AJ. Severe hypocalcemia after denosumab in a patient with acquired Fanconi syndrome. *Osteoporosis International*. 2014;25(3):1187–1190.
8. Chandurkar V, Marliss EB. Multiple Factors in Recurrent Symptomatic Hypocalcemia Following Denosumab in a Patient Receiving Home Parenteral Nutrition. *Journal of Parenteral and Enteral Nutrition*. 2016;40(5): 734–738.
9. Talreja DB. Severe hypocalcemia following a single injection of denosumab in a patient with renal impairment. *J Drug Assess*. 2012;1(1): 30–33.
10. Dave V, Chiang CY, Booth J, Mount PF. Hypocalcemia post denosumab in patients with chronic kidney disease stage 4–5. *Am J Nephrol*. 2015;41(2):129–137.
11. Farinola N, Kanjanapan Y, Hospital RA, Farinola N, Hospital RA. Denosumab-induced hypocalcaemia in high bone turnover states of malignancy and secondary hyperparathyroidism from renal failure. *Intern Med J*. 2013;43(11):1243–1246.

12. Blackley S, Anderson K, Berg J. A case of denosumab-induced hypocalcaemia in a patient with non-metastatic prostate cancer and renal impairment. *J R Coll Physicians Edinb*. 2015;45(2):133–135.
13. Ungprasert P, Cheungpasitporn W, Srivali N, Kittanamongkolchai W, Bischof EF. Life-threatening hypocalcemia associated with denosumab in a patient with moderate renal insufficiency. *Am J Emerg Med*. 2013;31(4):756–756.
14. Laskowski LK, Goldfarb DS, Howland MA, Kavesak K, Lugassy DM, Smith SW. A RANKL Wrinkle: Denosumab-Induced Hypocalcemia. *J Med Toxicol*. 2016:3–6.
15. Block GA, Bone HG, Fang L, Lee E, Padhi D. A single-dose study of denosumab in patients with various degrees of renal impairment. *J Bone Miner Res*. 2012;27(7):1471–1479.
16. Ishikawa K, Nagai T, Sakamoto K, et al. High bone turnover elevates the risk of denosumab-induced hypocalcemia in women with postmenopausal osteoporosis. *Ther Clin Risk Manag*. 2016;12:1831–1840.
17. Qi WX, Lin F, He AN, Tang LN, Shen Z, Yao Y. Incidence and risk of denosumab-related hypocalcemia in cancer patients: a systematic review and pooled analysis of randomized controlled studies. *Curr Med Res Opin*. 2013;29(9):1067–1073.
18. Matsuo S, Imai E, Horio M, et al. Collaborators developing the Japanese equation for estimated GFR. Revised equations for estimated GFR from serum creatinine in Japan. *Am J Kidney Dis*. 2009;53(6):982–992.
19. Asano T, Shimizu T, Takahashi D, et al. Potential association with early changes in serum calcium level after starting or switching to denosumab combined with eldecacitol. *J Bone Miner Metab*. Epub 2018 May 02.
20. Matsumoto T, Takano T, Yamakido S, Takahashi F, Tsuji N. Journal of Steroid Biochemistry and Molecular Biology Comparison of the effects of eldecacitol and alfacalcidol on bone and calcium. *J Steroid Biochem Mol Biol*. 2010;121(1–2):261–264.
21. Bolland MJ, Grey AB, Ames RW, et al. The effects of seasonal variation of 25-hydroxyvitamin D and fat mass on a diagnosis of vitamin D sufficiency. *Am J Clin Nutr*. 2007;86(4):959–964.
22. Kinoshita Y, Arai M, Ito N, et al. High serum ALP level is associated with increased risk of denosumab-related hypocalcemia in patients with bone metastases from solid tumors. *Endocr J*. 2016;63(5):479–484.
23. Bisballe S, Eriksen EF, Melsen F, Mosekilde L, Sørensen OH, Hesse I. Osteopenia and osteomalacia after gastrectomy: interrelations between biochemical markers of bone remodelling, vitamin D metabolites, and bone histomorphometry. *Gut*. 1991;32(11):1303–1307.
24. Nakamura Y, Kamimura M, Ikegami S. Changes in Bone Turnover Markers and Fracture in Osteoporosis: A Review of the Literature. *Ann Orthop Rheumatol*. 2014;2:2–5.

Clinical Interventions in Aging

Publish your work in this journal

Clinical Interventions in Aging is an international, peer-reviewed journal focusing on evidence-based reports on the value or lack thereof of treatments intended to prevent or delay the onset of maladaptive correlates of aging in human beings. This journal is indexed on PubMed Central, MedLine,

CAS, Scopus and the Elsevier Bibliographic databases. The manuscript management system is completely online and includes a very quick and fair peer-review system, which is all easy to use. Visit <http://www.dovepress.com/testimonials.php> to read real quotes from published authors.

Submit your manuscript here: <http://www.dovepress.com/clinical-interventions-in-aging-journal>

Dovepress