

Acute Myeloid Leukemia with *NUP98-RARG* Gene Fusion Similar to Acute Promyelocytic Leukemia: Case Report and Literature Review

This article was published in the following Dove Press journal:
OncoTargets and Therapy

Shandong Tao^{1,2,*}

Lixiao Song^{1,2,*}

Yuan Deng^{1,2}

Yue Chen^{1,2}

Yuye Shi^{1,2}

Yimin Gan^{1,2}

Zhikui Deng^{1,2}

Banghe Ding^{1,2}

Zhengmei He^{1,2}

Chunling Wang^{1,2}

Liang Yu^{1,2}

¹Department of Hematology, The Affiliated Huai'an No.1 People's Hospital of Nanjing Medical University, Huai'an, Jiangsu 223300, People's Republic of China; ²Key Laboratory of Hematology of Nanjing Medical University, Nanjing 210029, People's Republic of China

*These authors contributed equally to this work

Abstract: Retinoic acid receptor gamma (RARG) belongs to the nuclear receptor superfamily and has 90% homology to RAR alpha (RARA) and RAR beta. The *promyelocytic leukemia (PML)–RAR* fusion gene has been implicated in acute promyelocytic leukemia (APL). *RARG* gene rearrangement has been identified in a rare subtype of acute myeloid leukemia (AML) that resembles APL. To date, only 10 cases of gene rearrangements involving *RARG* (*nucleoporin [NUP]98–RARG*, *promyelocytic leukemia protein–RARG*, *cleavage and polyadenylation-specific factor 6–RARG*, or *nucleophosmin [NPM]1–RARG–NPM1*) have been reported. These patients show characteristics similar to APL, including bone marrow morphology, coagulation abnormality, and immunophenotype; however, they are resistant to all-trans retinoic acid and arsenic trioxide treatment. Moreover, there is no optimal therapeutic regimen for this subtype of AML. In this study, we report the clinical presentation and experimental findings of a case of AML with *NUP98–RARG* gene fusion similar to APL and review other cases of *RARG* gene rearrangement described in the literature.

Keywords: acute myeloid leukemia, acute promyelocytic leukemia, NUP98-RARG, RARG rearrangement

Introduction

Acute myeloid leukemia (AML) is a highly heterogeneous and malignant clonal disease of hemopoietic stem cells characterized by uncontrolled proliferation and blocked differentiation of myeloid lineage blasts.¹ Acute promyelocytic leukemia (APL) is a specific type of AML, accounting for 5–15% of total AML cases.² The fusion gene *promyelocytic leukemia protein (PML)–retinoic acid receptor alpha (RARA)*, which is generated by the chromosomal translocation t(15;17)(q22;q21), is implicated in the pathogenesis of APL. All-trans retinoic acid (ATRA) and arsenic trioxide (ATO) have been shown to induce myeloid blast differentiation in APL;³ and it is recommended that patients with APL who have relapsed after ATRA plus chemotherapy be treated with a combined ATRA plus ATO-based regimen.⁴

RAR gamma (RARG) plays a key role in maintaining the self-renewal and differentiation of hematopoietic stem cells. *RARG* gene rearrangements have been detected in AML as a rare specific subtype with a clinical presentation resembling that of APL;⁵ however, these patients do not respond to treatment with ATRA and ATO. As such, the role of *RARG* in AML remains unclear.

Correspondence: Liang Yu; Chunling Wang
1 Huang River Road West, Huai'an, Jiangsu 223300, People's Republic of China
Tel/Fax +86-517 8087 2603
Email yuliangha@163.com; wcl6506@163.com

The first AML patient with a *nucleoporin (NUP)98–RARG* gene rearrangement was identified in 2011.⁶ Since then, 9 additional cases of *RARG* rearrangement have been reported, including 2 with *NUP98–RARG* fusions.^{7–13} Here we describe a case of *NUP98–RARG* gene fusion in an AML patient with the classic morphologic features and immunophenotype of APL.

Materials and Methods

Case Presentation

This study was approved by the institutional review board of The Affiliated Huai'an No.1 People's Hospital of Nanjing Medical University. On April 27, 2018, a 47-year-old female patient was admitted to our hospital presenting with skin ecchymosis and vaginal bleeding. The peripheral blood count revealed a white blood cell (WBC) count of $7.91 \times 10^9/\text{l}$, hemoglobin (Hg) level of 84 g/l, and platelet count of $14 \times 10^9/\text{l}$. Prothrombin time was 16.9 s (ref. 9.0–13.0 s), activated partial thromboplastin time was 40.7 s (ref. 20.0–40.0 s), fibrinogen level was 1.66 g/l (ref. 2.00–4.00 g/l), and D-dimer level was 20 $\mu\text{g/mL}$ (ref. 0–0.50 $\mu\text{g/mL}$). A bone marrow (BM) smear showed

hypercellularity, with 96.5% abnormal promyelocytic granulocytes. Auer bodies were observed in some cells. The smear was strongly positive for peroxidase staining (Figure 1A–C). An immunophenotype analysis showed positivity for myeloperoxidase, cluster of differentiation (CD)13, CD33, human leukocyte antigen-DR, and CD56 (Figure 2). The results of second-generation gene sequencing and reverse transcription-polymerase chain reaction (RT-PCR) were indeterminate. The initial diagnosis was APL. The patient was treated with ATRA (20 mg twice a day) and ATO (10 mg per day). After 14 days of treatment, the patient experienced chest tightness, dyspnea, systemic edema, and pleural effusion, consistent with differentiation syndrome. A chest computed tomography scan and color Doppler ultrasound were performed (Figure 3). WBC count did not increase with treatment and the coagulation abnormality did not show significant improvement: WBC count was $9.4 \times 10^9/\text{l}$, Hg level was 59 g/l, and platelet count was $38 \times 10^9/\text{l}$. Prothrombin time was 18.3 s, fibrinogen level was 0.91 g/l, and D-dimer level was 20 $\mu\text{g/mL}$. The karyotype was 45, X, –X, del(9)(q13q22), t(11;12)(p15;q13) in 20/20 analyzed metaphases

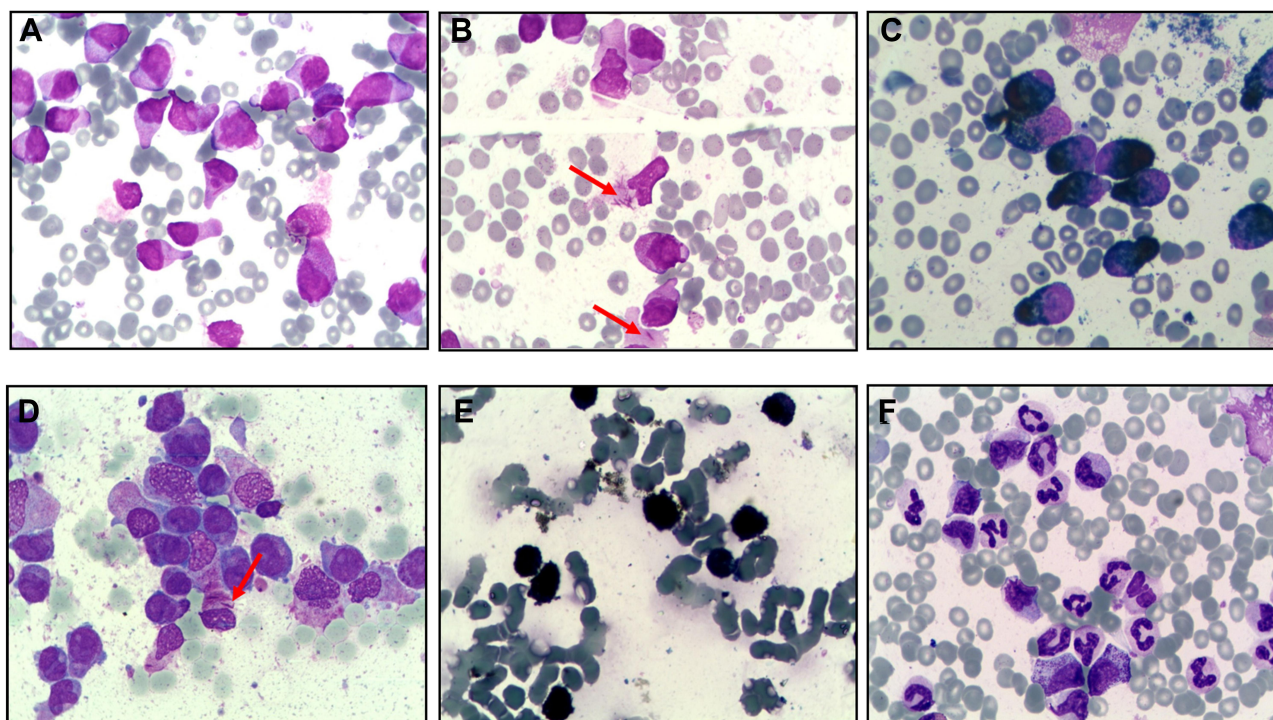


Figure 1 Morphologic features of an AML patient with *NUP98–RARG* gene fusion. (A, B, D) Promyelocytes with hypergranulated cytoplasm, invaginated nuclei, and Auer rods are indicated with red arrows (Wright-Giemsa stained BM smear, 1000 \times magnification). (C, E) BM smear strongly positive for peroxidase staining. Morphologic features were observed at the newly diagnosed stage (A–C) and 20 days after treatment with ATRA and ATO (D, E). The BM smear showed 95.5% abnormal promyelocytic granulocytes, with an occasional Auer body in the form of an Auer bundle; the peroxidase staining positive rate was 100%, indicating that there was no remission. (F) BM smear revealing complete remission.

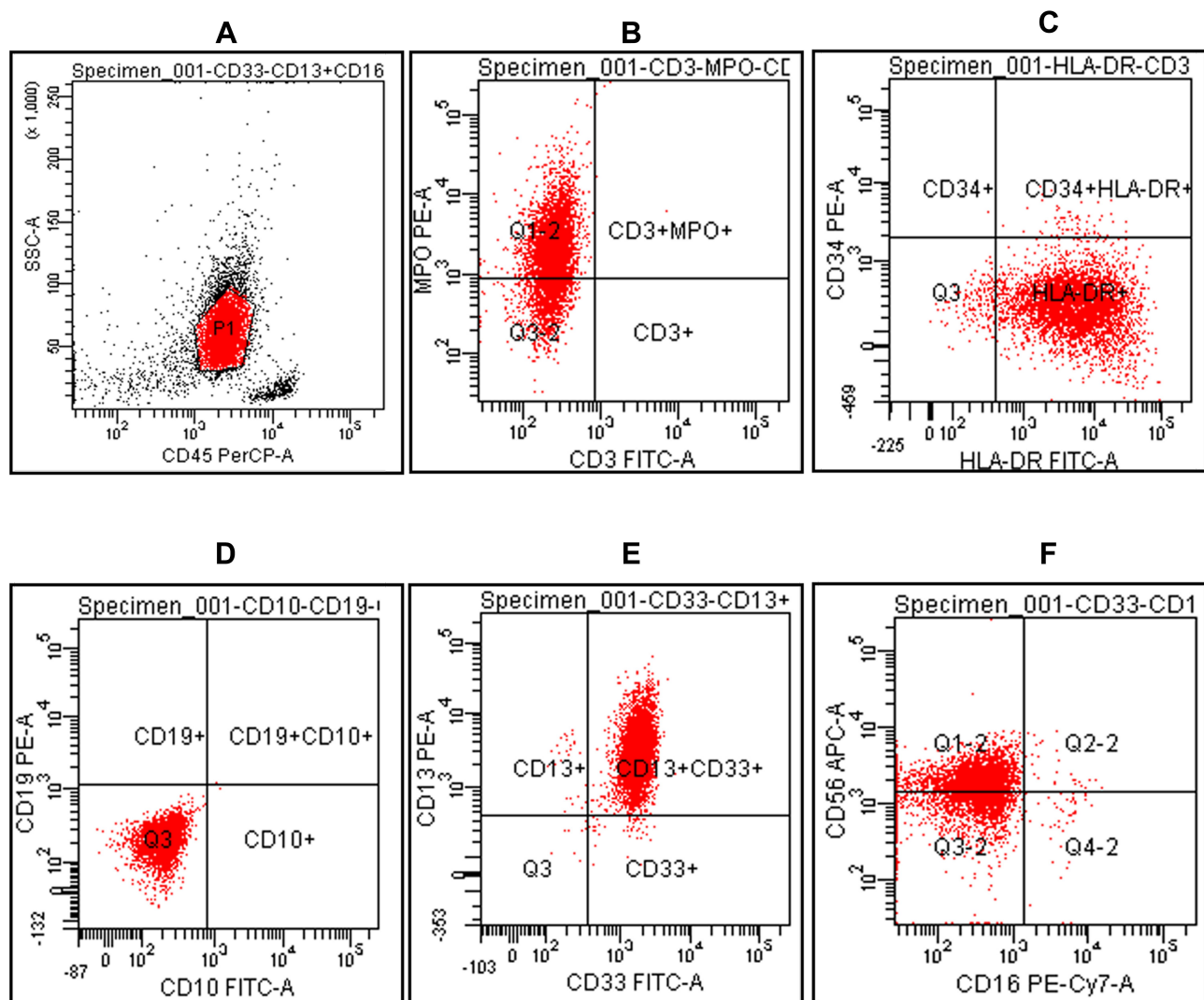


Figure 2 Flow cytometry scatterplots showing an immunotype consisting of abnormal populations in an AML patient with *NUP98-RARG* gene fusion. **(A)** CD45 gating: a group of abnormal cells is circled. **(B)** Positive myeloperoxidase (MPO) and negative CD3 expression. **(C)** Positive human leukocyte antigen (HLA)-DR and negative CD34 expression. **(D)** CD19 and CD10 negativity. **(E)** CD13 and CD33 positivity. **(F)** CD56 and CD16 negativity.

(Figure 4); fluorescence quantitative PCR detection of the *PML-RARA* fusion transcript was negative, but mutations were detected in several genes at various frequencies including *isocitrate dehydrogenase (IDH)2* (37.68%), *ten-eleven translocation (TET)2* (49.72%), *additional sex combs-like (ASXL)1* (100%), *tumor protein (TP)53* (54.75%), *Wilms' tumor (WT)1*-exon7 (100%), and *WT1*-exon9 (43.77%). Treatment with ATRA and ATO was discontinued, and diuretic detumescence and ventilator-assisted respiratory therapy were administered. A second BM smear showed 95.5% abnormal promyelocytic granulocytes, with an occasional Auer body in the form of an Auer bundle; the rate of positive peroxidase staining was 100%, suggesting no remission (Figure 1D and E). This

indicated that the patient was completely resistant to ATRA and ATO, and the treatment was switched to the IA regimen (idarubicin [10 mg/m² for 3 days] and cytarabine [150 mg/day for 7 days]) as induction therapy. The patient experienced severe pulmonary infection on day 7 after initiation of the regimen, and received antibiotics for 2 weeks until the infection was gradually controlled; however, WBC and platelet counts remained low, and a third BM smear showed 10.5% blasts. A HIAG chemotherapy regimen (homoharringtonine [2 mg/day] for 7 days, idarubicin [5 mg/day for 4 days], cytarabine [40 mg/day for 14 days], and granulocyte colony-stimulating factor [G-CSF; 300 µg/day until WBC count was >20×10⁹/l]) was administered as reinduction chemotherapy. A BM examination

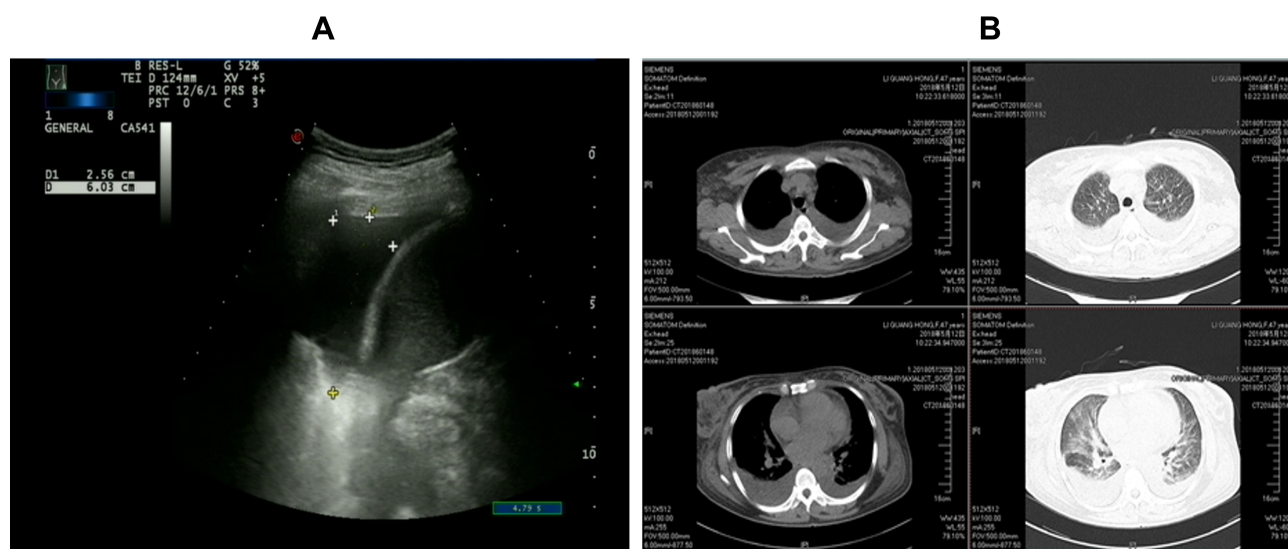


Figure 3 Chest computed tomography (CT) and color Doppler ultrasound of the patient. (A) Color Doppler ultrasound showing pleural effusion at a depth of 6.03 cm. (B) Chest CT showing pleural effusion on both sides.




Figure 4 Karyotype of an AML patient with *NUP98-RARG* gene fusion. G-banding revealed a karyotype of 45, X, -X, del(9)(q13q22), t(11;12)(p15; q13); arrows indicate 11p+, 12q-, and 9q-.

was performed to evaluate the response to HIAG; the smear showed 0.5% blasts, indicating that the patient had achieved complete remission (Figure 1F).

Consolidation therapy with the HIAG regimen was initiated on August 13, 2018. During the BM suppression period following chemotherapy, severe pulmonary infection, septic shock, metabolic acidosis, heart failure, and other serious complications occurred; the patient was admitted to the intensive care unit for emergency treatment, and recovered after 1 month. The patient refused to undergo allogeneic hematopoietic stem cell transplantation (allo-HSCT). Since September 19, 2018, the patient has received 2 cycles of half-dose CAG regimen (aclerubicin hydrochloride [20 mg/day for 4 days], cytarabine [40 mg/day for 7 days], and GCSF [300 µg/day until WBC count was $>20 \times 10^9/l$]) and 2 cycles of the HA regimen (homoharringtonine [4 mg/day for 3 days] and cytarabine [150 mg/day for 7 days]) as consolidation chemotherapy. The minimal residual disease detected by flow cytometry was negative during each round of consolidation chemotherapy. The treatment timeline is shown in Figure 5. The patient remains alive and was leukemia-free at the last (24-month) follow-up.

RT-PCR

NUP98-RARG mRNA was reverse transcribed into cDNA using random hexamers, and PCR was performed using the following primers: *NUP98* forward, 5'-GAG TAACCAAGCCTCACAGC-3' and *RARG* reverse, 5'-CCCATAGTGGTAGCCTGAGGAC-3'. A 200-bp product was specifically amplified from the patient's cDNA, representing the *NUP98-RARG* fusion product (Figure 6A).

Cytogenetic Analysis and Fluorescence in situ Hybridization (FISH)

A BM sample was processed after short-term culture (24 h) according to standard procedures. The chromosomes were stained by G-banding and the karyotype was determined according to International System for Human Cytogenetic Nomenclature recommendations. FISH was performed on 200 interphase cells using dual-color translocation probes (Figure 6B).

Results and Discussion

Nine patients harboring a *NUP98-RARG*, *PML-RARG*, *CPSF6-RARG*, or *NPM1-RARG-NPM1* gene rearrangement have been described to date; their age, sex, and molecular and genetic characteristic are shown in Table 1. In 2011, Such et al first reported *NUP98-RARG* fusion in an AML patient with morphologic and immunophenotypic features resembling APL (Table 1, No.1), the patient discontinued ATRA treatment due to absence of a *PML-RARA* fusion gene and was switched to a standard 3+7 regimen with cytarabine and idarubicin, undergoing consolidation chemotherapy followed by autologous SCT.⁶ Patient 2 was a 64-year-old woman with *PML-RARG* fusion (Table 1, No.2); her BM smears showed atypical hypergranular promyelocytes with Auer rods, and she received idarubicin and cytarabine chemotherapy after 9 days of ATRA treatment as well as 1 cycle of high-dose cytarabine consolidation chemotherapy followed by allo-HSCT.⁷ In addition to *NUP98-RARG* fusion, *CPSF6-RARG* or *NPM1-RARG-NPM1* fusion have been detected in AML patients who all showed the classic morphologic and immunophenotypic features of APL and were resistant to ATRA and ATO. The common

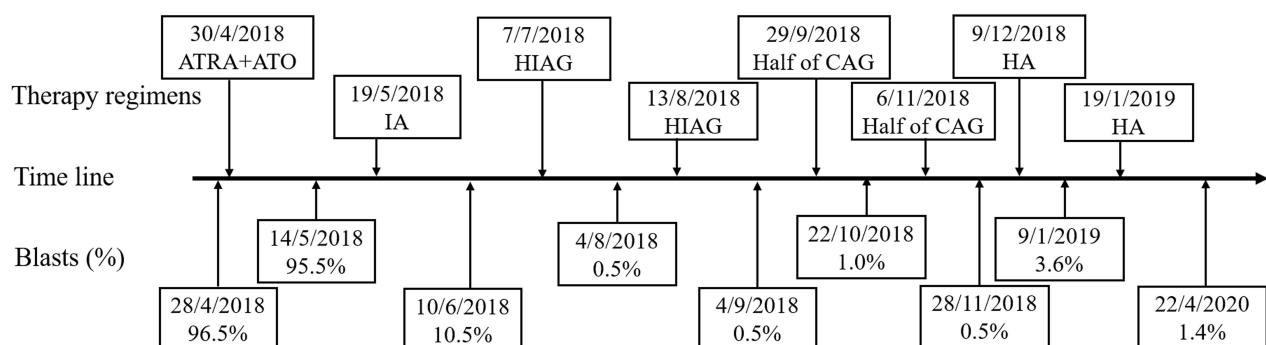


Figure 5 Timeline of patient's treatment.

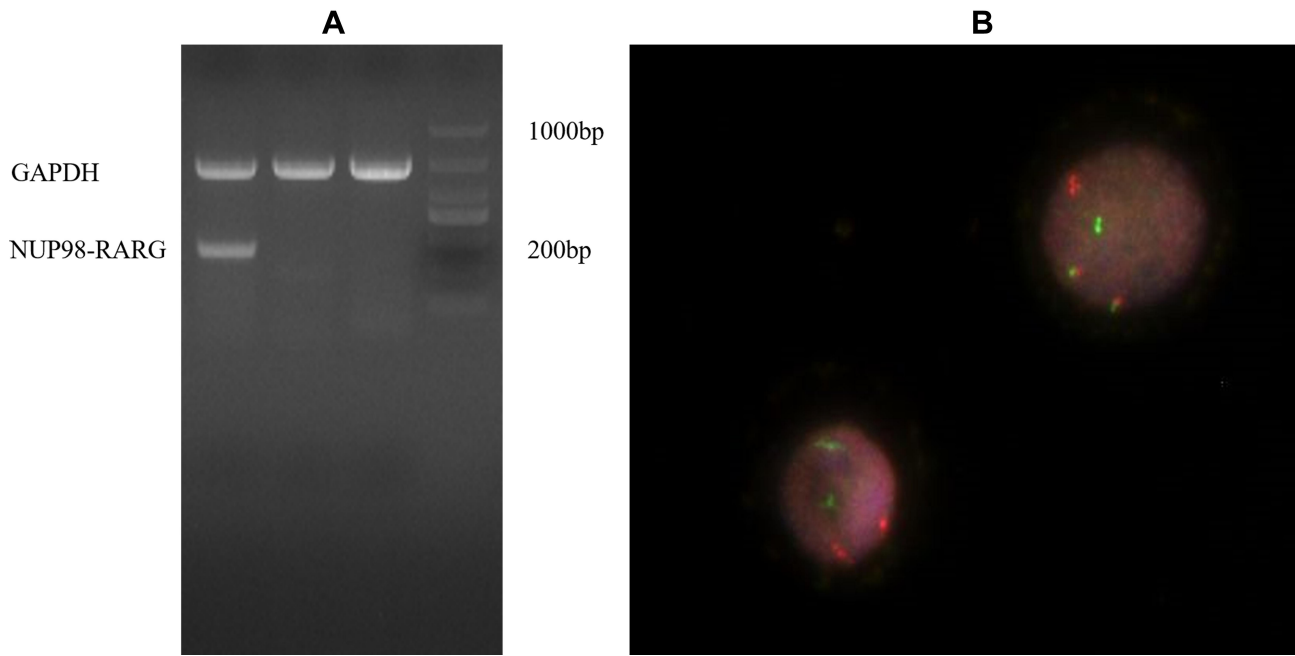


Figure 6 Detection of *NUP98-RARG* by RT-PCR and FISH. **(A)** *NUP98-RARG* mRNA was detected by RT-PCR analysis of leukemia cell total RNA derived from the AML patient; the product size was 200 bp. **(B)** FISH using dual color *NUP98-RARG* probes. The 2 orange signals show *NUP98-RARG* fusion, while green *RARG* and red *NUP98* signals are present on intact chromosomes 11 and 12, respectively.

characteristic of these patients was the presence of *RARG* rearrangement. Some partner proteins can bind to different DNA-binding domains of *RARG* to form fusion proteins such as *PML-RARG*, *NUP98-RARG*, *CPSF6-RARG*, and *NPM1-RARG-NPM1*. *NUP98* exon 12 was fused in frame to *RARG* exon 4, forming the *NUP98-RARG* fusion gene.⁵ However, the role of *RARG* in AML has yet to be elucidated.

The patient described herein was a 47-year-old female presenting with features of APL without a detectable *PML-RARA* fusion by RT-PCR. We detected the *NUP98-RARG*

fusion gene in our patient by PCR using previously described primers (Figure 6A). The cytogenetic analysis revealed an intermediate-risk karyotype of 45, X, -X, del (9)(q13q22), t (11;12)(p15;q13), and the *NUP98-RARG* fusion was also detected by FISH (Figure 6B). ATRA and ATO treatment was discontinued and switched to idarubicin and cytarabine. The patient experienced serious complications during the initial IA induction chemotherapy and subsequent low-dose regimen, and had poor compliance and refused allo-HSCT; we were also concerned about the risk of treatment-related death. Therefore, the patient received 6 cycles of low-dose

Table 1 Acute Myeloid Leukemia Resembling Acute Promyelocytic Leukemia with *RARG* Rearrangements in Literatures

Case No.	Sex/Age (Years)	Cytogenetic Abnormal	<i>RARG</i> Rearrangements	Survival (Days)	Reference
1	M/35	t (11;12) (p15; q13)	<i>NUP98-RARG</i>	730	Such, et al, 2011 ⁶
2	F/64	t (12;15) (q13; q22)	<i>PML-RARG</i>	NA	Ha, et al, 2017 ⁷
3	M/26	45, X, -Y [10]/idem, add (6) (q?13) [2]	<i>RARG-CPSF6</i>	NA	Miller et al, 2018 ⁸
4	F/51	46, XX, del (12) (p12) [2]/46, XX [18]	<i>CPSF6-RARG</i>	>90	Liu et al, 2018 ⁹
5	F/48	92, XXXX [2]	<i>CPSF6-RARG</i>	<60	Liu et al, 2018 ⁹
6	M/38	46, XY [20]	<i>CPSF6-RARG</i>	37	Qin et al, 2018 ¹⁰
7	M/22	46, XY, t (11;12) (p15; q13)	<i>NUP98-RARG</i>	NA	Zhang et al, 2019 ¹¹
8	F/45	46, XX, t (11;12) (p15; q13) [16]	<i>NUP98-RARG</i>	35	Luo et al, 2019 ¹²
9	M/69	46, XY	<i>NPM1-RARG-NPM1</i>	240	Chen et al, 2019 ¹³
10	M/55	46, XY	<i>CPSF6-RARG</i>	>360	Zhang et al, 2020 ¹⁷

Abbreviations: No., number; M, male; F, female; NA, not available.

CAG and HA regimens as consolidation chemotherapy. At present, the patient is alive and in complete remission.

It was reported that *NUP98* exon 12 is fused in-frame to *RARG* exon 4,⁵ but the mechanism of oncogenic transformation mediated by *NUP98–RARG* in AML is unknown. An in vitro study showed that the *NUP98–RARG* fusion was extremely sensitive to ATRA treatment, implying that retinoid/rexinoid signaling plays an important role in AML and is a potential therapeutic target for patients harboring this chromosomal abnormality.¹⁴ However, another study examining relapsed primary blasts of an AML patient with *NUP98–RARG* rearrangement found that they were resistant to ATRA.¹⁵ Consistent with other case reports, we found that leukemia cells with *NUP98–RARG* fusion were completely resistant to both ATRA and ATO. Abnormalities in other genes such as *WT1* and *enhancer of zeste homolog 2* may confer ATRA resistance.^{10,16} Our patient also harbored 2 *WT1* mutations and *IDH2*, *TET2*, *ASXL1*, or *TP53* mutations. AML patients with *RARG* rearrangement can be treated with either idarubicin or homoharringtonine and cytarabine as the induction chemotherapy regimen,^{6,11,17} while allo-HSCT is recommended for post-remission treatment.

In summary, previous reports and findings from our case demonstrate that *NUP98–RARG* rearrangement defines a novel subtype of AML with morphologic and immunologic characteristics similar to APL but showing resistance to ATRA and ATO treatment. Further studies are needed to clarify the mechanism by which *NUP98–RARG* fusion promotes leukemogenesis and confers ATRA resistance in this subset of AML patients.

Patient Statement

Written, informed consent for publication of the case details was obtained from the patient.

Abbreviations

allo-HSCT, allogeneic hematopoietic stem cell transplantation; AML, acute myeloid leukemia; APL, acute promyelocytic leukemia; *ASXL1*, additional sex combs-like 1; ATO, arsenic trioxide; ATRA, all-trans retinoic acid; BM, bone marrow; CD, cluster of differentiation; FISH, fluorescence in situ hybridization; GCSF, granulocyte colony-stimulating factor; Hg, hemoglobin; *IDH2*, isocitrate dehydrogenase 2; *NUP98*, nucleoporin 98; *RARA*, retinoic acid receptor alpha; *RARG*, retinoic acid receptor gamma; RT-PCR, reverse transcription-polymerase chain reaction;

TET2, ten-eleven translocation 2; *TP53*, tumor protein 53; WBC, white blood cell; *WT1*, Wilms' tumor 1.

Funding

This work was supported by research grants from the Science and Technology Fund of Huai'an City (no. HAB201810) and Science and Technology Fund of Jiangsu Commission of Health (nos. H2018085 and H2019082).

Disclosure

The authors report no conflicts of interest in this work. Co-first authors: Shandong Tao, Lixiao Song.

References

- Short NJ, Rytting ME, Cortes JE. Acute myeloid leukaemia. *Lancet*. 2018;392(10147):593–606. doi:10.1016/S0140-6736(18)31041-9
- Szotkowski T, Faber E, Hubacek J, et al. Acute promyelocytic leukemia successfully treated also in elderly patients with significant comorbidities: a 20-year single-center experience. *Neoplasma*. 2015;62(01):146–151. doi:10.4149/neo_2015_019
- Lo-Coco F, Avvisati G, Vignetti M, et al. Retinoic acid and arsenic trioxide for acute promyelocytic leukemia. *N Engl J Med*. 2013;369(2):111–121. doi:10.1056/NEJMoa1300874
- Sanz MA, Fenaux P, Tallman MS, et al. Management of acute promyelocytic leukemia: updated recommendations from an expert panel of the European leukemianet. *Blood*. 2019;133(15):1630–1643. doi:10.1182/blood-2019-01-894980
- Conserva MR, Redavid I, Anelli L, et al. *RARG* gene dysregulation in acute myeloid leukemia. *Front Mol Biosci*. 2019;6:114.
- Such E, Cervera J, Valencia A, et al. A novel *NUP98/RARG* gene fusion in acute myeloid leukemia resembling acute promyelocytic leukemia. *Blood*. 2011;117(1):242–245. doi:10.1182/blood-2010-06-291658
- Ha JS, Do YR, Ki CS, et al. Identification of a novel *PML–RARG* fusion in acute promyelocytic leukemia. *Leukemia*. 2017;31(9):1992–1995. doi:10.1038/leu.2017.167
- Miller CA, Tricarico C, Skidmore ZL, et al. A case of acute myeloid leukemia with promyelocytic features characterized by expression of a novel *RARG–CPSF6* fusion. *Blood Adv*. 2018;2(11):1295–1299. doi:10.1182/bloodadvances.2017014183
- Liu T, Wen L, Yuan H, et al. Identification of novel recurrent *CPSF6–RARG* fusions in acute myeloid leukemia resembling acute promyelocytic leukemia. *Blood*. 2018;131(16):1870–1873. doi:10.1182/blood-2017-11-818716
- Qin YZ, Huang XJ, Zhu HH. Identification of a novel *CPSF6–RARG* fusion transcript in acute myeloid leukemia resembling acute promyelocytic leukemia. *Leukemia*. 2018;32(10):2285–2287. doi:10.1038/s41375-018-0095-z
- Zhang X, Li F, Wang J, et al. *RARγ*-rearrangements resemble acute promyelocytic leukemia and benefit from 3 + 7 regimen. *Leuk Lymphoma*. 2019;60(7):1831–1834. doi:10.1080/10428194.2018.1553302
- Luo H, Zhang S, Li K, et al. A novel entity of acute myeloid leukaemia with recurrent *RARG*-rearrangement resembling acute promyelocytic leukaemia. *Leuk Res*. 2019;77:14–16. doi:10.1016/j.leukres.2018.12.009
- Chen X, Wang F, Zhang Y, et al. A novel *NPM1–RARG–NPM1* chimeric fusion in acute myeloid leukaemia resembling acute promyelocytic leukaemia but resistant to all-trans retinoic acid and arsenic trioxide. *Br J Cancer*. 2019;120(11):1023–1025. doi:10.1038/s41416-019-0456-z

14. Qiu JJ, Zeisig BB, Li S, et al. Critical role of retinoid/rexinoid signaling in mediating transformation and therapeutic response of NUP98-RARG leukemia. *Leukemia*. 2015;29(5):1153–1162. doi:10.1038/leu.2014.334
15. Such E, Cordon L, Sempere A, et al. In vitro all-trans retinoic acid sensitivity of acute myeloid leukemia blasts with NUP98/RARG fusion gene. *Ann Hematol*. 2014;93(11):1931–1933. doi:10.1007/s00277-014-2073-5
16. Coccaro N, Zagaria A, Orsini P, et al. RARA and RARG gene down-regulation associated with EZH2 mutation in acute promyelocytic-like morphology leukemia. *Hum Pathol*. 2018;80:82–86. doi:10.1016/j.humpath.2018.02.023
17. Zhang Z, Jiang M, Borthakur G, et al. Acute myeloid leukemia with a novel CPSF6-RARG variant is sensitive to homoharringtonine and cytarabine chemotherapy. *Am J Hematol*. 2020;95(2):E48–E51. doi:10.1002/ajh.25689

OncoTargets and Therapy

Dovepress

Publish your work in this journal

OncoTargets and Therapy is an international, peer-reviewed, open access journal focusing on the pathological basis of all cancers, potential targets for therapy and treatment protocols employed to improve the management of cancer patients. The journal also focuses on the impact of management programs and new therapeutic

agents and protocols on patient perspectives such as quality of life, adherence and satisfaction. The manuscript management system is completely online and includes a very quick and fair peer-review system, which is all easy to use. Visit <http://www.dovepress.com/testimonials.php> to read real quotes from published authors.

Submit your manuscript here: <https://www.dovepress.com/oncotargets-and-therapy-journal>