


Retinal Microvasculature in Schizophrenia

Steven M Silverstein ¹⁻⁴

Adriann Lai ¹

Kyle M Green³

Christen Crosta⁵

Samantha I Fradkin⁶

Rajeev S Ramchandran^{3,7}

¹Department of Psychiatry, University of Rochester Medical Center, Rochester, NY, USA; ²Department of Neuroscience, University of Rochester Medical Center, Rochester, NY, USA; ³Department of Ophthalmology, University of Rochester Medical Center, Rochester, NY, USA; ⁴Center for Visual Science, University of Rochester, Rochester, NY, USA; ⁵Department of Cell Biology and Neuroscience, Rutgers University, Piscataway, NJ, USA; ⁶Department of Psychology, University of Rochester, Rochester, NY, USA; ⁷Department of Public Health Sciences, University of Rochester Medical Center, Rochester, NY, USA

Purpose: Schizophrenia is associated with alterations in neural structure and function of the retina that are similar to changes seen in the retina and brain in multiple neurodegenerative disorders. Preliminary evidence suggests that retinal microvasculature may also be compromised in schizophrenia. The goal of this study was to determine, using optical coherence tomography angiography (OCTA), whether 1) schizophrenia is associated with alterations in retinal microvasculature density; and 2) microvasculature reductions are associated with retinal neural layer thinning and performance on a measure of verbal IQ.

Patients and Methods: Twenty-eight outpatients with schizophrenia or schizoaffective disorder and 37 psychiatrically healthy control subjects completed OCT and OCTA exams, and the Wechsler Test of Adult Reading.

Results: Schizophrenia patients were characterized by retinal microvasculature density reductions, and enlarged foveal avascular zones, in both eyes. These microvascular abnormalities were generally associated with thinning of retinal neural (macular and peripapillary nerve fiber layer) tissue (but the data were stronger for the left than the right eye) and lower scores on a proxy measure of verbal IQ. First- and later-episode patients did not differ significantly on OCTA findings.

Conclusion: The retinal microvasculature impairments seen in schizophrenia appear to be a biomarker of overall brain health, as is the case for multiple neurological conditions. Additional research is needed, however, to clarify contributions of social disadvantage and medical comorbidities to the findings.

Keywords: schizophrenia, retina, OCT angiography, OCTA, venule, arteriole

Introduction

Schizophrenia is a multi-system disorder that involves a significant vascular component. This was described long ago by Bleuler, who noted “The fragility of the blood vessels which appears in many schizophrenics, both acute and chronic, seems to indicate a real vascular pathology”.¹ More recently, studies indicate both peripheral² and central nervous system³ microvasculature abnormalities, in addition to elevated rates of cardiac disease⁴ and a significant overrepresentation of genes involved in vascular function among schizophrenia candidate risk genes.⁵ Based on this and other evidence, it has been suggested that schizophrenia is an adult vascular-ischemic disorder,⁵ with vascular changes occurring secondary to neuroinflammatory processes and eventually leading to changes in neural function and neuroanatomy.⁶

The retina is a part of the central nervous system (CNS) that derives from the same tissue as the brain in early development, and the retina and brain share many aspects of cytoarchitecture and physiology, including neurotransmitter and receptor types. As a result, the retina is often referred to as a “window to the brain”.⁷ Studies of changes in

Correspondence: Steven M Silverstein
Department of Psychiatry, University of Rochester Medical Center, 300
Crittenden Boulevard, Rochester, NY,
14642, USA
Tel +1 585 275-6742
Fax +1 585 276-2094
Email steven_silverstein@urmc.rochester.edu

neural retinal structure have been informative regarding changes in brain structure and function, and disease progression, in neurodegenerative diseases,⁷ and accumulating evidence suggests that retinal microvasculature changes are also informative in cases of CNS disease.^{3,8–11}

A brief and non-invasive method for assessing the state of retinal vasculature is optical coherence tomography angiography (OCTA).^{12–18} OCT is a method based on low-coherence interferometry that uses the difference between the power in spectral frequencies of near-infrared light reflected back from the eye, relative to the frequency composition of the original light output, to generate detailed images of retinal layers (conventional OCT) and the retinal microvasculature (OCTA), in a manner analogous to how ultrasound is used to generate biological images. Imaging of the microvasculature specifically is implemented via analysis of motion contrast across the rapidly collected images. A decorrelation technique is applied to successive images; patterns that are similar across scans are interpreted as stable tissue, whereas regions that show differences across successive images are interpreted as flow through blood vessels, and therefore the presence (and location, length, and width) of blood vessels. The use of OCTA in the field of neurology has generated data indicating that a wide range of neurodegenerative diseases are characterized by retinal microvasculature abnormalities, with extent of the alteration (eg, reduced density of vessels) often being correlated with disease severity.^{9–11,19} OCTA is only now beginning to be incorporated into psychiatric studies, however. Previous studies of the retinal microvasculature in schizophrenia using conventional fundus photography have reported wider venules,^{3,20} narrower arterioles,²⁰ and abnormal trajectories of venules and arterioles.^{21,22} OCTA provides estimates of the total area containing blood vessels, and the total length of blood vessels within prescribed regions of the retina (see Figures 1 and 2), which are indices that have not been previously reported on in schizophrenia in published studies.

Thus, we sought to characterize the retinal microvasculature in schizophrenia using OCTA. Because there is evidence from OCT that thinning of retinal layers in schizophrenia may not develop until several years after the first psychotic episode,^{23–26} we investigated a sample that included both people recovering from a first episode of schizophrenia (eg, patients with a single hospitalization that

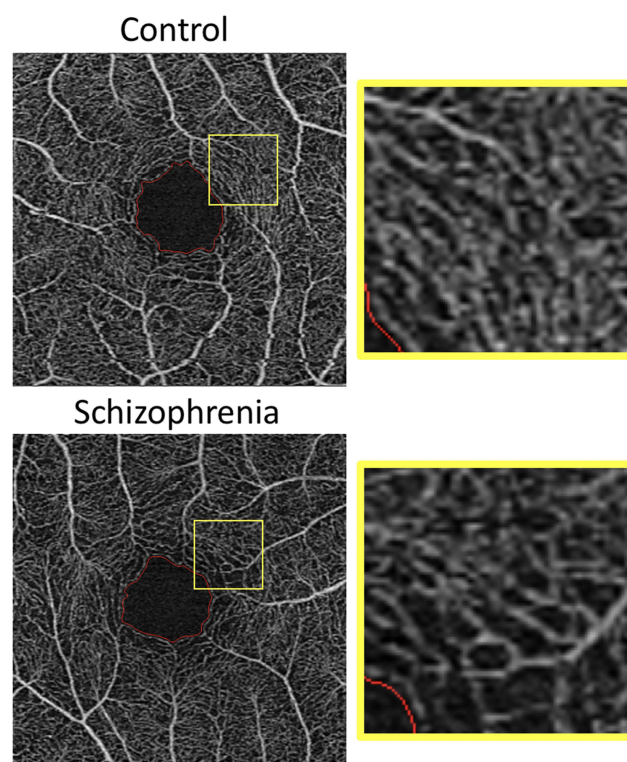


Figure 1 OCTA images of superficial retinal layer vasculature in a psychiatrically healthy control subject (top left) that was age-matched to a later-episode schizophrenia patient (bottom left). Reduced microvasculature density is clearly visible in the lower image (see also Figures 2–4 for additional information). The foveal avascular zone is highlighted with a red border. This region was larger in the schizophrenia sample (see Table 3). The same subsection of each image, bounded by a yellow square, is enlarged and shown to the right of each primary image. Microvasculature reduction is more easily visible in these enlargements, despite the lowered resolution.

had occurred no more than 2 years prior to testing), and people with a longer period of established illness (ie, who had experienced multiple hospitalizations for psychotic episodes, with greater than 2 years since their initial episode), in order to determine if any OCTA findings would follow this pattern. Of note, the OCTA data reported here were collected from the subject sample in one of our prior OCT studies.²⁴ The results of that study indicated macula thinning in the later-episode, but not first-episode, schizophrenia participants relative to age-matched controls. These findings are consistent with emerging evidence of retinal abnormalities in people with schizophrenia^{26–29} and, in some cases, in those at high risk for the disorder.^{30–32} Here we report: 1) OCTA findings from this sample; 2) relationships between microvascular and neural layer thickness and volume; and 3) the relationship between retinal microvasculature and estimated verbal IQ.

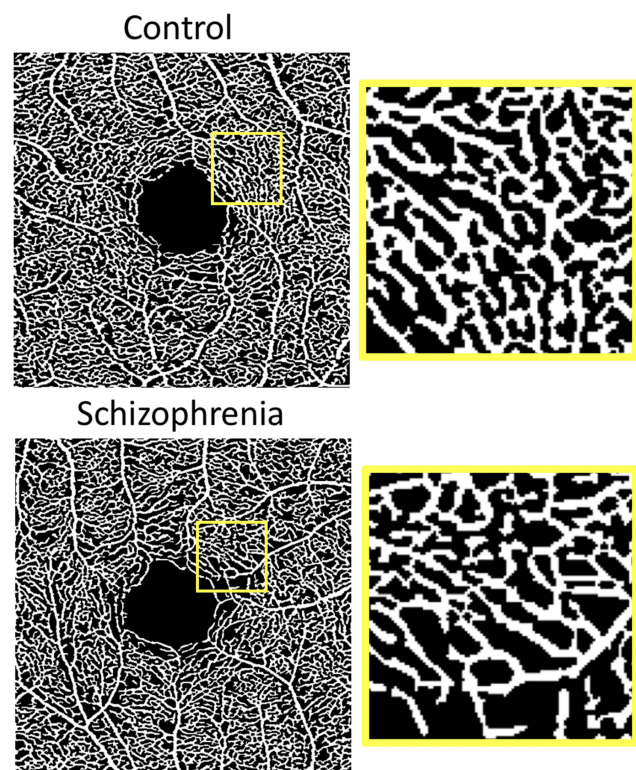


Figure 2 Perfusion density traces of the images shown in Figure 1. These images are binarized, so that regions that exceed a standard brightness threshold are rendered in white, while all other regions are rendered in black. These images depict the total area of the image containing blood vessels. The smaller images to the right are magnified views of the regions bordered by yellow squares. These images offer an additional perspective on retinal microvasculature reduction observed in schizophrenia.

Patients and Methods

Subjects

This study was conducted in accordance with the Declaration of Helsinki. The study was approved by the Institutional Review Board of Rutgers Biomedical and Health Sciences, and subjects provided written informed consent. Thirty-three people with a diagnosis of schizophrenia or schizoaffective

disorder and 38 psychiatrically healthy control subjects participated in the study. Demographic data on subjects are found in Table 1. The patient group included 15 young people recovering from their first psychotic episode, with their single hospitalization occurring within the past 2 years, and 18 people with at least two hospitalizations due to psychotic symptoms; for 17 out of these 18 later-episode participants, it had been over 5 years since their first hospitalization. The control group included 20 subjects under 30 years of age and 18 healthy control subjects over 30 years of age. As described in Lai et al,²⁴ inclusion criteria were: age between 18–65 years, an understanding of English, and normal or corrected-to-normal visual acuity as measured by a logarithmic acuity chart. Exclusion criteria included a history of eye injury or disease (eg, cataracts, macular degeneration, diabetic retinopathy, glaucoma); neurological, intellectual, mood, or developmental disorders; a history of head injury with loss of consciousness of more than 10 minutes; electroconvulsive therapy within the last 8 weeks; amblyopia (lazy eye) or a squint; and diabetes or high blood pressure. For patient participants, chlorpromazine (CPZ) equivalent dose, as a measure of total amount of antipsychotic medication currently taken daily, was calculated according to the method described by Leucht et al.³³

WTAR

The Wechsler Test of Adult Reading (WTAR)³⁴ was administered to each participant prior to their OCT session. This is a reliable, valid, and brief measure that is used to generate an estimate of a verbal intelligence quotient (IQ), which is typically viewed as a proxy for premorbid full-scale IQ in neuropsychiatric populations.³⁵

Table 1 Age, Race, Ethnicity, and Medication Data, by Group, and for the Sample as a Whole

	Age	CPZ	% White	%* Hispanic	% Male
Control (n=37)	32.22 (12.63) [†]		65	14	65
Schizophrenia (n=28)	32.21 (11.27) [‡]	235.58 (266.14)	23	18	86
Total (n=65)	32.22 (11.97)		48	15	74

*Notes: Hispanic ethnicity, as reported here, is independent of race, as per NIH (USA) reporting guidelines. [†]The age range for younger controls was 20–27 (mean=23.05, SD=2.35), and for older controls was 30–65 (mean=41.89, SD=11.79). [‡]The age range for first episode schizophrenia patients was 19–42 (mean=24.00, SD=6.22) and for later episode patients was 25–59 (mean=38.37, SD=10.28).

OCT and OCTA

OCT data were acquired with a Cirrus 5000 high definition (HD-) OCT scanner, a spectral domain (SD) OCT device. The OCT scanner acquired data at a scan depth of 2 millimeters, with a resolution of 5 micrometers, at a rate of approximately 27,000 axial (A-) scans per second. OCT angiograms were acquired from 3×3 mm² scans centered on the foveal avascular zone (FAZ), the region at the center of the fovea in which blood vessels are absent. The region covered by the scans therefore includes the FAZ (typically 500 microns wide), the fovea (typically 1.5 mm wide, including the FAZ), and the area surrounding the fovea. Automated segmentation of the FAZ from the surrounding vasculature, and all analyses of OCTA raw image data were implemented using AngioPlex Metrix™, software developed by Carl Zeiss Meditec, Inc. OCTA measures examined for this report were superficial layer perfusion density (reflecting the total percentage of the 3×3 mm² region containing blood vessels, with larger vessels contributing more to the estimate, which can be considered an estimate of potential retinal perfusion), and vessel density (the total length of all blood vessels, independent of blood vessel width, which represents the density of the vascular network). While the variables are significantly correlated, vessel density has been shown to be the strongest OCTA discriminator of healthy eyes from those with retinal disease.³⁶ We also measured FAZ raw size (total area), as this enlarges when vessel density is reduced.

All images used for generating perfusion and vessel density metrics were read by both a researcher at Zeiss, and by an ophthalmologist (KMG), who were, for all images, unaware of the group membership of the participant. Images were excluded if there was evidence of excessive motion artifact or signal inhomogeneity. This led to exclusion of data from 16 eyes in total (two right eyes from younger controls; two left eyes and one right eye from first episode patients; two left eyes from older controls; four left eyes and five right eyes from later episode patients). OCT-A scans were of poor quality in both eyes of six subjects, accounting for 12 of the 16 eyes with poor-quality data. These six subjects (one younger control, and five patients (two first episode, three later episode)) did not contribute any data to the study. Therefore, the sample of OCTAs of sufficient quality to be included in the study were drawn from 28 patients (12 first episode, 16 later episode) and 37 controls (18 under 30 years of age, 19 over 30).

Individual analyses often included slightly fewer participants due to single eye exclusions for specific images, as noted above. Images for which the FAZ was not centered were used if none of the exclusion criteria listed above were met, as is common practice. In total, three eyes had non-centered scans: one from the younger schizophrenia subgroup and two from the older patient group. For all images used, OCTA signal strength was high (8 or higher out of a possible 10), and in nearly all cases (see Results) was at least 9. A cutoff of 9 has been recommended due to differences in OCTA findings between images at lower vs higher levels, and a lack of differences between images with signal quality ratings of 9 or 10.³⁷ In clinical practice, however, images with ratings of 8 and 7 are often used. The manufacturer of the Cirrus 5000 HD-OCT device recommends using images with signal strength of 6 or greater for both OCTA and OCT images.³⁸

From the conventional OCT data on retinal layer thickness described in our earlier paper²⁴ we included here, for correlational analyses, data on macula central subfield (CSF: the 1 mm² region centered on the fovea) thickness, and macular cube volume (a 3D metric), which were the variables that differentiated the later episode schizophrenia group from all other groups (including first episode patients). We also included data on peripapillary retinal nerve fiber layer (RNFL) thickness from the previous dataset,²⁴ although these values did not differ between patient and control groups in the original study. Per convention, quality control was maintained by only including OCT scans with a signal quality of 7 (out of 10) or greater, and by visually reviewing every scan image to rule out evidence of retinal disease and significant artifacts. Previous studies have demonstrated that low signal quality in OCT images of retinal neural layers is associated with errors in segmentation of layers, and with reduced discrimination between healthy and diseased eyes.³⁹ All subjects had their right eye scanned first for OCT and OCTA protocols, followed by the left eye. During scanning, the non-scanned eye was occluded.

Data Analysis

Between-group comparisons on demographic variables used chi-square tests for categorical variables and *t*-tests for continuous variables. Between-group comparisons for the OCTA variables used Welch's ANOVAs due to group differences in variance, which can lead to inflated Type I error when using traditional parametric or nonparametric

Table 2 Verbal Intelligence Estimates (WTAR Scaled Scores), and Data on Participant, Maternal, and Paternal Education Levels, by Group

		N	Mean (SD)	t (df)	Sig.	Effect Size (Cohen's d)
WTAR	Control Schizophrenia	37 28	114.73 (8.79) 100.07 (14.41)	4.75 (41.86)	0.00	1.27
Years of education	Control Schizophrenia	37 28	17.16 (2.02) 14.73 (2.53)	4.30 (63)	0.00	1.08
Years of Education – Mother	Control Schizophrenia	37 25	15.22 (2.97) 14.60 (3.34)	0.76 (60)	0.45	0.20
Years of Education – Father	Control Schizophrenia	37 21	15.35 (3.31) 15.10 (2.76)	0.30 (56)	0.77	0.08

Note: Per convention $d=0.20$ is a small effect size, 0.50 is a medium effect size, and 0.80 or higher is considered a large effect size.

tests (eg, Kruskal–Wallis test). Spearman rho coefficients were used for correlational analyses due to differences in distribution sizes and characteristics between groups.

Results

Participants

Demographic and IQ characteristics of each group, along with medication data for patients, are reported in Tables 1 and 2. The groups did not differ in age, maternal education level, or paternal education level. The patient group had

a higher male–female ratio, but this difference did not reach statistical significance (Fisher's Exact test, $p=0.087$). The groups differed in their rates of self-reported white vs non-white status (control=24:13, patient=6:20, Fisher's Exact test, $p=0.002$), as well as in level of education and WTAR score (see Table 2).

Signal Strength for OCTA Scans

Mean OCTA signal strength was high for all of the images analyzed; specifically, it was 8 or higher in all cases, and 9

Table 3 OCT Angiography (OCTA) Findings, by Eye, by Group

		N	Mean (SD)	Welch F	df	Sig.	Effect Size (Eta-Squared)
Left Eye Perfusion Density	Control Schizophrenia	35 23	0.39 (0.02) 0.37 (0.03)	8.13	1, 27.38	0.01	0.16
Left Eye Vessel Density	Control Schizophrenia	35 23	22.14 (0.86) 21.02 (1.93)	6.89	1, 27.82	0.01	0.14
Right Eye Perfusion Density	Control Schizophrenia	35 24	0.39 (0.02) 0.38 (0.03)	4.90	1, 41.50	0.03	0.09
Right Eye Vessel Density	Control Schizophrenia	35 24	21.84 (1.25) 21.17 (1.65)	2.88	1, 40.49	0.10	0.05
Left Eye Signal Strength	Control Schizophrenia	35 24	9.97 (0.17) 9.67 (0.70)	4.35	1, 24.84	0.05	0.10
Right Eye Signal Strength	Control Schizophrenia	35 25	9.94 (0.24) 9.84 (0.55)	0.76	1, 30.25	0.39	0.02
Left Eye FAZ	Control Schizophrenia	35 22	0.21 (0.10) 0.29 (0.15)	4.94	1, 34.34	0.03	0.10
Right Eye FAZ	Control Schizophrenia	35 24	0.22 (0.09) 0.29 (0.13)	5.48	1, 38.97	0.02	0.10

Notes: Eta-squared values can range from 0 to 1. Per convention 0.01 is a small effect size, 0.06 is a medium effect size, and 0.14 or higher is considered a large effect size.

or 10 in most cases (five images out of 119 (4.2%) were rated 8). For the schizophrenia group the mean (SD) signal strength in the left eye was 9.67 (0.70) and in the right eye was 9.84 (0.55), and for the control group the values were 9.97 (0.17) and 9.94 (0.24), respectively. The between-group difference for signal strength in the left eye was statistically significant ($p=0.047$), whereas the right eye difference was not ($p=0.39$).

Between-Group Comparisons on Perfusion and Vessel Density

Means and standard deviations, and test results and effect sizes, for the four primary OCTA variables, are shown in Table 3, and additional characteristics of the distributions

are shown in Figures 3 and 4. Welch's ANOVAs indicated that the first and later episode schizophrenia groups did not differ on any OCTA variable or CPZ equivalent dose, and that the older and younger control groups did not differ on any OCTA variable, and so the two patient groups were combined, as were the two control groups, for all further analyses. The schizophrenia and control groups differed on left eye perfusion density and vessel density, and on right eye perfusion density, with the patient group demonstrating reduced density in all three cases. For right eye vessel density, the patient group also demonstrated a lower value, but the magnitude of the effect was at a trend level only. The schizophrenia group also demonstrated a significantly enlarged FAZ in both the left and right eye.

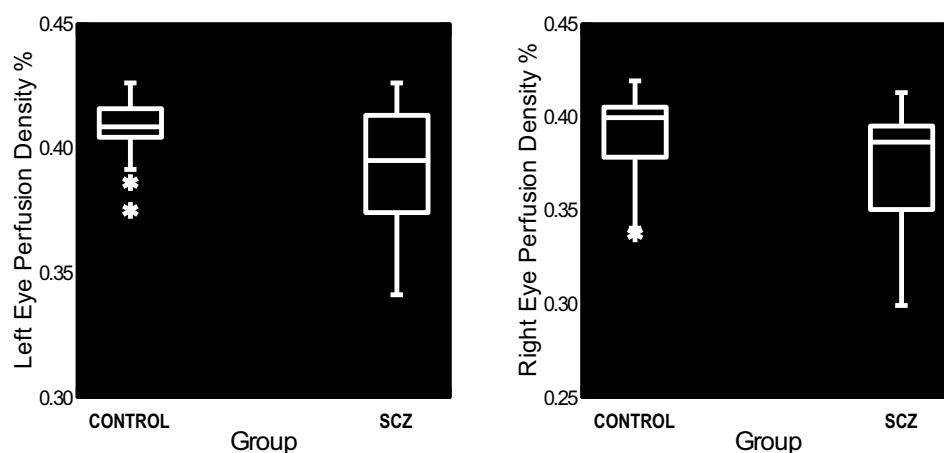


Figure 3 Box plots of perfusion density values for the left eye (left panel) and right eye (right panel), by group. Density is expressed the proportion of total area in the $3 \times 3 \text{ mm}^2$ image in which blood vessels are visible. Asterisks signify data points between 1–3 interquartile ranges from the lower hinge (25th percentile) of the boxplot. The main effect of group was significant in both cases. See text for statistical test results.

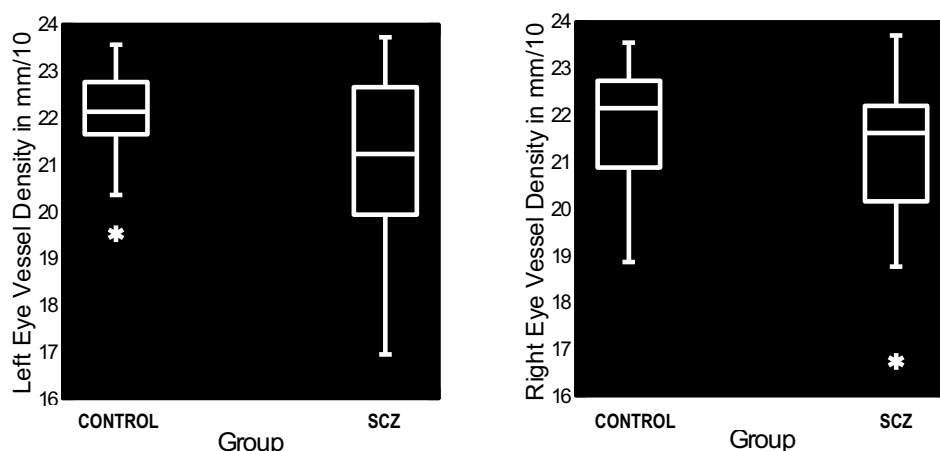


Figure 4 Box plots of vessel density values for the left eye (left panel) and right eye (right panel), by group. Density is expressed as total length of all vessels in the $3 \times 3 \text{ mm}^2$ image, in mm^{-1} . Asterisks signify data points between 1–3 interquartile ranges from the lower hinge (25th percentile) of the boxplot. The main effect of group was significant in both cases. See text for statistical test results.

Due to the significant difference in the racial composition of the patient and control groups, which raises the possibility that the patient-control group differences could be driven significantly by factors associated with interpersonal and medical histories that differed between white and non-white subjects, we performed post-hoc analyses on inter-race differences within the patient and control groups. For the patient group there were no significant differences on perfusion or vessel density, or FAZ size, in either eye. On some variables, the white subgroup had non-significantly reduced densities while on others the non-white group had lower values. The non-white group had higher (more abnormal) FAZ size values in both eyes. For left eye FAZ size, the effect size (d) of the difference was 0.71. In all other cases effect sizes were below 0.42. For the control group, where the tests were more highly powered than in the patient group, the non-white subgroup had higher density values

on three of the four density variables, and lower FAZ size values. Again, however, none of the differences were statistically significant, and effect sizes were all below 0.40, with the exception of right eye FAZ size, where the white subgroup had higher (more abnormal) values. In short, no pattern of white vs non-white differences emerged on OCTA variables, and the overall pattern of the direction of effects cannot account for the direction of patient vs control group differences.

Relationships Between OCTA Measures and Retinal Neural Tissue Thickness and Volume

For the sample as a whole, the correlation between perfusion density and macula CSF thickness for the left eye ($n=58$) was $r_s=0.49$ ($p<0.001$), and between perfusion density and macula cube volume was $r_s=0.54$ ($p<0.001$). For vessel

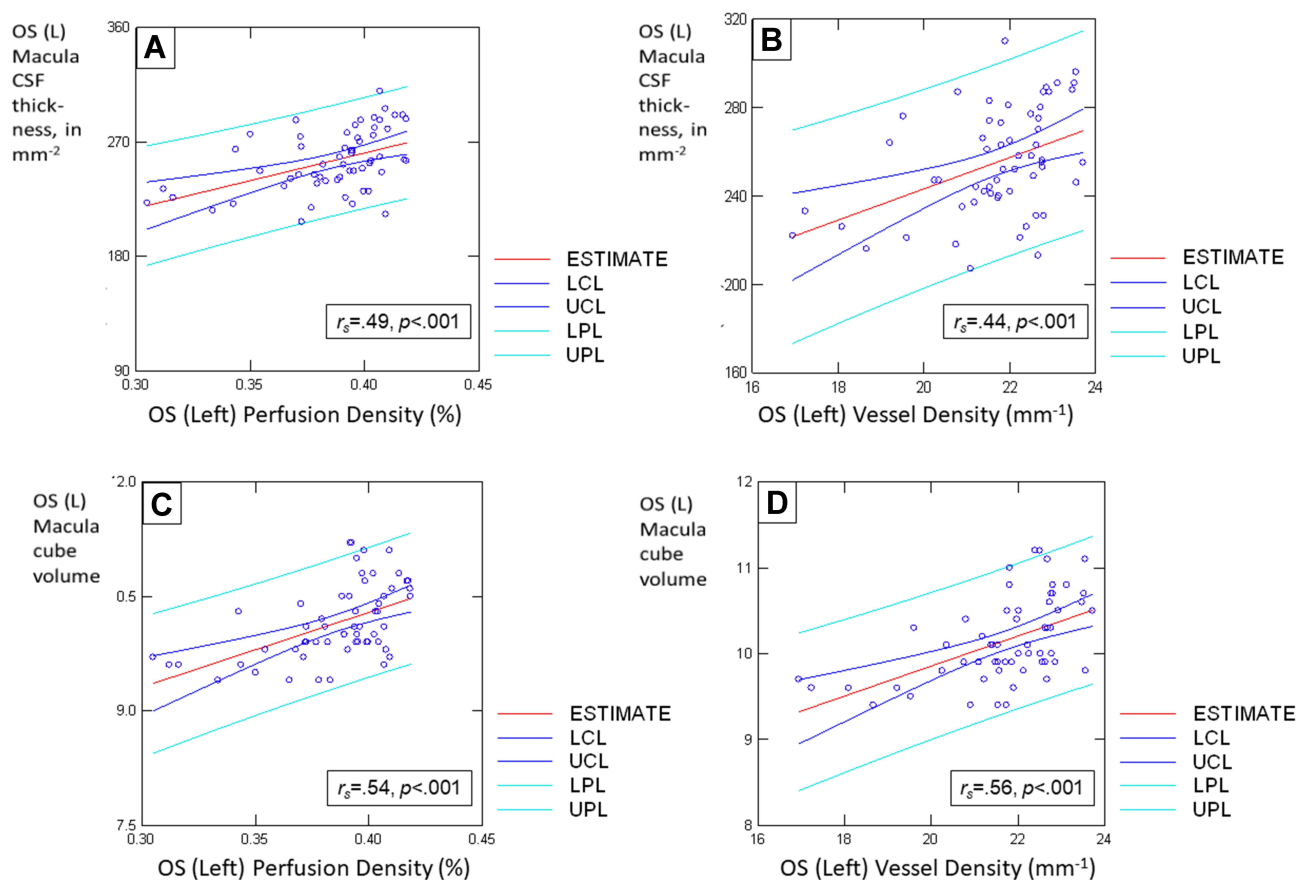


Figure 5 Scatterplots of relationships between left eye (OS) perfusion and vessel density values as predictors of left eye macula central subfield (CSF) thickness and cube volume, for the entire sample. Each panel shows all data points along with the best-fitting least-squares regression line (in red, labeled as "estimate"), upper and lower 95% confidence limits for a single mean response (inner, blue lines), and prediction limits for new observations (outer, cyan lines). The Spearman rho correlation coefficient and accompanying p -value, expressing the strength of the relationship between variables, is shown in the lower right portion of each panel. Panels display relationships between: (A) perfusion density and CSF thickness; (B) vessel density and CSF thickness; (C) perfusion density and cube volume; and (D) vessel density and cube volume. The same overall pattern of positive relationships existed in the right eye data, but relationships between variables were weaker than for the left eye in all cases. The relationships between variables were similar for patients and control subjects when considered as separate groups.

density, the correlation coefficients were 0.44 ($p=0.001$) and 0.56 ($p<0.001$), respectively. See Figure 5 for graphical descriptions of these relationships. These associations were weaker for the right eye ($n=62$): the correlation between perfusion density and macula CSF thickness was $r_s=0.31$ ($p=0.015$), and between perfusion density and macula cube volume was $r_s=0.21$ ($p=0.11$). For vessel density, the correlation coefficients were 0.17 ($p=0.20$) and 0.07 ($p=0.60$).

For the schizophrenia group alone, the pattern was similar. The correlation between perfusion density and macula CSF thickness for the left eye was $r_s=0.44$ ($p=0.037$), and between perfusion density and macula cube volume was $r_s=0.60$ ($p=0.002$). For vessel density, the correlation coefficients were 0.50 ($p=0.016$) and 0.60 ($p=0.002$). For the right eye, the correlation between perfusion density and macula CSF thickness was $r_s=0.32$ ($p=0.13$), and between perfusion density and macula cube volume was $r_s=0.16$ ($p=0.46$). For vessel density, the correlation coefficients were 0.28 ($p=0.19$) and 0.08 ($p=0.71$).

OCTA measurements were also associated with RNFL thickness values. For the sample as a whole, left eye RNFL thickness was associated with greater left eye perfusion density, $r_s=0.41$ ($p=0.001$) and greater left eye vessel density, $r_s=0.42$ ($p=0.001$). For the right eye, RNFL thickness was related to greater perfusion density at a trend level, $r_s=0.25$ ($p=0.06$) after removing one outlier (without outlier removal the correlation coefficient was 0.29 ($p=0.03$)). The correlation between RNFL thickness and right eye vessel density was 0.14 ($p=0.28$).

For the schizophrenia group, left eye RNFL thickness was associated with greater perfusion density, $r_s=0.49$ ($p=0.02$) and greater vessel density, $r_s=0.56$ ($p=0.01$). For the right eye, the correlation between perfusion density and RNFL thickness was $r_s=0.10$ ($p=0.66$), and between right eye vessel density and RNFL thickness was $r_s=-0.09$ ($p=0.69$).

Relationships Between OCTA Measures, Antipsychotic Medication Dose, and Duration of Illness

CPZ equivalent dose of antipsychotic medication was not significantly associated with any of the four primary OCTA variables: left eye perfusion density, $r_s=0.10$ ($p=0.70$); left eye vessel density, $r_s=0.004$ ($p=0.99$); right eye perfusion density, $r_s=-0.04$ ($p=0.88$), right eye vessel density, $r_s=-0.005$ ($p=0.98$), or with left or right FAZ size

($r_s=0.21$ and -0.19 , $p=0.21$ and 0.42 , respectively). These OCTA variables were also unrelated to age at first hospitalization or self-reported age of the appearance of the first psychotic symptom. Higher correlations were observed, for the left eye data only, with the variable “current age minus age at first hospitalization”, which can be considered a measure of duration of fully-developed illness. These tests were all in the direction of a longer duration of illness being associated with reduced densities; however, none of them reached statistical significance: left eye perfusion density, $r_s=-0.41$ ($p=0.08$), left vessel density, $r_s=-0.35$ ($p=0.14$), right perfusion density, $r_s=-0.01$ ($p=0.95$), right eye vessel density, $r_s=-0.05$ ($p=0.83$), left FAZ size, $r_s=-0.05$ ($p=0.84$), and right FAZ size, $r_s=-0.23$ ($p=0.35$).

Relationships Between OCTA Measures and WTAR Scores

For the sample as a whole, there were multiple significant relationships between OCTA indices and WTAR scores, indicating that reduced vasculature was associated with lower WTAR scores: left perfusion density, $r_s=0.31$ ($p=0.02$), left vessel density, $r_s=0.41$ ($p=0.002$), right perfusion density, $r_s=0.36$ ($p=0.005$), right vessel density, $r_s=0.29$ ($p=0.03$), left FAZ size, $r_s=-0.29$ ($p=0.029$), and right FAZ size, $r_s=-0.25$ ($p=0.055$). For the schizophrenia participants alone, however, while some of the correlation values were similar, none of the correlations were statistically significant (all r_s values <0.33 ; all p -values >0.12), due in some cases to lack of power.

Inter-Ocular Comparisons

As a quality control check, left and right eye data were compared (across the sample as a whole). These analyses indicated no differences between the left and right eyes on perfusion density ($t(51)=0.43$, $p=0.67$), vessel density ($t(51)=0.60$, $p=0.55$), FAZ size ($t(50)=-0.60$, $p=0.55$), or OCTA signal strength ($t(53)=-1.00$, $p=0.32$).

Discussion

The main findings from this study were that: 1) schizophrenia patients demonstrated retinal microvasculature alterations, in both perfusion and vessel density, and in the size of the FAZ; 2) microvascular abnormalities were generally associated with thinning of retinal neural (macular and peripapillary RNFL) tissue, but the data were stronger for the left than the right eye; 3) among the

total sample, retinal microvasculature integrity was positively associated with scores on a proxy measure of verbal IQ; and 4) OCTA findings in patients were not significantly related to length of illness or medication dose, although some of the correlation coefficients with the former variable were of a sufficient magnitude that this issue warrants further investigation in a larger sample and one with a larger age range.

Overall, these findings are consistent with the proposal that schizophrenia involves microvascular dysfunction,² and that there are significant vascular-ischemic effects of the disorder.^{5,6} The mechanisms involved in this remain unclear, however. One hypothesis is that neuroinflammatory processes cause vascular abnormalities which eventually lead to changes in neuronal function and, eventually, volume.⁶ An alternative explanation is that retinal microvasculature reduction is secondary to excitotoxicity. Evidence for this is that retinal microvasculature abnormalities, and thinning of macula layers, have been linked to excessive glutamate due to reductions in the glutamate/aspartate transporter in a mouse model of schizophrenia (GLAST-/- mice).⁴⁰ Further work is needed to clarify the relative timing of microvascular versus neural tissue loss in the retina, and the mechanisms involved, in schizophrenia.

The relationship between reduced retinal microvasculature and lower WTAR scores is consistent with data indicating that retinal venule width in adults is negatively associated with neuropsychological test scores, subjective appraisal of cognitive functioning, and IQ scores from childhood testing.⁴¹ A more recent study in children also observed that abnormal retinal microvasculature (specifically, reduced width of arterioles) was related to lower IQ and to specific aspects of cognitive impairment.⁴²

This study had several limitations. One is the small sample size. A second is that we report data here only from the superficial retinal layer, and it is possible that deep retinal layer findings might differ (see four paragraphs below). We also focused on the 3×3 mm² region centered on the FAZ. It is possible that different findings might be obtained from larger total areas or from outer rings of the macula. A fourth issue is that the order of testing of eyes was not counterbalanced. This could have caused differences between the first (right) and second (left) eyes tested in level of dryness (from having kept the left eye open during initial testing of the right eye due to the requirement to not blink during scanning). Arguing against this, however, is that neither signal strength, nor

any of the primary OCTA values (ie, perfusion density, vessel density, FAZ size) differed between left and right eyes. Visual inspection of the included images also did not reveal evidence of differences in the amount of dry eye or blink artifact, which typically have characteristic effects on OCTA images,⁴³ between left and right eyes. Also, it is not clear why left eye data would be more affected by this factor in the schizophrenia group than in the control group, especially since: 1) there is some, albeit inconsistent, evidence that people with schizophrenia blink more often than people without schizophrenia,^{44,45} and 2) while a reduced blink rate can be associated with Parkinsonian side-effects from (typically) high doses of antipsychotic medication, this relationship is weak,⁴⁶ and we found no evidence of a relationship between OCTA data and CPZ equivalent medication dose in this sample. On the other hand, patients with schizophrenia were more likely to have OCT angiograms not analyzed due to artifacts in this study, which was likely related to excessive movement or dryer eyes. It is therefore possible that subtler artifacts that could not be detected when reading the images nevertheless led to lower density values in patients. In future studies, this potential confound can be mitigated by counterbalancing the order of testing across eyes, and by using artificial tears in each eye prior to scanning each eye to match eyes on dryness level. A fifth limitation of the study is that we did not record data on certain variables on which the groups may have differed, and that are known to affect retinal health and OCT data.^{7,26} The most important of these are smoking and body mass index, since people with schizophrenia generally smoke at a higher rate than people in the general population,^{47,48} and also are more likely to be overweight due to a combination of factors,^{4,49} including sedentary lifestyle and antipsychotic medication-induced weight gain. It will be important in future studies to determine the contributions of these factors to OCTA findings in schizophrenia. Schizophrenia is also associated with increases in diabetes and hypertension,^{4,50,51} which negatively affect retinal health, but these factors were not an issue in this study as potential participants with those diseases, or a range of other systemic or ophthalmological conditions were excluded from the study.

An additional limitation of the study is that the groups were not matched on education or race. While differences in education between schizophrenia and control groups are to be expected,⁵² the finding that the groups did not differ on maternal or paternal education suggests that group differences in WTAR scores did not reflect differences in

parental/inherited intelligence. However, the significant difference between groups in white vs non-white racial status indicates that clarification is needed regarding the relative contributions of schizophrenia vs interpersonal and medical history factors (eg, history of discrimination and social defeat experiences, quality of health care over the lifetime, etc.) in interpreting the results. This is a complex issue because schizophrenia is not independent of social disadvantage, and there is evidence that the latter set of factors can contribute to the development of schizophrenia,^{53–55} but also to cardiovascular disease.⁵⁶ Nevertheless, it will be important to better match groups on race in future studies to begin to determine the relative extents to which social (eg, discrimination) and medical factors that can affect retinal health (eg, diabetes, which is over-represented in schizophrenia and in non-white samples), and a diagnosis of schizophrenia itself are driving the microvasculature effects. In this study, it was notable that our post-hoc analyses did not reveal a pattern of white versus non-white differences on any of the OCTA variables. This suggests that, while social and medical factors are known to contribute to vascular changes, it is also likely that schizophrenia is associated with vascular changes, especially given the number of studies that have now observed this (outside of the retina).

Prior research has found that increased age is associated with reduced retinal vessel density,⁵⁷ but we did not observe differences between younger and older subgroups of patients and controls in this study. However, in the study by Wei et al.⁵⁷ it was only people age 65 and over who were significantly different from the young adult group on retinal vessel density, and our older subgroups averaged well below age 65 (see Table 1 note). In future studies it would be important to determine if aging and schizophrenia interact to further accelerate retinal microvasculature loss in older (>65) patients, as is the case for cerebral hypoperfusion.⁵⁸

A potentially important finding from this study is that the first episode and later episode schizophrenia groups did not differ on OCTA findings. This is in contrast to our earlier OCT study of retinal neural layer thickness in the same sample,²⁴ in which first episode patients' findings were within normal limits, whereas later episode patients demonstrated clear evidence of thinning at the macula. Because this study was not powered to detect small between-group differences, it is possible that a larger study would reveal subtle differences between these groups. On the other hand, our findings may reflect that vascular changes occur earlier than

neural changes in the retina for patients with schizophrenia. This view is consistent with the hypothesis that schizophrenia involves a sequence of changes that begins with neuroinflammation, which causes vascular impairments, finally leading to changes in neuronal function and structure.^{5,6} It remains to be seen whether OCTA findings might be indicators for anti-inflammatory or other specific intervention early in the course of schizophrenia, but this is an intriguing possibility for future investigation.

To our knowledge, this is the first paper describing OCTA findings in schizophrenia. However, findings from three earlier studies have been published in abstract form, and it is important to interpret our findings within the context of those studies. One study with 19 schizophrenia patients and eight controls found reduced superficial layer perfusion and vessel densities, and, interestingly, observed increased perfusion densities in the deep retinal layer.⁵⁹ Another study of 39 schizophrenia patients and 27 controls found reduced superficial layer perfusion density in the peripapillary region, but increased vessel density in the central macular region in the superficial layer.⁶⁰ A third study of 24 schizophrenia patients and 16 controls found no change in perfusion or vessel density in schizophrenia, but observed wider vessel diameters in the patient group.⁶¹ Without availability of further information about these studies, it is not possible to reconcile their different findings, or our findings with theirs. Importantly, however, increases or decreases in retinal vessel density have been reported in multiple sclerosis, and these differences may be due to methodological differences in how density is calculated, in addition to differences due to illness severity and stage.⁶² Regarding the latter, one possibility is that loss of microvasculature leads to hypoxia,⁶³ which is followed by a compensatory increase in levels of vascular endothelial growth factor (VEGF), adenosine, and other angiogenic factors,^{64–66} which, under certain conditions, can lead to non-permanent increases in vascular density that exceed normal levels.^{62,67} Whether this process occurs in the retina in schizophrenia, or in some patients at certain points in the illness, and whether overcompensation becomes impossible at other points, is not known at present. Too few OCTA studies have been done in schizophrenia as of yet to predict which factors are associated with the direction (ie, increase vs decrease) or specific location of retinal blood vessel changes. This situation is similar in some ways to data from conventional OCT in schizophrenia, where different studies have found thinning in different neural layers, and in the peripapillary retinal nerve fiber layer or macula or both, while some studies have reported normal findings.²⁶ The

reasons for these differences are not entirely clear but are likely to involve heterogeneity within schizophrenia in terms of neurodevelopment and illness progression as well as genetic and other biological factors (eg, short- and long-term effects of neuroinflammation), and these need to be investigated in OCTA studies of schizophrenia as well. What is clear, however, is that schizophrenia appears to be associated with retinal microvascular abnormalities, and that the location (center, periphery) and layer (superficial, deep) of these changes can vary across patients.

If the findings from this study are replicated, they would provide further evidence that indices of retinal abnormalities are biomarkers of brain disease. Consistent with OCTA detecting changes in a range of neurological disorders,¹¹ it was recently shown that OCTA data predict brain vasculature changes in cerebral small vessel disease.¹⁹ OCTA may therefore have utility as a screening tool for cerebral hypoperfusion, which is a risk factor for dementia,^{68,69} but is also found in schizophrenia,⁵⁸ even at first episode.⁷⁰ Cerebral hypoperfusion is more common in older schizophrenia patients, however, where it worsens at a greater rate than expected from normal aging.⁵⁸ If such cerebral vascular changes are found to contribute to the strikingly increased rates of early and late dementia diagnoses in people with schizophrenia,⁷¹ OCTA could be an expedient and non-invasive method for monitoring neurovascular degeneration and cognitive decline in schizophrenia and other conditions associated with microvasculature changes, including atrophy over time.

Acknowledgments

We thank Mary Durbin at Carl Zeiss Meditec, Inc., for generating the OCT angiograms and density values using the AngioPlex MetrixTM software package. We also thank Judy Thompson for her helpful critiques and edits of an earlier version of the manuscript. This work was funded by internal funds from Rutgers University, and by the New York Fund for Research in Innovation and Scientific Talent (NYFIRST).

Disclosure

The authors report no conflicts of interest regarding this work.

References

- Bleuler E. *Dementia Praecox or the Group of Schizophrenias*. New York: International Universities Press; 1950.
- Vetter MW, Martin BJ, Fung M, Pajevic M, Anderson TJ, Riedler TJ. Microvascular dysfunction in schizophrenia: a Case-Control Study. *NPJ Schizophr*. 2015;1(1):15023. doi:10.1038/npjpsch.2015.23
- Meier MH, Shalev I, Moffitt TE, et al. Microvascular abnormality in schizophrenia as shown by retinal imaging. *Am J Psychiatry*. 2013;170(12):1451–1459. doi:10.1176/appi.ajp.2013.13020234
- Correll CU, Robinson DG, Schooler NR, et al. Cardiometabolic risk in patients with first-episode schizophrenia spectrum disorders: baseline results from the RAISE-ETP Study. *JAMA Psychiatry*. 2014;71(12):1350–1363. doi:10.1001/jamapsychiatry.2014.1314
- Moises HW, Wollschlaeger D, Binder H. Functional genomics indicate that schizophrenia may be an adult vascular-ischemic disorder. *Transl Psychiatry*. 2015;5(8):e616. doi:10.1038/tp.2015.103
- Hanson DR, Gottesman II. Theories of schizophrenia: a genetic-inflammatory-vascular synthesis. *BMC Med Genet*. 2005;6(1):7. doi:10.1186/1471-2350-6-7
- Silverstein S, Demmin D, Schallek JB, Fradkin SI. Measures of retinal structure and function as biomarkers in neurology and psychiatry. *Biomark Neuropsychiatry*. 2020;2:100018.
- Wagner S, Fu D, Faes L, et al. Insights into systemic disease through retinal imaging-based oculosomics. *Trans Vis Sci Tech*. 2020;9(2):6. doi:10.1167/tvst.9.2.6
- Rifai OM, McGrory S, Robbins CB, et al. The application of optical coherence tomography angiography in Alzheimer's disease: a systematic review. *Alzheimers Dement (Amst)*. 2021;13(1):e12149. doi:10.1002/dad2.12149
- Ulusoy MO, Horasanli B, Isik-Ulusoy S. Optical coherence tomography angiography findings of multiple sclerosis with or without optic neuritis. *Neurol Res*. 2020;42(4):319–326. doi:10.1080/01616412.2020.1726585
- Tsokolas G, Tsaousis KT, Diakonis VF, Matsou A, Tyradellis S. Optical coherence tomography angiography in neurodegenerative diseases: a review. *Eye Brain*. 2020;12:73–87. doi:10.2147/EB.S193026
- Choi W. Imaging motion: a comprehensive review of optical coherence tomography angiography. *Adv Exp Med Biol*. 2021;1310:343–365.
- Spaide RF, Fujimoto JG, Waheed NK, Sadda SR, Staurengi G. Optical coherence tomography angiography. *Prog Retin Eye Res*. 2018;64:1–55.
- Kashani AH, Chen CL, Gahm JK, et al. Optical coherence tomography angiography: a comprehensive review of current methods and clinical applications. *Prog Retin Eye Res*. 2017;60:66–100.
- Ang M, Tan ACS, Cheung CMG, et al. Optical coherence tomography angiography: a review of current and future clinical applications. *Graefes Arch Clin Exp Ophthalmol*. 2018;256(2):237–245. doi:10.1007/s00417-017-3896-2
- Tan ACS, Tan GS, Denniston AK, et al. An overview of the clinical applications of optical coherence tomography angiography. *Eye*. 2018;32(2):262–286. doi:10.1038/eye.2017.181
- Spaide RF, Klancnik JM Jr, Cooney MJ. Retinal vascular layers imaged by fluorescein angiography and optical coherence tomography angiography. *JAMA Ophthalmol*. 2015;133(1):45–50. doi:10.1001/jamaophthalmol.2014.3616
- Chalam KV, Sambhav K. Optical coherence tomography angiography in retinal diseases. *J Ophthalmic Vis Res*. 2016;11(1):84–92. doi:10.4103/2008-322X.180709
- Lee JY, Kim JP, Jang H, et al. Optical coherence tomography angiography as a potential screening tool for cerebral small vessel diseases. *Alzheimers Res Ther*. 2020;12(1):73. doi:10.1186/s13195-020-00638-x
- Appaji A, Nagendra B, Chako DM, et al. Retinal vascular abnormalities in schizophrenia and bipolar disorder: a window to the brain. *Bipolar Disord*. 2019;21(7):634–641. doi:10.1111/bdi.12779

21. Appaji A, Nagendra B, Chako DM, et al. Retinal vascular fractal dimension in bipolar disorder and schizophrenia. *J Affect Disord*. 2019;259:98–103. doi:10.1016/j.jad.2019.08.061
22. Appaji A, Nagendra B, Chako DM, et al. Examination of retinal vascular trajectory in schizophrenia and bipolar disorder. *Psychiatry Clin Neurosci*. 2019;73(12):738–744. doi:10.1111/pcn.12921
23. Silverstein SM, Paterno D, Cherneski L, Green S. Optical coherence tomography indices of structural retinal pathology in schizophrenia. *Psychol Med*. 2018;48(12):2023–2033. doi:10.1017/S0033291717003555
24. Lai A, Crosta C, Silverstein S, Silverstein SM. Retinal structural alterations in chronic vs. first episode schizophrenia. *Biomark Neuropsychiatry*. 2020;2:100013. doi:10.1016/j.bionps.2020.100013
25. Jerotic S, Ristic I, Pejovic S, et al. Retinal structural abnormalities in young adults with psychosis spectrum disorders. *Prog Neuropsychopharmacol Biol Psychiatry*. 2020;98:109825. doi:10.1016/j.pnpbp.2019.109825
26. Silverstein SM, Fradkin SI, Demmin DL. Schizophrenia and the retina: towards a 2020 perspective. *Schizophr Res*. 2020;219:84–94. doi:10.1016/j.schres.2019.09.016
27. Adams SA, Nasrallah HA. Multiple retinal anomalies in schizophrenia. *Schizophr Res*. 2018;195:3–12. doi:10.1016/j.schres.2017.07.018
28. Kazakos CT, Karageorgiou V. Retinal changes in schizophrenia: a systematic review and meta-analysis based on individual participant data. *Schizophr Bull*. 2020;46(1):27–42. doi:10.1093/schbul/sbz106
29. Lizano P, Bannai D, Lutz O, Kim LA, Miller J, Keshavan M. A meta-analysis of retinal cytoarchitectural abnormalities in schizophrenia and bipolar disorder. *Schizophr Bull*. 2020;46(1):43–53. doi:10.1093/schbul/sbz029
30. Hébert M, Gagne AM, Paradis ME, et al. Retinal response to light in young nonaffected offspring at high genetic risk of neuropsychiatric brain disorders. *Biol Psychiatry*. 2010;67(3):270–274. doi:10.1016/j.biopsych.2009.08.016
31. Gagne AM, Moreau I, St-Amour I, Marquet P, Maziade M. Retinal function anomalies in young offspring at genetic risk of schizophrenia and mood disorder: the meaning for the illness pathophysiology. *Schizophr Res*. 2020;219:19–24. doi:10.1016/j.schres.2019.06.021
32. Maziade M, Silverstein SM. The place of the retina in psychiatry: uniting neurobiological and neurodevelopmental research with clinical research in psychiatric disorders. *Schizophr Res*. 2020;219:1–4. doi:10.1016/j.schres.2020.03.028
33. Leucht S, Samara M, Heres S, Davis JM. Dose equivalents for antipsychotic drugs: the DDD method. *Schizophr Bull*. 2016;42 (Suppl 1):S90–94. doi:10.1093/schbul/sbv167
34. Wechsler D. *Wechsler Test of Adult Reading: WTAR*. Psychological Corporation; 2001.
35. Bright P, van der Linde I. Comparison of methods for estimating premorbid intelligence. *Neuropsychol Rehabil*. 2020;30(1):1–14. doi:10.1080/09602011.2018.1445650
36. Durbin MK, An L, Shemonski ND, et al. Quantification of retinal microvascular density in optical coherence tomographic angiography images in diabetic retinopathy. *JAMA Ophthalmol*. 2017;135 (4):370–376. doi:10.1001/jamaophthalmol.2017.0080
37. Lim HB, Kim YW, Kim JM, Jo YJ, Kim JY. The importance of signal strength in quantitative assessment of retinal vessel density using optical coherence tomography angiography. *Sci Rep*. 2018;8 (1):12897. doi:10.1038/s41598-018-31321-9
38. Carl Zeiss Meditec I. *Cirrus HD-OCT User Manual - Models 500, 5000*. Dublin, Ireland; 2015.
39. Folio LS, Wollstein G, Ishikawa H, et al. Variation in optical coherence tomography signal quality as an indicator of retinal nerve fibre layer segmentation error. *Br J Ophthalmol*. 2012;96(4):514–518. doi:10.1136/bjophthalmol-2011-300044
40. Gonome T, Xie Y, Arai S, et al. Excess glutamate may cause dilation of retinal blood vessels in glutamate/aspartate transporter-deficient mice. *Biomed Res Int*. 2019;2019:6512195. doi:10.1155/2019/6512195
41. Shalev I, Moffitt TE, Wong TY, et al. Retinal vessel caliber and lifelong neuropsychological functioning: retinal imaging as an investigative tool for cognitive epidemiology. *Psychol Sci*. 2013;24 (7):1198–1207. doi:10.1177/0956797612470959
42. Wei FF, Raaijmakers A, Zhang ZY, et al. Association between cognition and the retinal microvasculature in 11-year old children born preterm or at term. *Early Hum Dev*. 2018;118:1–7. doi:10.1016/j.earlhumdev.2018.01.018
43. Hsu S, Vajzovic L. Identifying artifacts in OCT angiography. In: Toth CA, Ong SS, editors. *Handbook of Pediatric Retinal OCT and the Eye-Brain Connection*. Philadelphia: Elsevier; 2020:45–54.
44. Karson CN, Dykman RA, Paige SR. Blink rates in schizophrenia. *Schizophr Bull*. 1990;16(2):345–354. doi:10.1093/schbul/16.2.345
45. McGovern JE, Masucci MD, Le TP, Cohen AS. The (b)link between amotivation and psychosis: insights through phasic eye blink rate. *Psychiatry Res*. 2020;294:113490. doi:10.1016/j.psychres.2020.113490
46. Mentzel CL, Bakker PR, van Os J, et al. Blink rate is associated with drug-induced parkinsonism in patients with severe mental illness, but does not meet requirements to serve as a clinical test: the Curacao extrapyramidal syndromes study XIII. *J Negat Results Biomed*. 2017;16(1):15. doi:10.1186/s12952-017-0079-y
47. Williams JM, Gandhi KK. Use of caffeine and nicotine in people with schizophrenia. *Curr Drug Abuse Rev*. 2008;1(2):155–161. doi:10.2174/1874473710801020155
48. de Leon J, Diaz FJ. A meta-analysis of worldwide studies demonstrates an association between schizophrenia and tobacco smoking behaviors. *Schizophr Res*. 2005;76(2–3):135–157. doi:10.1016/j.schres.2005.02.010
49. McDaid TM, Smyth S. Metabolic abnormalities among people diagnosed with schizophrenia: a literature review and implications for mental health nurses. *J Psychiatr Ment Health Nurs*. 2015;22 (3):157–170. doi:10.1111/jpm.12185
50. Bernardo M, Canas F, Banegas JR, et al. Prevalence and awareness of cardiovascular risk factors in patients with schizophrenia: a Cross-Sectional Study in a low cardiovascular disease risk geographical area. *Eur Psychiatry*. 2009;24(7):431–441. doi:10.1016/j.eurpsy.2009.07.010
51. Hoffman RP. The complex inter-relationship between diabetes and schizophrenia. *Curr Diabetes Rev*. 2017;13(3):528–532. doi:10.2174/1573399812666161201205322
52. Hakulinen C, McGrath JJ, Timmerman A, et al. The association between early-onset schizophrenia with employment, income, education, and cohabitation status: Nationwide Study with 35 years of follow-up. *Soc Psychiatry Psychiatr Epidemiol*. 2019;54 (11):1343–1351. doi:10.1007/s00127-019-01756-0
53. Davis J, Eyre H, Jacka FN, et al. A review of vulnerability and risks for schizophrenia: beyond the two hit hypothesis. *Neurosci Biobehav Rev*. 2016;65:185–194. doi:10.1016/j.neubiorev.2016.03.017
54. Selten JP, Boonij J, Buwalda B, Meyer-Lindenberg A. Biological mechanisms whereby social exclusion may contribute to the etiology of psychosis: a narrative review. *Schizophr Bull*. 2017;43:287–292.
55. Selten JP, van der Ven E, Rutten BP, Cantor-Graae E. The social defeat hypothesis of schizophrenia: an update. *Schizophr Bull*. 2013;39(6):1180–1186. doi:10.1093/schbul/sbt134
56. Powell-Wiley TM, Dey AK, Rivers JP, et al. Chronic stress-related neural activity associates with subclinical cardiovascular disease in a community-based cohort: data from the Washington, D. C. cardiovascular health and needs assessment. *Front Cardiovasc Med*. 2021;8:599341. doi:10.3389/fcvm.2021.599341
57. Wei Y, Jiang H, Shi Y, et al. Age-related alterations in the retinal microvasculature, microcirculation, and microstructure. *Invest Ophthalmol Vis Sci*. 2017;58(9):3804–3817. doi:10.1167/iiov.17-21460
58. Kawakami K, Wake R, Miyaoka T, Furuya M, Liaury K, Horiguchi J. The effects of aging on changes in regional cerebral blood flow in schizophrenia. *Neuropsychobiology*. 2014;69(4):202–209. doi:10.1159/000358840

59. Kasetty M, Lizano P, Zeng R, et al. A pilot study of chorioretinal structural and vascular abnormalities in psychosis. *Psychiatry Res.* 2019.
60. Asanad S, Addis H, Chen S, et al. Retinal thickness and vascular pathology as ocular biomarkers for schizophrenia: morphometric analysis of the peripapillary and macular regions using OCT and OCTA in vivo. *Invest Ophthalmol Vis Sci.* 2020;61:5105.
61. Lizano P, Bannai D, Adnan I, et al. Superficial retinal vascular abnormalities in schizophrenia as shown by swept source OCT-angiography: a Preliminary Study. *Biol Psychiatry.* 2020;87(9):S445. doi:10.1016/j.biopsych.2020.02.1133
62. Jiang H, Gameiro GR, Liu Y, et al. Visual function and disability are associated with increased retinal volumetric vessel density in patients with multiple sclerosis. *Am J Ophthalmol.* 2020;213:34–45. doi:10.1016/j.ajo.2019.12.021
63. D'Haeseleer M, Cambron M, Vanopdenbosch L, De Keyser J. Vascular aspects of multiple sclerosis. *Lancet Neurol.* 2011;10(7):657–666. doi:10.1016/S1474-4422(11)70105-3
64. Lin Y, Jiang H, Liu Y, et al. Age-related alterations in retinal tissue perfusion and volumetric vessel density. *Invest Ophthalmol Vis Sci.* 2019;60(2):685–693. doi:10.1167/iops.18-25864
65. Adair TH, Cotten R, Gu JW, et al. Adenosine infusion increases plasma levels of VEGF in humans. *BMC Physiol.* 2005;5(1):10. doi:10.1186/1472-6793-5-10
66. Meininger CJ, Schelling ME, Granger HJ. Adenosine and hypoxia stimulate proliferation and migration of endothelial cells. *Am J Physiol.* 1988;255(3 Pt 2):H554–562. doi:10.1152/ajpheart.1988.255.3.H554
67. Wang X, Jia Y, Spain R, et al. Optical coherence tomography angiography of optic nerve head and parafovea in multiple sclerosis. *Br J Ophthalmol.* 2014;98(10):1368–1373. doi:10.1136/bjophthalmol-2013-304547
68. Wolters FJ, Zonneveld HI, Hofman A, et al. Cerebral perfusion and the risk of dementia: a population-based study. *Circulation.* 2017;136(8):719–728. doi:10.1161/CIRCULATIONAHA.117.027448
69. de la Torre JC. Cardiovascular risk factors promote brain hypoperfusion leading to cognitive decline and dementia. *Cardiovasc Psychiatry Neurol.* 2012;2012:367516. doi:10.1155/2012/367516
70. Wake R, Miyaoka T, Kawakami K, et al. Characteristic brain hypoperfusion by 99mTc-ECD single photon emission computed tomography (SPECT) in patients with the first-episode schizophrenia. *Eur Psychiatry.* 2010;25(6):361–365. doi:10.1016/j.eurpsy.2009.12.005
71. Stroup TS, Olfson M, Huang C, et al. Age-specific prevalence and incidence of dementia diagnoses among older US adults with schizophrenia. *JAMA Psychiatry.* 2021;78(6):632. doi:10.1001/jamapsychiatry.2021.0042

Eye and Brain

Publish your work in this journal

Eye and Brain is an international, peer-reviewed, open access journal focusing on clinical and experimental research in the field of neuro-ophthalmology. All aspects of patient care are addressed within the journal as well as basic research. Papers covering original research, basic science, clinical and epidemiological studies, reviews and

Submit your manuscript here: <https://www.dovepress.com/eye-and-brain-journal>

Dovepress

evaluations, guidelines, expert opinion and commentary, case reports and extended reports are welcome. The manuscript management system is completely online and includes a very quick and fair peer-review system, which is all easy to use. Visit <http://www.dovepress.com/testimonials.php> to read real quotes from published authors.