

Neurofibromatosis Type I and Hypospadias in a Male 46, XY with a Mutation in the *NF1* Gene and a Mutation in *NR5A1*

Lina Perafan-Valdes^{1,2}, Sebastian Giraldo-Ocampo³, Juliana Lores², Harry Pachajoa^{2,4}

¹Universidad Libre, Programa de Maestría en Epidemiología, Cali, Colombia; ²Fundación Valle del Lili, Genetics Division, Cali, Colombia; ³Universidad del Valle, Departamento de Microbiología, Cali, Colombia; ⁴Universidad Icesi, Centro de Investigaciones en Anomalías Congénitas y Enfermedades Raras (CIACER), Cali, Colombia

Correspondence: Harry Pachajoa, Fundación Valle del Lili, Genetics Division, Carrera 98 # 18-49, Cali, Colombia, Tel +57 5552334 ext 7653, Email hmpachajoa@icesi.edu.co

Abstract: Neurofibromatosis type 1 is one of the most common genetic autosomal dominant disorders described, with a prevalence of 1 in 2000 to 1 in 3000 individuals. It is characterized by skin, nerves, and bone abnormalities. Non-related to NF1, hypospadias is a displacement in the urethral opening which in the majority of patients has an idiopathic cause. Here, we describe a patient with neurofibromatosis type 1, hypospadias, and unilateral cryptorchidism. The heterozygous variants c.6789_6792delTTAC, p. (Tyr2264Thrfs*5) and c.140A>G, p.(Tyr47Cys) were found in the *NF1* and *NR5A1* genes, respectively. This case contributes to the phenotypical characterization of patients with NF1 but also with hypospadias caused by a mutation in the *NR5A1* gene, which usually leads to severe sex disorders.

Keywords: tumor predisposition syndrome, cafe-au-lait macules, external genitalia development, Colombia

Introduction

Neurofibromatosis type 1 (NF1; OMIM 162200), a tumor predisposition syndrome,¹ is one of the most common dominant-inheritance genetic disorders with an estimated prevalence of 1 in 2000 to 1 in 3000 individuals.^{2,3} It is caused by mutations in the tumor-suppressor gene Neurofibromin 1 (NF1) located on chromosome 17, which encodes neurofibromin, a negative regulator of the Ras/MAPK signaling pathway.¹ NF1 patients are characterized by skin, nerve, and bone alterations that clinically are seen as cutaneous or plexiform benign Schwann cell tumors (neurofibromas), cafe-au-lait macules (CALMs), Lisch nodules, gliomas, scoliosis, and pseudoarthrosis.^{4,5} Currently, more than 2800 genetic variants, leading to NF1 have been identified in the *NF1* gene, the majority of which are loss-of-function mutations;⁴ about two-thirds of *NF1* variants are single-nucleotide substitutions, from which, the majority affects splicing (37%), truncate the protein (nonsense, 27%) or are frameshift variants (30%).⁶

On the other hand, hypospadias, a non-NF1 related abnormal external genitalia development, is one of the most common congenital anomalies in males with an approximate prevalence, in the United States, of 1 in 200 live births.⁷ This condition is defined by the incorrect position, displaced along the ventral side of the penis, of the urethral opening caused during embryogenesis.⁸ Depending on the position of the urethral opening, hypospadias can be classified as proximal/severe (30% of cases) or distal/minor (70% of cases) if it is located on the posterior or anterior part of the penis, respectively.⁹ This condition may occur as an isolated defect, develop with other genital disorders, or be associated with any of the more than 200 syndromes in which this condition has been described.⁹

Nevertheless, the genetic cause is only clearly identified in 30% of cases, which corresponds to a syndromic association. Isolated cases of hypospadias usually are idiopathic,^{8,9} however, variants in some genes have been reported to cause isolated or associated hypospadias such as *NR5A1*, *BMP4*, *BMP7*, *WT1*, *HOXA4*, *MAP3K1*, *MAMLD1*,

CYP11A1, *AKR1C3*, *SRD5A2*, and so on.⁹ Here we report a Colombian male patient (karyotype 46, XY) with NF1 with the variant c.6789_6792delTTAC, p.(Tyr2264Thrfs*5) in the *NF1* gene and hypospadias with the variant c.140A>G, p.(Tyr47Cys) in the *NR5A1* gene, the latter previously published in a patient with severe sex disorders.

Case Report

Ten-year-old male patient, first-born to non-related parents and delivered at term without complication. Both of his parents were aged 20 at the time of birth. Hypospadias was noticed at birth and was corrected at 14 months of age. Motor development was normal and the patient achieved all milestones except crawling. Language development was also normal. His mother had scoliosis but not CALMs; his father and brother did not have CALMs either. No other family history was reported.

At five years old, the patient was diagnosed with thoracolumbar scoliosis. Thoracic and lumbar curves were flexible and the Cobb angle was 14° and 23°, respectively. At six years old, he was diagnosed with neurofibromatosis type 1 due to CALMs, freckling and neurofibromas. Magnetic resonance (MRI) of the spine revealed a lobulated mass in the right L1-L2 neuroforamen, hyperintense on T2, and isointense on T1 compatible with a neurofibroma. Lower limbs panoramic radiography showed pelvic tilt. Ophthalmologic analysis revealed hyperopic astigmatism in both eyes and otorhinolaryngology tests were normal. Follow up at seven years old, through spine panoramic radiography, showed spine curve progression (thoracic and lumbar Cobb angle: 42° and 36°, respectively) with a sagittal vertical axis of 4 cm. Whole exome sequencing (WES) in trio was performed. Approximately 214,000 exons from all encoded sequences were enriched for consensus using genomic DNA fragments of >340,000 probes against the human genome. The sequencing was performed on the Illumina HiSeq 4000, with subsequent validation by Sanger sequencing identifying the heterozygous pathogenic (College of Medical Genetics and Genomics, ACMG criteria: pathogenic very strong, PVS1; pathogenic moderate, PM2; pathogenic supporting, PP5) variant c.6789_6792delTTAC, p.(Tyr2264Thrfs*5) in the *NF1* gene (OMIM: 613113); and the heterozygous probably pathogenic (ACMG criteria: pathogenic strong, PS3; PM1, PM2, PP2, PP3, PP5) variant c.140A>G, p.(Tyr47Cys) in the *NR5A1* gene (OMIM 184757).

These two variants were found in the patient and not in his parents and therefore, given that germline mosaicism is possible but infrequent, they were probably de novo variants. Subsequent G-banded karyotype was normal (46, XY). Protein interaction network performed in the STRING software (version 11.5) with *NF1* and genes associated with hypospadias mentioned above, revealed that NF1 protein does not interact with any of the proteins coded by the other genes and is unlikely that is causing the hypospadias. Furthermore, the protein coded by *NR5A1* interacts with the products of the other genes used in the analysis such as *WT1*, *CYP11A1*, and *HSD3B2* (Figure 1).

At eight years old, testicular ultrasound indicated unilateral left cryptorchidism. Total testosterone was 2.7 ng/dL, Somatomedin-C 119 ng/mL, and dehydroepiandrosterone (DHEA) 9.9 µg/dL. Thyroid-stimulating hormone (TSH) and free T4 were normal. Given the hypospadias, cryptorchidism, and low, although normal levels of testosterone, a low-dose regimen (200mg) of testosterone undecanoate annually was initiated. Follow-up spine panoramic radiography showed an increase in thoracic Cobb angle (49°) and decrease in lumbar angle (32°) and therefore, given the rapid progress of scoliosis, surgery correction (Shilla procedure) was performed.

Physical examination at the current age (10 years old) showed freckling in the axillary and inguinal regions, shawl and slightly hypoplastic scrotum (Figure 2) and more than one hundred CALMs ranging in size from 0.5 to 1.5 cm with a generalized distribution, including palms of the hands and the soles of the feet. Scoliosis has improved (thoracic Cobb angle of 35°), there have been no signs of hypertension, and a nuclear magnetic resonance of the brain revealed two benign tumoral lesions without an apparent mass effect; the proband has had no symptoms indicating central or peripheral nervous system involvement. Weight was 27 kg (9th percentile) and height was 140 cm (38th percentile). He is currently in neurosurgery, neurology, endocrinology, urology, and ophthalmology follow-up with no complications.

Discussion

Neurofibromatosis type 1 (NF1) is a relatively common genetic disorder characterized by alterations in the skin, nerves, and bone abnormalities. As a negative regulator of the Ras/MAPK signaling pathway, it is included in the set of disorders known as RASopathies that also include Noonan syndrome, Costello syndrome, Legius syndrome, Noonan syndrome with multiple

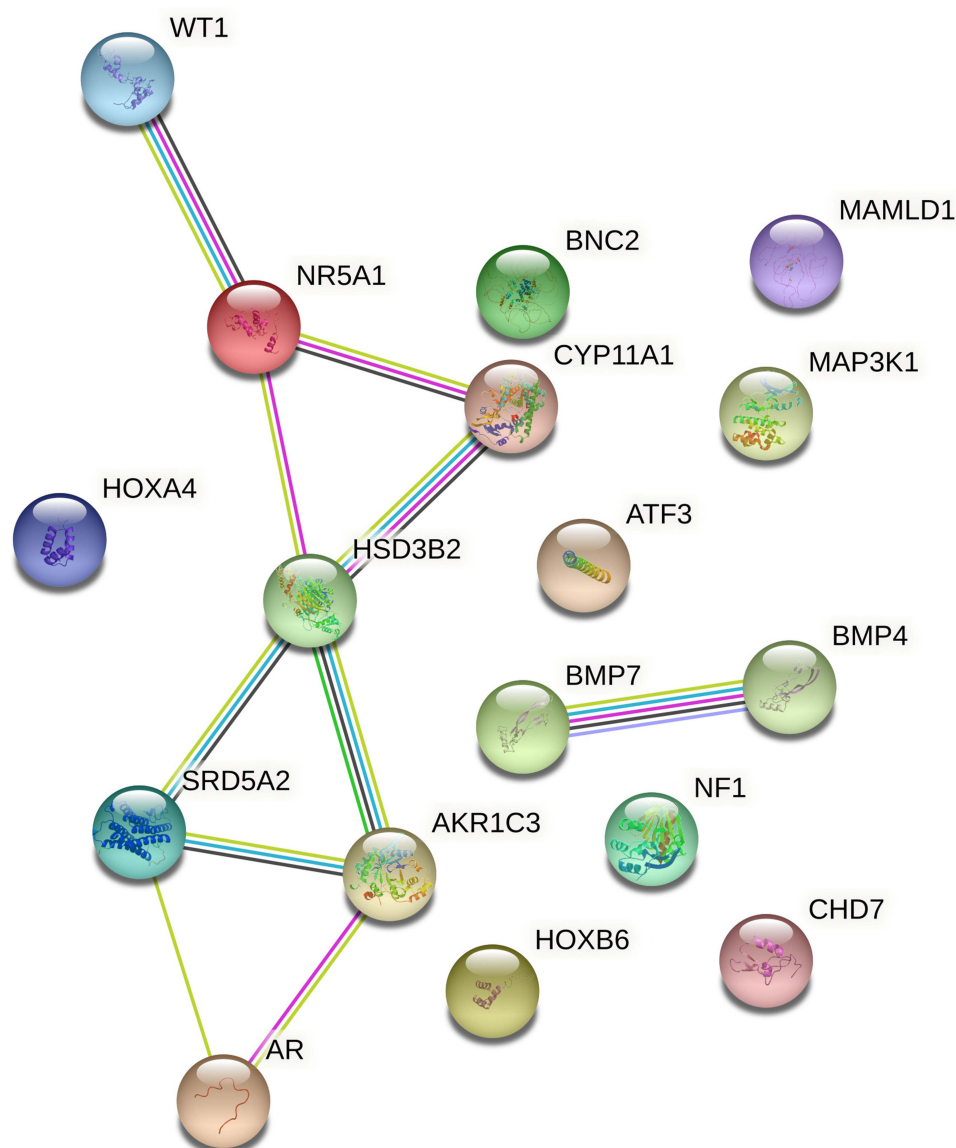


Figure 1 Functional protein association network using *NF1* gene and genes associated to hypospadias in the literature. Interaction score was set at high confidence (0.7). Color lines between two nodes/proteins indicate a known interaction between proteins (pink: from curated databases; blue: experimentally determined), co-expression (black) or a predicted interaction (light green: text mining).

lentigines, cardio-facio-cutaneous syndrome, capillary malformation–arteriovenous malformation syndrome and autosomal dominant intellectual disability type 5.¹⁰ This pathway is involved in regulating the cell cycle and cellular growth, cell differentiation, and senescence. Given that all of these disorders are caused by gain-of-function mutations in the same pathway, overlapping clinical features are frequent.¹¹ For instance, Legius syndrome, LEOPARD syndrome, and Noonan syndrome can present several overlapping features with *NF1*; however, these disorders are rarely confused with *NF1* due to the presence of characteristic symptoms such as neurofibromas and Lisch nodules.⁵ Our patient, given his age and the age-dependent clinical manifestations of the disease, which usually presents as milder or incomplete *NF1* phenotypes in young individuals, only had CALMs, freckling in the axillary and inguinal regions, which allowed the diagnosis of *NF1*,¹² and non-dystrophic thoracolumbar scoliosis. The former was the symptom that confirm, without genetic testing, the diagnosis of *NF1* as some cases with only CALMs and freckling might have another diagnosis like Legius syndrome.¹²

The genetic variant c.6789_6792delTTAC, p.(Tyr2264Thrfs*5) found in this patient causes a frameshift by deleting four nucleotides. It has been already reported in the ClinVar database and was first reported in 1995.¹³ Subsequent

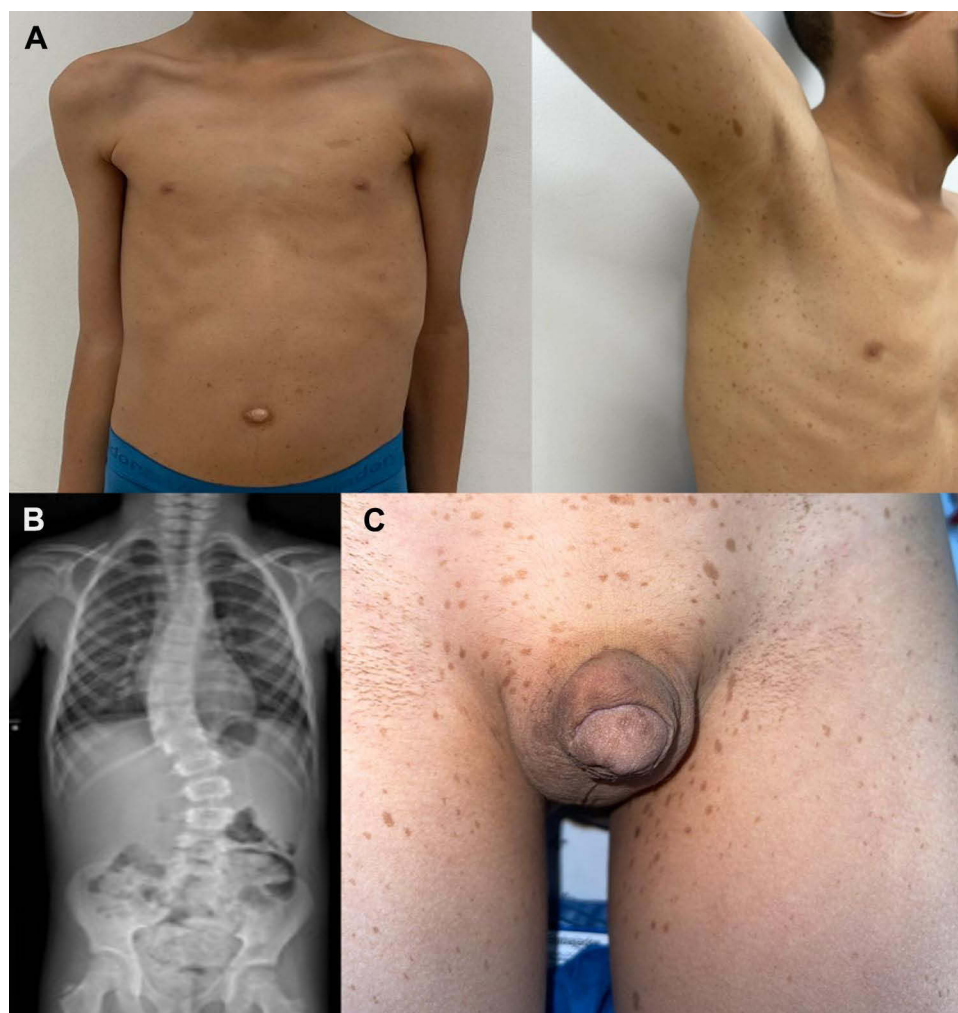


Figure 2 7-year-old patient. (A) Multiple cafe-au-lait macules in trunk and upper extremities, and axillary freckling. (B) Whole spine X-ray revealing thoracic scoliosis with right-sided curvature involving T7-T12, approximate angle of 42°, without spinal rotation. (C) Shawl and slightly hypoplastic scrotum and glandular hypospadias.

clinical case reports and studies have also identified this variant, however, some are newborns with only one NF1 clinical feature and some have additionally associated features, such as glomus tumors of the fingers and toes.^{14,15} Due to the clinical variability (even in patients with the same variant causing the disease) and the incomplete penetrance in young patients, data about genotype-phenotype correlation are crucial for possible complication forecast that allows proper monitoring of the disease and also highlights the importance of genetic testing in NF1 patients, even if they already fulfill the diagnosis of NF1 without genetic analysis. In this manner, this case provides data related to the range of clinical manifestations that patients with this specific variant might develop.

More interesting in this case, was the isolated, non-NF1 related, hypospadias in which its cause in more than half of patients is idiopathic.⁸ The variant c.140A>G (pTyr47Cys) found in the *NR5A1* gene changed a tyrosine to cysteine (missense) at 47 amino acid residue, and according to the guidelines of the College of Medical Genetics and Genomics ACMG¹⁶ is classified as probably pathogenic. This gene is expressed exclusively in the adrenal cortex and steroidogenic tissue. Its protein, named steroidogenic factor 1, is a transcription factor that is essential for sex determination and formation of the primary steroidogenic tissues;¹⁷ more specifically, it is involved in pituitary stem cells differentiation to the gonadotrope lineage, and mutations in this gene cause gonadotrope deficiency/impaired androgenization, leading ultimately to testosterone deficiency, disorders of cell development, with or without adrenal failure, and in females, can affect ovarian development and function.¹⁸ Some variants, however, have milder effects. For instance, *NR5A1* has been

explored in hypospadias with no other several sex development disorders.¹⁹ However, the identification of such variants and to which region of the gene correspond is not clearly known to date.

The variant reported here in the *NR5A1* gene has been reported three times: in the LOVD database as a VUS variant; in a patient with karyotype 46, XY with prenatal ultrasound diagnosis revealing female genitalia and, after birth, laparotomy showed inguinal testes in the upper part of the inguinal channel;²⁰ and in an unpublished young patient presented in the APAPU conference 2021 with sex disorders (not specified in the abstract) without adrenal dysfunction. This variant is located in the DNA-binding domain part of the protein and is predicted to affect the DNA-binding capacity of the protein it encoded given that the residue 47 is highly conserved between different species.²⁰ Given that this variant has previously been associated with sex disorders, the reported phenotypes of other variants in this gene, that our patient had altered adrenal function as measured by DHEA (9.9 µg/dL), although not total testosterone was altered, low-regimen testosterone was initiated. No sex development disorders or clinical manifestations aside from hypospadias and unilateral cryptorchidism have appeared in this young patient, which suggests that this variant has a milder phenotype and is associated specifically with hypospadias, at least in this proband, and therefore although only has been published once before, it seems other factors are influencing the clinical phenotypes seen in the carriers of these variants. Follow-up for future sex disorders is required in the patient.

Conclusion

Here we report a patient with NF1 with scoliosis, CALMs, and freckling in the axillary and inguinal regions, hypospadias, and unilateral cryptorchidism. The variants c.6789_6792delTTAC, p.(Tyr2264Thrfs*5) in the *NF1* gene and c.140A>G, p.(Tyr47Cys) in the *NR5A1* gene were found. This study contributes to the knowledge of the variability of clinical presentation of NF1 and the correlation with the variant described. Furthermore, we report a variant in the *NR5A1* gene, with a milder phenotype than described for other variants and even the same variant (although only published once), and is associated specifically with hypospadias in this proband, revealing clinical heterogeneity, although more patients with the variant are required to establish a genotype-phenotype correlation.

Abbreviations

NF1, neurofibromatosis type 1; *NF1* gene, gene encoding Neurofibromin 1; CALMs, cafe-au-lait macules.

Data Sharing Statement

The datasets used and/or analyzed during the current study are available from the corresponding author on reasonable request.

Ethics Approval and Informed Consent

This study was approved by the Ethics Committee of Fundación Valle del Lili, Colombia (human study protocol #1504) and performed in accordance with the Declaration of Helsinki. Written informed consent was obtained from the parents of the patient, including the consent for genetic testing. Information revealing the subject's identity was not included in the manuscript. The patient was identified by number and not by his real name.

Consent for Publication

Written informed consent for publication of clinical details and images/photographs was obtained from the parents of the patient.

Acknowledgments

The authors would like to thank the patient and his parents for agreeing to the publication of this report. We also thank the people who have contributed to the development and execution of this study.

Author Contributions

All authors made a significant contribution to the work reported, whether that is in the conception, study design, execution, acquisition of data, analysis and interpretation, or in all these areas; took part in drafting, revising or critically reviewing the manuscript; gave final approval of the version to be published; have agreed on the journal to which the article has been submitted; and agree to be accountable for all aspects of the work.

Funding

There is no funding to declare.

Disclosure

The authors have no conflicts of interest in relation to this work to declare.

References

1. Pasmant E, Vidaud M, Vidaud D, Wolkenstein P. Neurofibromatosis type 1: from genotype to phenotype. *J Med Genet*. 2012;49:483–489. doi:10.1136/jmedgenet-2012-100978
2. Williams VC, Lucas J, Babcock MA, Gutmann DH, Bruce B, Maria BL. Neurofibromatosis type 1 revisited. *Pediatrics*. 2009;123:124–133. doi:10.1542/peds.2007-3204
3. Kallionpää RA, Uusitalo E, Leppävirta J, Pöyhönen M, Peltonen S, Peltonen J. Prevalence of neurofibromatosis type 1 in the Finnish population. *Genet Med*. 2018;20:1082–1086. doi:10.1038/gim.2017.215
4. Wang W, Wei CJ, Cui XW, et al. Impacts of NF1 gene mutations and genetic modifiers in neurofibromatosis type 1. *Front Neurol*. 2021;12:1–12.
5. Jett K, Friedman JM. Clinical and genetic aspects of neurofibromatosis 1. *Genet Med*. 2010;12:1–11. doi:10.1097/GIM.0b013e3181bf15e3
6. Giugliano T, Santoro C, Torella A, et al. Clinical and genetic findings in children with neurofibromatosis type 1, legius syndrome, and other related neurocutaneous disorders. *Genes*. 2019;10:1–29. doi:10.3390/genes10080580
7. Mai CT, Isenburg J, Langlois PH, et al. Population-based birth defects data in the United States, 2008 to 2012: presentation of state-specific data and descriptive brief on variability of prevalence. *Birth Defects Res Part A*. 2015;103:972–993. doi:10.1002/bdra.23461
8. van der Horst HJR, de Wall LL. Hypospadias, all there is to know. *Eur J Pediatr*. 2017;176:435–441. doi:10.1007/s00431-017-2864-5
9. Bouty A, Ayers KL, Pask A, Heloury Y, Sinclair AH. The genetic and environmental factors underlying hypospadias. *Sex Dev*. 2015;9:239–259. doi:10.1159/000441988
10. Riller Q, Rieux-Laucat F. RASopathies: from germline mutations to somatic and multigenic diseases. *Biomed J*. 2021;44:422–432. doi:10.1016/j.bj.2021.06.004
11. Rauen KA. The RASopathies. *Annu Rev Genomics Hum Genet*. 2013;14:355–369. doi:10.1146/annurev-genom-091212-153523
12. Legius E, Messiaen L, Wolkenstein P, et al. Revised diagnostic criteria for neurofibromatosis type 1 and Legius syndrome: an international consensus recommendation. *Genet Med*. 2021;23:1506–1513. doi:10.1038/s41436-021-01170-5
13. Robinson PN, Böddrich A, Peters H, et al. Two recurrent nonsense mutations and a 4 bp deletion in a quasi-symmetric element in exon 37 of the NF1 gene. *Hum Genet*. 1995;96:95–98. doi:10.1007/BF00214193
14. Banerjee S, Lei D, Liang S, et al. Novel phenotypes of NF1 patients from unrelated Chinese families with tibial pseudarthrosis and anemia. *Oncotarget*. 2017;8:39695–39702. doi:10.18632/oncotarget.13932
15. Brems H, Park C, Maertens O, et al. Glomus tumors in neurofibromatosis type 1: genetic, functional, and clinical evidence of a novel association. *Cancer Res*. 2009;69:7393–7401. doi:10.1158/0008-5472.CAN-09-1752
16. Richards S, Aziz N, Bale S, et al. Standards and guidelines for the interpretation of sequence variants: a joint consensus recommendation of the American College of Medical Genetics and Genomics and the Association for Molecular Pathology. *Genet Med*. 2015;17:405–424. doi:10.1038/gim.2015.30
17. Pacini V, Petit F, Querat B, Laverrière JN, Cohen-Tannoudji J, L'Hôte D. Identification of a pituitary ERα-activated enhancer triggering the expression of Nr5a1, the earliest gonadotrope lineage-specific transcription factor. *Epigenetics Chromatin*. 2019;12:1–17. doi:10.1186/s13072-019-0291-8
18. Lourenço D, Brauner R, Lin L, et al. Mutations in NR5A1 associated with ovarian insufficiency. *N Engl J Med*. 2009;360:1200–1210. doi:10.1056/NEJMoa0806228
19. El-Khairi R, Achermann J. Steroidogenic factor-1 and human disease. *Semin Reprod Med*. 2012;30:374–381. doi:10.1055/s-0032-1324720
20. Rocca MS, Ortolano R, Menabò S, et al. Mutational and functional studies on NR5A1 gene in 46, XY disorders of sex development: identification of six novel loss of function mutations. *Fertil Steril*. 2018;109:1105–1113. doi:10.1016/j.fertnstert.2018.02.123

Pharmacogenomics and Personalized Medicine

Dovepress

Publish your work in this journal

Pharmacogenomics and Personalized Medicine is an international, peer-reviewed, open access journal characterizing the influence of genotype on pharmacology leading to the development of personalized treatment programs and individualized drug selection for improved safety, efficacy and sustainability. This journal is indexed on the American Chemical Society's Chemical Abstracts Service (CAS). The manuscript management system is completely online and includes a very quick and fair peer-review system, which is all easy to use. Visit <http://www.dovepress.com/testimonials.php> to read real quotes from published authors.

Submit your manuscript here: <https://www.dovepress.com/pharmacogenomics-and-personalized-medicine-journal>