

# Solitary Interdigital Condyloma Latum in a Female Adolescent: A Case Report of an Unusual Form of Secondary Syphilis

Cong You<sup>1</sup>, Kun Wang<sup>1</sup>, Mingyi Liao<sup>1</sup>, Luying Zhang<sup>1</sup>, Mintong He<sup>1</sup>, Xiaoying Ye<sup>1</sup>, Yongzhang Qin<sup>2</sup>, Tao Yang<sup>1</sup>

<sup>1</sup>Department of Dermatology and Venereology; Candidate Branch of National Clinical Research Centre for Skin and Immune Diseases, The First Affiliated Hospital of Gannan Medical University, Ganzhou, People's Republic of China; <sup>2</sup>Department of Endocrinology, The First Affiliated Hospital of Gannan Medical University, Ganzhou, People's Republic of China

Correspondence: Tao Yang, Department of Dermatology and Venereology, Candidate Branch of National Clinical Research Centre for Skin and Immune Diseases, The First Affiliated Hospital of Gannan Medical University, Ganzhou, People's Republic of China, Tel +8618720732351, Email danny20021068@sina.com

**Abstract:** Condylomata lata are flat-topped, moist papules or plaques usually found in the anogenital area as cutaneous manifestations of secondary syphilis. Here, we present a unique case of a solitary interdigital condyloma latum of secondary syphilis in a 16-year-old female sex worker without other cutaneous findings. Sexual contact history, histopathology, including direct detection of *Treponema pallidum*, and serological tests were essential for the diagnosis of this case. The patient reached serological cure with two doses of intramuscularly delivered penicillin G benzathine. Owing to the dramatic rise in the incidence of primary and secondary syphilis, medical workers should be aware of the atypical skin manifestations of secondary syphilis in adolescents who are at risk of acquiring sexually transmitted diseases to avoid the progression to late syphilis and further transmission to sexual partners.

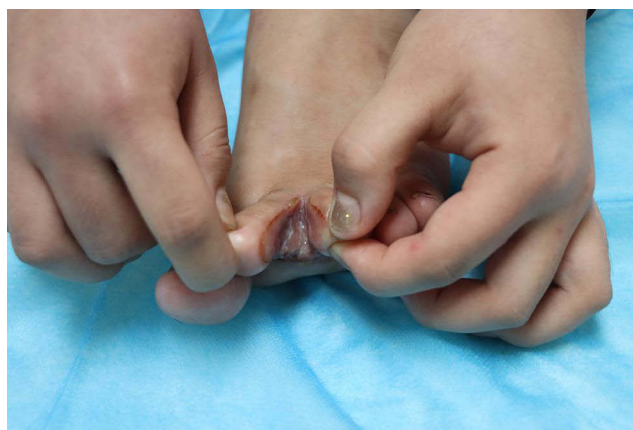
**Keywords:** interdigital condyloma latum, secondary syphilis, female adolescent

## Introduction

The incidence of syphilis in children and adolescents has gradually increased in recent years, with a significant relative annual change of 3.8%.<sup>1</sup> Incidences of both primary and secondary syphilis have also dramatically risen.<sup>2</sup> A variety of signs can be produced by secondary syphilis, and it was once considered “the great imitator”<sup>3</sup> due to the numerous types of skin lesions that could be attributed to secondary syphilis. The typical skin manifestation of secondary syphilis is a diffuse maculopapular rash.<sup>4</sup> Condylomata lata is another skin manifestation of flat-topped, moist papules or plaques that tend to develop in the anogenital area.<sup>5</sup> Condylomata lata can be the only manifestation of secondary syphilis and can be present in extragenital locations.<sup>6</sup> Here, we report a case of unusual secondary syphilis in an adolescent female sex worker who presented with a solitary condyloma latum on her toe web.

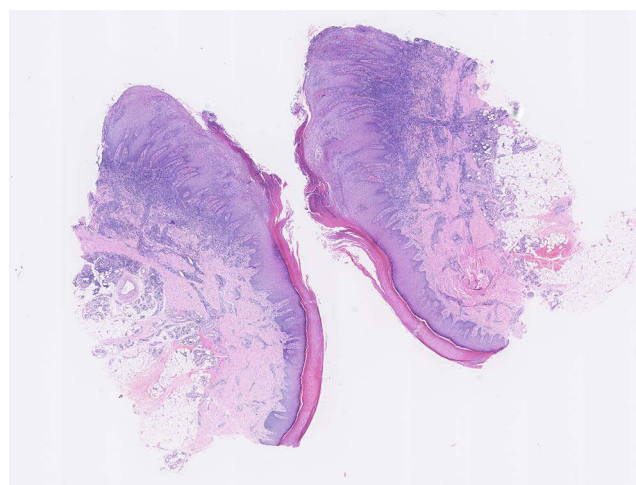
## Case Presentation

A 16-year-old female with no history of skin rashes, systemic symptoms, or significant medical history presented with a one-month history of painful skin lesions on the web between the second and third toes of her left foot. Physical examination revealed several well-defined, reddish-brown, flat-topped, odorless plaques with smooth surfaces located in the interdigital web space between the second and third toes of the left foot (Figure 1). No lesions were observed in the anogenital region, nor was any systemic involvement observed. Initially, the patient was diagnosed with tinea pedis and was topically treated with 2% miconazole nitrate cream for 4 weeks without any improvement. Further inquiry revealed that the patient had been a sex worker for approximately one year and had positive results of human papillomavirus types 16, 26, 33, 58, and 82 from her cervical swab test performed two months prior to her current hospital presentation.

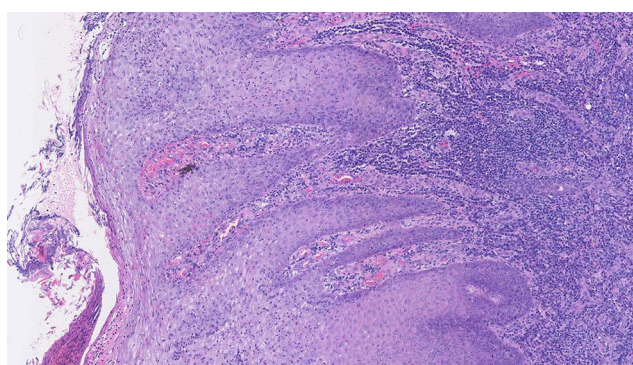


**Figure 1** Interdigital lesions at the patient's first visit.

Histopathology of the lesion revealed parakeratosis, abundant neutrophilic infiltration with acanthosis, and regular elongation of the rete ridges within the epidermis (Figures 2 and 3). Dense infiltration of plasma cells was observed throughout the dermal layer (Figure 3). Immunohistochemistry revealed numerous spirochetes within the epidermis (Figure 4). Both the toluidine red unheated serum test (TRUST) and *Treponema pallidum* hemagglutination test were



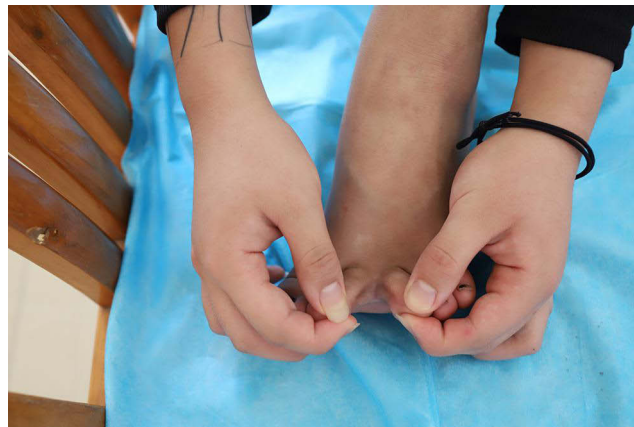**Figure 2** The epidermis contained marked regular elongation of the rete ridges, parakeratosis, and acanthosis (original magnification 40×).



**Figure 3** Evident neutrophilic infiltration in the epidermis layer and dermal inflammation with plasma cell predominance accompanied by swelling of endothelial cells of the small blood vessels (original magnification 200×).



**Figure 4** Innumerable spirochetes within the epidermis and scattered spirochetes within the dermis detected by immunohistochemistry (original magnification 100×).



**Figure 5** Interdigital lesions completely resolved 1 month after treatment.

positive; the TRUST test results were positive at a dilution of 1:64. Human immunodeficiency virus test results were negative. Based on the patient's occupation, histological findings, and serological test results, she was diagnosed with a condyloma latum due to secondary syphilis. According to Chinese guidelines, the patient was treated intramuscularly with 2.4 million units of penicillin G benzathine per week for 2 weeks.<sup>7</sup> One month after treatment, the skin lesion had entirely resolved, and only hyperpigmentation was observed (Figure 5). Six months after treatment, the TRUST titer decreased to 1:4.

## Discussion and Conclusion

Flat-topped papules or plaques with smooth surfaces in intertriginous areas, such as the spaces between toes, may be diagnostic clues for condylomata lata.<sup>6</sup> According to Barei et al, the toe web is the most involved extra-anogenital site in the development of condylomata lata.<sup>8</sup> Vera et al reported that condylomata lata exhibited a predilection for the 3rd and 4th interdigital space and most patients had other skin lesions of secondary syphilis besides the interdigital condylomata lata.<sup>9</sup> Interdigital condylomata lata can mimic tinea pedis, erythrasma, macerated corns, and ulcerated warts, among others.<sup>10</sup> In our case, only a solitary skin lesion on the 2nd toe web space without any concomitant signs of secondary syphilis was found, making the diagnosis more challenging. Melo et al reported that, unlike the typical maculopapular rash of secondary syphilis, the lesion in the toe web space is usually painful, as the patient experienced in our case.<sup>11</sup> We recommend that in cases presenting with painful eroded lesions involving the interdigital area without other cutaneous manifestations, sexual contact history should always be investigated, and a full-body skin examination should be performed. In addition to specific serological tests, we performed direct immunohistopathological tests to identify *T. pallidum*, which is important for the diagnosis of secondary syphilis.<sup>8,12</sup>

We were only able to identify other reports of a solitary condyloma latum in the toe webs of three adult male patients.<sup>8</sup> To the best of our knowledge, a solitary condyloma latum in a single toe web without other secondary syphilis signs in an adolescent female sex worker has not been reported. Penicillin is highly effective against syphilis and is the first-line drug of choice for treatment. In our case, the patient responded well to penicillin G benzathine, and the decline by a factor of 16 in the TRUST titer 6 months after the therapy indicated the serologic cure of the patient.<sup>12</sup>

Notably, adolescent women aged 15–19 years who were out of school had the lowest level of sexual health knowledge in China.<sup>13</sup> Female sex workers are at high risk of catching syphilis.<sup>14,15</sup> Experts have reported that sexual health knowledge, such as consistent condom use, which is favorable for preventing sexually transmitted diseases, is poor among adolescent female sex workers in China.<sup>16</sup> Unfortunately, the detection of adolescent sex workers in hospitals is challenging because of the sexually conservative culture and the illegal nature of sex work in China. Under such circumstances, their occupation is often concealed by patients. Therefore, dermatologists should endeavor to collect detailed social history, such as occupation or sexual contact history. Dermatologists should maintain their awareness of various manifestations of adolescent syphilis to conduct a proper diagnosis, avoid progression to late syphilis, and prevent further transmission to sexual partners. We conclude that syphilis screening, including sexual history acquisition, skin biopsy, and serological testing, should be performed for erosive interdigital lesions, especially in individuals at high risk of acquiring sexually transmitted diseases.

## Abbreviation

TRUST, toluidine red unheated serum test.

## Data Sharing Statement

The datasets used and/or analyzed during the current study are available from the corresponding author on reasonable request.

## Ethics Approval and Informed Consent

Before undergoing the treatment, the patient and her legal guardian provided written informed consent for the case details and images to be published in the report. Writing and publishing this case report was approved by The First Affiliated Hospital of Gannan Medical University.

## Consent for Publication

Consent for publication was included in the informed consent obtained from the participant.

## Acknowledgments

We would like to thank Editage ([www.editage.cn](http://www.editage.cn)) for English language editing.

## Author Contributions

All authors made a significant contribution to the work reported, whether that is in the conception, study design, execution, acquisition of data, analysis and interpretation, or in all these areas; took part in drafting, revising or critically reviewing the article; gave final approval of the version to be published; have agreed on the journal to which the article has been submitted; and agree to be accountable for all aspects of the work.

## Funding

The authors received no financial support for the research, authorship, and/or publication of this case report.

## Disclosure

Authors declare no competing interests for this study.

## References

1. Dong Y, Wang L, Burgner DP, et al. Infectious diseases in children and adolescents in China: analysis of national surveillance data from 2008 to 2017. *BMJ*. 2020;369:m1043. doi:10.1136/bmj.m1043
2. Bernstein KT, Grey J, Bolan G, et al. Developing a Topology of Syphilis in the United States. *Sex Transm Dis*. 2018;45(9):S1–S6. doi:10.1097/OLQ.0000000000000817
3. Balagula Y, Mattei PL, Wisco OJ, et al. The great imitator revisited: the spectrum of atypical cutaneous manifestations of secondary syphilis. *Int J Dermatol*. 2014;53(12):1434–1441. doi:10.1111/ijd.12518
4. Ehlers S, Sergeant S, Ashurst J. Secondary Syphilis. *Clin Pract Cases Emerg Med*. 2020;4(4):675–676. doi:10.5811/cpcem.2020.7.48515
5. Leavens J, Furukawa D, Gates G. Condyloma latum of the plantar foot: case report of an unusual manifestation of secondary syphilis. *Int J STD AIDS*. 2021;32(14):1354–1357. doi:10.1177/09564624211032798
6. Pourang A, Fung MA, Tartar D, et al. Condyloma lata in secondary syphilis. *JAAD Case Rep*. 2021;10:18–21. doi:10.1016/j.jdc.2021.01.025
7. Division for STD control and prevention of China CDC, Dermatology division of Chinese Medical Association, Venereal subspecialty committee of Chinese Dermatologist Association. The diagnosis and therapy guidelines for syphilis, gonorrhea, and urogenital Chlamydia trachomatis infection (2020). *Chin J Dermatol*. 2020;53(3):168–179. doi:10.35541/cjd.20190808
8. Barei F, Murgia G, Ramoni S, et al. Secondary syphilis with extra-genital condyloma lata: a case report and review of the literature. *Int J STD AIDS*. 2022;33(12):1022–1028. doi:10.1177/09564624221124710
9. Vera CI, Bermejo A, Leiro V, et al. Interdigital condylomata lata. *Dermatol Argent*. 2010;16(2010):199–203.
10. Rosen T, Hwong H. Pedal interdigital condylomata lata: a rare sign of secondary syphilis. *Sex Transm Dis*. 2001;28(3):184–186. doi:10.1097/00007435-200103000-00011
11. Melo R, Antonello V, Ramos MC. Painful interdigital lesion: could it be syphilis. *J Eur Acad Dermatol Venereol*. 2018;32(4):e129–e130. doi:10.1111/jdv.14621
12. Ghanem KG, Ram S, Rice PA. The modern epidemic of syphilis[J]. *N Engl J Med*. 2020;382(9):845–854. doi:10.1056/NEJMra1901593
13. Zheng XY, Chen G, Han YL, et al. Survey of youth access to reproductive health in China. *Popul Dev*. 2015;16:2–16. Chinese.
14. Sato T, Shinozaki M, Tsuno NH. The modern epidemic of syphilis. *N Engl J Med*. 2020;382(24):2379. doi:10.1056/NEJMc2006129
15. Chen XS. Challenges in responses to syphilis epidemic. *Lancet Infect Dis*. 2017;17(8):793–794. doi:10.1016/S1473-3099(17)30327-4
16. Lim MS, Zhang XD, Kennedy E, et al. Sexual and reproductive health knowledge, contraception uptake, and factors associated with unmet need for modern contraception among adolescent female sex workers in China. *PLoS One*. 2015;10(1):e0115435. doi:10.1371/journal.pone.0115435

International Journal of Women's Health

Dovepress

### Publish your work in this journal

The International Journal of Women's Health is an international, peer-reviewed open-access journal publishing original research, reports, editorials, reviews and commentaries on all aspects of women's healthcare including gynecology, obstetrics, and breast cancer. The manuscript management system is completely online and includes a very quick and fair peer-review system, which is all easy to use. Visit <http://www.dovepress.com/testimonials.php> to read real quotes from published authors.

Submit your manuscript here: <https://www.dovepress.com/international-journal-of-womens-health-journal>