

# Laparoscopic cholecystectomy under spinal anesthesia: comparative study between conventional-dose and low-dose hyperbaric bupivacaine

Luiz Eduardo Imbelloni<sup>1</sup>  
Raphael Sant'Anna<sup>2</sup>  
Marcos Fornasari<sup>2</sup>  
José Carlos Fialho<sup>2</sup>

<sup>1</sup>Department of Anesthesiology,  
Faculty of Medicine Nova Esperança,  
Hospital de Mangabeira, João Pessoa,  
<sup>2</sup>Hospital Rio Laranjeiras, Rio de  
Janeiro, Brazil

**Background:** Laparoscopic cholecystectomy has the advantages of causing less postoperative pain and requiring a short hospital stay, and therefore is the treatment of choice for cholelithiasis. This study was designed to compare spinal anesthesia using hyperbaric bupivacaine given as a conventional dose by lumbar puncture or as a low-dose by thoracic puncture.

**Methods:** A total of 140 patients with symptomatic gallstone disease were randomized to undergo laparoscopic cholecystectomy with low-pressure CO<sub>2</sub> pneumoperitoneum under spinal anesthesia using either conventional lumbar spinal anesthesia (hyperbaric bupivacaine 15 mg and fentanyl 20 mg) or low-dose thoracic spinal anesthesia (hyperbaric bupivacaine 7.5 mg and fentanyl 20 µg). Intraoperative parameters, postoperative pain, complications, recovery time, and patient satisfaction at follow-up were compared between the two treatment groups.

**Results:** All procedures were completed under spinal anesthesia, with no cases needing conversion to general anesthesia. Values for time for block to reach the T<sub>3</sub> dermatomal level, duration of motor and sensory block, and hypotensive events were significantly lower with low-dose bupivacaine. Postoperative pain was higher for low-dose hyperbaric bupivacaine at 6 and 12 hours. All patients were discharged after 24 hours. Follow-up 1 week postoperatively showed all patients to be satisfied and to be keen advocates of spinal anesthesia.

**Conclusion:** Laparoscopic cholecystectomy can be performed successfully under spinal anesthesia. A small dose of hyperbaric bupivacaine 7.5 mg and 20 µg fentanyl provides adequate spinal anesthesia for laparoscopy and, in comparison with hyperbaric bupivacaine 15% and fentanyl 20 µg, causes markedly less hypotension. The low-dose strategy may have an advantage in ambulatory patients because of the earlier recovery of motor and sensory function and earlier discharge.

**Keywords:** cholecystectomy, laparoscopic, spinal anesthesia

## Introduction

Soon after its introduction, laparoscopic cholecystectomy was established as the treatment of choice for symptomatic gallstone disease.<sup>1</sup> This was as a result of the obvious advantages of the minimally invasive nature of the procedure, which is associated with less postoperative pain, reduced hospital stay, and earlier return to daily activities. A previous study done at our center demonstrated that conventional-dose spinal hyperbaric bupivacaine + fentanyl provided effective anesthesia for laparoscopic cholecystectomy.<sup>2</sup> Also, a low-dose spinal hypobaric lidocaine + fentanyl technique has been shown to provide effective short-duration anesthesia for outpatient

Correspondence: Luiz Eduardo Imbelloni  
Rua Francisco Diomedes Cantalice,  
21/802, Cabo Branco, 58045-210, João  
Pessoa, Paraíba, Brazil  
Tel +55 83 9962 4101  
Email dr.imbelloni@terra.com.br

gynecological laparoscopy,<sup>3,4</sup> with the advantages of no hypotension, minimal motor block, faster sensory recovery, and earlier discharge than with conventional hyperbaric lidocaine anesthesia. The anatomy of the thoracic spinal canal was recently investigated by magnetic resonance imaging in 50 patients.<sup>5</sup> The safety of segmental spinal anesthesia at T<sub>10</sub> has been demonstrated in studies using a combined spinal-epidural<sup>6,7</sup> or single puncture technique.<sup>8</sup> In one recent study of 300 patients, it was demonstrated that thoracic puncture using a cut point needle or pencil point needle was associated with the same incidence of paresthesia as was the lumbar approach, and without sequelae.<sup>9</sup> The purpose of the present study was to compare thoracic puncture using low-dose bupivacaine + fentanyl vs lumbar puncture using conventional-dose bupivacaine + fentanyl for laparoscopic cholecystectomy with respect to intraoperative parameters, postoperative recovery, and complications.

## Materials and methods

Informed consent was obtained from all patients, and the trial protocol was approved by the hospital medical ethics committee. The patients were informed about the risk of need for conversion to general anesthesia, and all signed an informed consent form after being given an explanation of the experimental procedure. All patients recruited for this study were scheduled to undergo elective surgery for cholelithiasis. Additional inclusion criteria were American Society of Anesthesiologists Class I or II presentation and age 16–75 years. Exclusion criteria were acute cholecystitis and the presence of any condition contraindicating elective surgery or spinal anesthesia. Anesthesia and surgery were performed in all cases by the same anesthetic and surgical team. To confirm a reduction in the risk of hypotension from 70% to 30% when using bupivacaine 7.5 mg instead of 15 mg, at 99.5% power with a significance level of 0.01, a sample size of at least 69 patients was required in each group. We chose a sample size of 70 patients in each group, for ease of calculations.

No premedication was given before induction of anesthesia. Routine noninvasive monitoring (electrocardiography, arterial blood pressure, pulse oximetry, expired CO<sub>2</sub>) was started before anesthesia. Intravenous catheterization was done with a 20 gauge catheter inserted into the left hand. All patients received 500 mL of Ringer's lactate solution, with cephalosporin 2 g, ranitidine 50 mg, omeprazole 40 mg, dexamethasone 10 mg, ondansetron 8 mg, and metoclopramide 10 mg. A nasogastric tube was not inserted before induction

in any patient. After obtaining baseline vital signs, oxygen was commenced at 3 L/min through a face mask.

Fentanyl 1 µg/kg and midazolam 1 mg was given before spinal anesthesia. Patients were randomly allocated to receive hyperbaric bupivacaine 0.5% (Cristália Produtos Químicos e Farmacêuticos Ltd, Brazil) 15 mg and fentanyl 20 µg (Group 1) or to receive hyperbaric bupivacaine 0.5% 7.5 mg and fentanyl 20 µg (Group 2). With the patient in the left lateral decubitus position, a 27 gauge pencil point needle with an introducer (Braun Melsungen, Melsungen, Germany) was inserted into the subarachnoid space at the L<sub>3</sub>/L<sub>4</sub> (Group 1) or T<sub>10</sub>/T<sub>11</sub> (Group 2) intervertebral space under aseptic conditions. In both groups, the two drugs were injected intrathecally using separate syringes. After placement of the subarachnoid block, all patients in each group were placed in a 20°–30° Trendelenburg position until the level of sensory anesthesia (tested by pinprick at 1-minute intervals) reached the T<sub>3</sub> dermatome level, after which the surgical procedure was started.

Patients were monitored continuously during surgery by both clinical observation and noninvasive hemodynamic monitoring (electrocardiography, heart rate, arterial blood pressure, respiratory rate, pulse oximetry, expired CO<sub>2</sub>). All data were recorded at 5-minute intervals. Anxiety was treated with midazolam 1 mg, pain with fentanyl 50 µg, hypotension with noradrenaline 2 mg, and bradycardia with atropine 0.50 mg, all given as intravenous boluses as required. Drug consumption and fluid balance were recorded. Conversion criteria were necessity for a nasogastric tube, any organ lesion, bleeding, or lack of patient satisfaction with spinal anesthesia at any time during the procedure.

The standard laparoscopic technique<sup>2</sup> was used in all patients with one modification, ie, after visualization of the abdomen using a camera, lidocaine 1% 10 mL was sprayed under the right side of the diaphragm through a 14 gauge needle inserted below the lower border of the tenth rib.

Operative time was recorded, as well as any intraoperative incidents, especially those related to the type of spinal anesthesia, ie, shoulder pain, headache, nausea, and discomfort. Hemodynamic effects, necessity for a nasogastric tube, duration of pneumoperitoneum, duration of anesthesia (from puncture to dressing), and necessity to increase intra-abdominal pressure >8 mmHg were evaluated in both groups. Time for the block to reach the T<sub>3</sub> dermatomal level and time to regression of sensory and motor block were also recorded. At the end of surgery, we evaluated the ability of the patient to move to the stretcher unaided.

Postoperatively, all patients were given standard intravenous dextrose 5% 1.5 L for 24 hours and intravenous analgesia of ketoprofen 100 mg every 8 hours and dipirone 1.5 g every 4/4 h. Postoperative pain was assessed in both groups using a visual analog scale at hours 2, 4, 6, and 12 after completion of the procedure. Other postoperative events potentially related to either the surgical or anesthetic procedure, ie, discomfort, nausea and vomiting, shoulder pain, urinary retention, pruritus, headache, or other neurologic sequelae, were also recorded. The day after the surgery, patients were fed by mouth from 4 hours after the end of the procedure and were discharged 24 hours after the procedure if no complications occurred. All patients were followed up by telephone for 1 week postoperatively, and asked to assess their degree of satisfaction (high, fair, or not at all) with the procedure.

## Statistical analysis

Statistical analysis was done using mean (standard deviation), median (interquartile range), and percentage values. Comparison of mean values according to treatment group were done using the *t*-test, with comparison of median values performed using the Kruskal–Wallis test. Percentage comparison of “yes” and “no” responses was done using Pearson’s Chi-square test or by Fisher’s Exact test as appropriate. The significance level was set at  $\alpha = 0.05$ .

## Results

There were no significant differences in age, weight, height, gender, or theater time between the two groups (Table 1). Demographic data and surgical history were similar for the two groups. All procedures were completed laparoscopically without violation of the present protocol. No significant difference was found in operative time between the groups (range 35–86 minutes, see Table 2). Conversion from spinal to general anesthesia was not required in any of the cases,

**Table 1** Characteristics of patients who underwent laparoscopic cholecystectomy and previous surgeries (mean  $\pm$  standard deviation)

Characteristics	15 mg n = 70	7.5 mg n = 70	P-value
Age (years)	38.2 (11.3)	37.5 (10.8)	0.69
Weight (kg)	70.6 (12.5)	70.0 (12.8)	0.78
Height (cm)	163.3 (8.1)	162.3 (7.7)	0.46
BMI (kg/m <sup>2</sup> )	26.4 (4.2)	26.6 (4.7)	0.86
Gender (F/M)	49/21	54/16	0.86
Previous surgeries (yes/no)	37/33	42/28	0.40

**Abbreviations:** BMI, body mass index; F, female; M, male.

**Table 2** Characteristics in both groups in perioperative period (mean  $\pm$  standard deviation)

Parameter	15 mg n = 70	7.5 mg n = 70	P-value
Time until T <sub>3</sub> (minutes)	7.2 (1.1)	2.7 (0.5)	<0.0005
Surgical time (minutes)	59.9 (13.2)	56.6 (12.9)	0.14
Pneumoperitoneum (minutes)	36.4 (10.8)	33.9 (9.4)	0.15
Intravenous fluid (mL) <sup>1</sup>	1100 (113)	1050 (100)	0.050
Shoulder pain (yes/no) <sup>2</sup>	10/60	18/52	0.091
Nausea and vomiting (yes/no) <sup>2</sup>	0/70	1/69	1.0
Doses of midazolam (mg) <sup>1</sup>	3 (1)	2 (1)	0.23
Rescue fentanyl (yes/no) <sup>2</sup>	10/60	12/58	1.0
Hypotension (yes/no) <sup>2</sup>	27/43	10/60	0.64
Need for vasopressor <sup>1</sup> (n)	0 (1)	0 (0)	<0.005
Bradycardia (yes/no) <sup>2</sup>	8/62	2/68	0.049
Table to stretcher (yes/no) <sup>2</sup>	0/70	42/28	<0.0005

**Notes:** <sup>1</sup>Median (interquartile range); <sup>2</sup>Fisher’s Exact test.

and no major adverse intraoperative events occurred. There was no need to convert to open surgery in any patient. Twenty patients had dense adhesions of the omentum to the anterior abdominal wall, all of which were dissected successfully. Local washing of the right diaphragm with lidocaine solution 1% 10 mL was successful in preventing pain in 112 patients. Intravenous fentanyl 50  $\mu$ g was needed in 22 patients due to severe right shoulder pain; surgery was continued and completed uneventfully after administration of rescue analgesic in all cases.

Mean time for the block to reach T<sub>3</sub> was significantly ( $P < 0.0005$ ) longer in Group 1 than in Group 2 (7.2 [ $\pm 1.1$ ] minutes vs 2.7 [ $\pm 0.5$ ] minutes, respectively, Table 2). There was no significant difference in duration of pneumoperitoneum or in overall duration of surgery between the groups. Increased CO<sub>2</sub> pressure was not required in any patient in either treatment group. No patient required nasogastric tube insertion, and no patient had retention of CO<sub>2</sub>. There was no significant difference between the groups with regard to volume of lactate solution required.

None of the patients had cardiopulmonary problems during surgery, except for transient hypotension, which occurred in 27 (38.5%) patients in Group 1 and 10 (14.2%) in Group 2; the difference between the two groups was significant ( $P = 0.001$ ). Mean arterial blood pressure normalized in 27 patients with one dose of noradrenaline and in nine patients with two doses, and the procedure was completed uneventfully thereafter. Bradycardia developed in ten patients in each group.

Table 3 shows postoperative surgery-related and anesthesia-related events, including nausea, vomiting, urinary

**Table 3** Collateral effects during the postoperative period and duration of block (mean  $\pm$  standard deviation)

Parameter	15 mg n = 70	7.5 mg n = 70	P-value
Shoulder pain (y/n)	8/62	10/60	0.61
Nausea and vomiting (y/n)	2/68	3/67	0.65
Pruritus (y/n) <sup>2</sup>	8/62	12/58	0.33
Urinary retention	0	0	
Sensitive block (hours)	4.14 (0.36)	2.35 (0.25)	<0.0005
Motor block (hours)	3.06 (0.27)	1.17 (0.15)	<0.0005

Abbreviations: y, yes; n, no.

retention, right shoulder pain, and pruritus. The frequency of shoulder pain was similar in both groups. All patients were able to be discharged 24 hours after surgery and no patient required readmission. No patient complained of headache or other neurologic sequelae related to spinal anesthesia. Mean duration of motor block (3.06 [ $\pm$ 0.27] hours vs 1.17 [ $\pm$ 0.15] hours, respectively) as well as duration of sensory block were significantly ( $P < 0.0005$  for both) longer (4.14 [ $\pm$ 0.367] hours vs 2.35 [ $\pm$ 0.25] hours) with bupivacaine 15 mg than with bupivacaine 7.5 mg (Table 3). There was a reduction of 45.9% ( $\pm$ 2.9%) with bupivacaine 15 mg and 33.6% ( $\pm$ 2.1%) with bupivacaine 7.5 mg in the duration of motor block in relation to sensory block ( $P < 0.0005$ ).

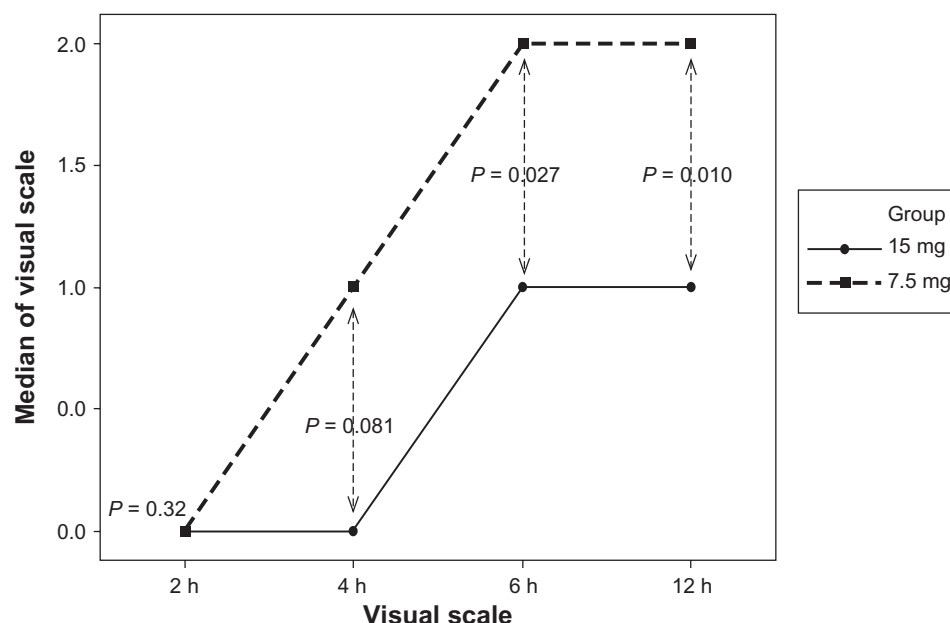
The median postoperative pain score 2 hours after completion of the procedure was the same in both groups (0, range 0–2,  $P = 0.64$ ), at 4 hours was 0 (range 0–3) in Group 1 and 1 (range 0–3) in Group 2 ( $P = 0.006$ ), at 6 hours was 1 (range 0–3) in Group 1 and 2 (range 0–5) in

Group 2 ( $P = 0.001$ ), and at 12 hours was 1 (range 0–2) in Group 1 and 1 (range 0–3) in Group 2 ( $P = 0.064$ ), indicating significantly higher median values at later time points in Group 2 (see Figure 1). All patients in Group 1 recovered within the 5 hours following surgery and were ready to be discharged from hospital, whereas all the Group 2 patients recovered within 3 hours following surgery. However, all patients were kept in hospital overnight to monitor clinical parameters (including heart rate and blood pressure) and any side effects (including nausea, vomiting, and headache) and were discharged the following morning.

One hundred and thirty-three patients reported that they were highly satisfied with the procedure, with seven patients reporting being dissatisfied because of experiencing longer motor block. All patients reported that they would definitely recommend spinal anesthesia for laparoscopic cholecystectomy. No late complications were detected at the 3-month follow-up.

## Discussion

A reduced dose of hyperbaric bupivacaine (7.5 mg) given in combination with fentanyl 20  $\mu$ g as a single dose provided adequate spinal block for laparoscopy cholecystectomy. Low-dose spinal anesthesia provided better hemodynamic stability, less hypotension, and a shorter duration of both sensory and motor block than with the conventional-dose hyperbaric bupivacaine + fentanyl combination. Block was adequate in all patients. Hemodynamic stability was reflected in a minimal need for vasopressor support.

**Figure 1** Pain scores on visual analog scale during the postoperative period.

The combined spinal epidural block technique is able to be performed at the lower thoracic level without difficulty, the tenth interspaces being chosen as lying in the center of the surgical field.<sup>10</sup> In this study, we utilized the same space without the aid of the combined spinal epidural set. No patient experienced paresthesia during initial insertion of the pencil point spinal needle, in contrast with a previous report using the same needle which showed an incidence of paresthesia of 5%.<sup>10</sup>

Laparoscopic cholecystectomy has rapidly become a popular alternative to open cholecystectomy, and is considered a cost-effective technique for the treatment of symptomatic cholelithiasis. Spinal anesthesia has some advantages compared with general anesthesia,<sup>2,11</sup> including the patient being awake and oriented at the end of the procedure, less postoperative pain, and the ability to ambulate earlier than patients receiving general anesthesia. Some potential problems related to the technique of general anesthesia, including damage to the teeth and oral cavity during insertion of the laryngoscope, sore throat, and pain related to intubation and/or extubation, are avoided by administering spinal anesthesia to selected patients undergoing laparoscopic interventions.<sup>12</sup> Use of bupivacaine 7.5 mg resulted in a significant reduction in recovery time from sensory and motor block, whereby 60% of patients were able to move themselves to the stretcher unaided. None of the patients who received the conventional 15 mg dose was able to move to the stretcher without help.

In our study, low-dose spinal anesthesia did not require any modification of surgical technique, except for a low flow rate of insufflation to avoid vagal reflexes and bradycardia. Tolerance of laparoscopy under spinal anesthesia was facilitated by limiting the total volume of CO<sub>2</sub> used for peritoneal insufflation to a maximum of 4 L and parenteral administration of analgesia and/or sedation. The intra-abdominal pressure of 8 mmHg is consistent with that reported previously.<sup>2</sup>

It would be desirable to provide patients undergoing laparoscopy cholecystectomy with the option of regional anesthesia. Conventional<sup>2,11</sup> and low-dose<sup>10</sup> epidural<sup>12</sup> bupivacaine spinal anesthesia has been used in the past. One of the major problems with laparoscopic cholecystectomy under spinal anesthesia is severe right shoulder pain.<sup>2,11</sup> A modification in the technique in relation to a previous series<sup>2</sup> was the administration of lidocaine 1% 10 mL intraperitoneally soon after introduction of the camera. This enabled a marked reduction in the incidence of shoulder pain from 47% to 20%, with a reduction in use of rescue analgesia from 29.4% to 15%.<sup>2</sup>

Spinal anesthesia is associated with a risk of severe and prolonged hypotension due to rapid extension of sympathetic block. Intraoperative hypotension is another problem for laparoscopic cholecystectomy under spinal anesthesia.<sup>2,10</sup> Hypotension on the conventional dose of hyperbaric bupivacaine has been variously reported at 41%<sup>2</sup> and 59%.<sup>11</sup> In this study, hypotension severe enough to require treatment with noradrenaline occurred in 38.5% of patients who received conventional-dose bupivacaine, whereas only ten patients (14.2%) in the low-dose group developed hypotension. A reduced dose of hyperbaric bupivacaine (7.5 mg) in combination with sufentanil 5 µg provides reliable spinal anesthesia for the repair of hip fracture in elderly patients, with few hypotensive events and little need for vasopressor support.<sup>13</sup> A similarly reduced dose of hyperbaric bupivacaine 7.5 mg given in combination with fentanyl in patients undergoing laparoscopic cholecystectomy affords better hemodynamic stability and fewer adverse events, as reflected in the minimal need for vasopressor support in our study.

A study of 40 patients showed that a combination of fentanyl 20 µg and hyperbaric bupivacaine 7.5 mg provides adequate block for ambulatory inguinal herniorrhaphy.<sup>14</sup> Another recent study of 25 patients undergoing repair of hip fracture reported adequate block and good postoperative pain relief with a combination of sufentanil 5 µg and hyperbaric bupivacaine 7.5 mg when compared with a conventional dose.<sup>13</sup> In this study, a combination of low-dose hyperbaric bupivacaine and fentanyl achieved adequate block and good postoperative pain control comparable with that of a conventional dose.

Differences in the duration of motor and sensory block may be partly due to the smaller dose of bupivacaine and is consistent with previous reports.<sup>13</sup> Our study demonstrated a reduction in the duration of motor block in relation to sensory block of 45.9% with bupivacaine 15 mg and 33% with bupivacaine 7.5 mg. This can be explained by deposition of the hyperbaric dose predominantly on the sensory nerve roots (posterior) in relation to the motor nerve roots (anterior and in this case uppermost).<sup>15</sup> This explains the quality of the analgesia during the postoperative period. The 50% reduction in the dose of hyperbaric bupivacaine provided faster recovery from motor block, enabling 60% of patients to move from the table to the stretcher unaided, making this technique excellent for ambulatory surgery. The low-dose strategy may thus have an advantage in ambulatory patients because of the earlier recovery of motor and sensory function.



Theoretically, the addition of intrathecal fentanyl should improve the quality of the block and provide postoperative analgesia. However, this also caused side effects, including pruritus, vomiting, drowsiness, and urinary retention. The incidence of postoperative nausea and vomiting was 3.5% and for pruritus was 14.2%. Neither urinary retention nor postoperative postural headache occurred in any patient.

Paresthesia can occur with any spinal anesthetic technique, but is of potentially greater significance when the needle is inserted above the conus medullaris. A study of 300 patients undergoing thoracic spinal puncture reported a 6.6% incidence of paresthesia without neurological sequelae,<sup>9</sup> ie, the same as for lumbar puncture.

In an earlier study of 3492 patients, the authors concluded that laparoscopic cholecystectomy done under spinal anesthesia does not require any change in technique and, at the same time, has a number of advantages when compared with general anesthesia, and should be the anesthesia of choice.<sup>16</sup>

In summary, the present study has shown that a small dose of hyperbaric bupivacaine 7.5 mg in combination with fentanyl 20 µg provides adequate spinal anesthesia for laparoscopic cholecystectomy. This low-dose combination, in comparison with the conventional 15 mg dose of hyperbaric bupivacaine with 20 µg fentanyl, causes less hypotension and fewer requirements for noradrenaline to support blood pressure. The low-dose strategy may have an advantage in ambulatory patients because of the earlier recovery of motor and sensory function and earlier discharge.

## Disclosure

The authors report no conflicts of interest in this work.

## References

1. Soper NJ, Stockman PT, Dunnegan DL, Ashley SW. Laparoscopic cholecystectomy: The new "gold standard"? *Arch Surg*. 1992;127:917–921.
2. Imbelloni LE, Fornasari M, Fialho JC, Sant'Anna R, Cordeiro JA. General anesthesia versus spinal block for laparoscopic cholecystectomy. *Rev Bras Anesthesiol*. 2010;60:264–273.
3. Vaghadia H, McLeod DH, Mitchell GWE, Merrick PM, Chilvers CR. Small-dose hypobaric lidocaine-fentanyl spinal anesthesia for short duration outpatient laparoscopy. I. A randomized comparison with conventional dose hyperbaric lidocaine. *Anesth Analg*. 1997;84:59–64.
4. Chilvers CR, Vaghadia H, Mitchell GWE, Merrick PM. Small-dose hypobaric lidocaine-fentanyl spinal anesthesia for short duration outpatient laparoscopy. II. Optimal fentanyl dose. *Anesth Analg*. 1997;84:65–70.
5. Imbelloni LE, Quirici MB, Ferraz-Filho JR, Cordeiro JA, Ganem EM. The anatomy of the thoracic spinal canal investigated with magnetic resonance imaging. *Anesth Analg*. 2010;110:1494–1495.
6. van Zundert AAJ, Stultiens G, Jakimowicz JJ, et al. Laparoscopic cholecystectomy under segmental thoracic spinal anaesthesia: A feasibility study. *Br J Anaesth*. 2007;98:682–686.
7. Imbelloni LE, Fornasari M, Fialho JC. Combined spinal epidural anesthesia during colon surgery in a high-risk patient. Case report. *Rev Bras Anesthesiol*. 2009;59:741–745.
8. Hobaika ABS. Thoracic spinal anesthesia for gastrostomy in a patient with severe lung disease. *Acta Anaesthesiol Scand*. 2007;51:783.
9. Imbelloni LE, Pitombo PF, Ganem EM. The incidence of paresthesia and neurologic complications after lower spinal thoracic puncture with cut needle compared to pencil point needle. Study in 300 patients. *J Anesth Clinic Res*. 2010;1:106.
10. van Zundert AAJ, Stultiens G, Jakimowicz JJ, et al. Laparoscopic cholecystectomy under segmental thoracic spinal anaesthesia: A feasibility study. *Br J Anaesth*. 2007;98:682–686.
11. Tzoravaras G, Fafoulakis F, Pratsas K, Georgopoulou S, Stamatou G, Hatzitheofilou C. Spinal vs general anesthesia for laparoscopic cholecystectomy. Interim analysis of a controlled randomized trial. *Arch Surg*. 2008;143:497–501.
12. Pursani KG, Bazza Y, Calleja M, Mughai MM. Laparoscopic cholecystectomy under epidural anesthesia in patient with chronic respiratory disease. *Surg Endosc*. 1998;12:1082–1084.
13. Olofsson C, Nygård EB, Bjersten AB, Hessling A. Low-dose bupivacaine with sufentanil prevents hypotension after spinal anesthesia for hip repair in elderly patients. *Acta Anaesthesiol Scand*. 2004;48:1240–1244.
14. Gupta A, Axelsson K, Thörn SE, Mathiessen P, Larsson LG, Holmström B. Low-dose bupivacaine plus fentanyl for spinal anesthesia during ambulatory inguinal herniorrhaphy: A comparison between 6 mg and 7.5 mg of bupivacaine. *Acta Anaesthesiol Scand*. 2003;47:13–19.
15. Gouveia MA, Imbelloni LE. Understanding spinal anaesthesia. *Acta Anaesthesiol Scand*. 2006;50:260.
16. Sinha R, Gurwara AK, Gupta MS. Laparoscopic cholecystectomy under spinal: A study of 3492 patients. *J Laparoendosc Adv Surg Tech A*. 2009;19:323–327.

### Local and Regional Anesthesia

### Publish your work in this journal

Local and Regional Anesthesia is an international, peer-reviewed, open access journal publishing on the development, pharmacology, delivery and targeting and clinical use of local and regional anesthetics and analgesics. The journal welcomes submitted papers covering original research, basic science, clinical studies, reviews & evaluations,

Submit your manuscript here: <http://www.dovepress.com/local-and-regional-anesthesia-journal>

guidelines, expert opinion and commentary, case reports and extended reports. The manuscript management system is completely online and includes a very quick and fair peer-review system, which is all easy to use. Visit <http://www.dovepress.com/testimonials.php> to read real quotes from published authors.

Dovepress