

# DMEK Surgery at a Tertiary Hospital in Sweden. Results and Complication Risks

Kinga Dabrowska-Kloda<sup>1</sup>, Eydis Olafsdottir<sup>1</sup>, Anastasia Stefanou<sup>1</sup>, Sven Crafoord<sup>1,2</sup>

<sup>1</sup>Department of Ophthalmology, Örebro University Hospital, Örebro, Sweden; <sup>2</sup>Department of Ophthalmology, Faculty of Medicine and Health, Örebro University, Örebro, Sweden

Correspondence: Kinga Dabrowska-Kloda, Department of Ophthalmology, Örebro University Hospital, PO Box 1613, Örebro, SE 70116, Sweden, Tel +46 19 6021000, Fax +46 19 6021052, Email kinga-magdalena.dabrowska-kloda@regionorebrolan.se

**Purpose:** This study reports clinical outcomes up to 6 years after Descemet's membrane endothelial keratoplasty (DMEK) performed at the Department of Ophthalmology, Örebro University Hospital, Örebro, Sweden.

**Methods:** The study has a cross-sectional and case series design. Inclusion criteria were all DMEK-operated eyes during 2013–2018 until repeat keratoplasty.

**Results:** Altogether 162 eyes from 120 patients were enrolled. Among eyes without preoperative comorbidities, examined 1–6 years after DMEK, 85.8% achieved visual acuity of 0.1 logMAR or better. The median endothelial cell density (ECD) loss was 27% in a cohort of eyes examined 1–2 years post-DMEK, 31% at 2–3 years, 42% at 3–4 years, and > 60% at 4–6 years post-DMEK. ECD at the examination timepoint was correlated with donor ECD (as expected) and time since surgery.

**Conclusion:** The results from DMEK surgeries in Örebro, Sweden, are promising. Further studies with even longer follow-up are needed to evaluate graft sustainability.

**Keywords:** DMEK, Descemet's membrane endothelial keratoplasty, endothelial cell density, endothelial cell loss, corneal surgery in Sweden, corneal surgery in Scandinavia

## Introduction

Descemet's membrane endothelial keratoplasty (DMEK) has been used increasingly for treatment of corneal endothelial dysfunction in recent years. In this technique, only the corneal endothelium and Descemet's membrane are transplanted without a layer of posterior stroma, in contrast to Descemet's stripping endothelial keratoplasty (DSEK). Compared with DSEK<sup>1–4</sup> and even with ultrathin DSEK in which the graft is <100 µm thick,<sup>5</sup> DMEK is the surgical procedure with superior visual acuity results. Moreover, the risk of graft rejection is significantly lower with DMEK than with DSEK.<sup>6–8</sup> However, the surgical technique is more challenging in DMEK<sup>9–12</sup> and, according to a recent report by the European Cornea and Cell Transplantation Registry, DSEK is still the most frequent technique for corneal transplantation in Europe.<sup>13</sup>

The Department of Ophthalmology at Örebro University Hospital and St. Erik's Eye Hospital in Stockholm were the first institutes of ophthalmology that introduced DMEK surgery in Sweden, in 2013. There are several publications on DMEK surgery results from different countries<sup>11,14–16</sup> but - to the best of our knowledge- there are no studies with follow-up >2 years from Scandinavia. This is the first report from Sweden about DMEK results up to 6 years after surgery.

The Department of Ophthalmology at Örebro University Hospital is the tertiary referral center for corneal diseases in Sweden. The included surgeries were performed both on local patients and patients referred from several ophthalmological centers providing care for a total of 2.2–3.5 million inhabitants (Official Statistics of Sweden).<sup>17</sup> All patients were followed up at our clinic in Örebro up to at least 1 month after the DMEK procedure. The consecutive follow-up visits up to 2 years post-DMEK took place at regional eye clinics; the patients were referred to us when needed. The additional follow-up visit was performed at our clinic in Örebro in March 2020 (1.2–6.8 years postoperatively).

## Materials and Methods

### Study Design

All patients who underwent DMEK surgery in Sweden during 2013–2018 were invited to participate in the study. The participants were examined during a 2-week period in March 2020. Inclusion criteria were: all eyes that underwent DMEK surgery at the Department of Ophthalmology, University Hospital in Örebro, Sweden, between 2013 and 2018. The eyes were included until repeat keratoplasty. Exclusion criteria were: repeat DMEK (two eyes), refusal, or inability to participate in the study (87 eyes).

Best spectacle-corrected visual acuity (BSCVA) was assessed by a certified optician using an ETDRS chart in all cases except for one case with BSCVA <0.1 decimal. In this case a four-letter low-vision acuity chart was used (low-vision acuity chart).<sup>18</sup> Endothelial cell density (ECD) was evaluated in vivo using a Konan Cell Check specular microscope (Konan Medical, Irvine, CA, USA). The automatically delineated cell borders were checked and manually reassigned, where appropriate, by an ophthalmologist. Central corneal thickness (CCT) was measured with Scheimpflug tomography (Pentacam; Oculus, Wetzlar, Germany). The applanation eye pressure was measured and a complete slit-lamp examination of the eyes was performed by an ophthalmologist.

Retrospective data on the DMEK surgery, such as date, ocular comorbidities, preoperative BSCVA, BSCVA 1 month after surgery (both obtained using Snellen chart and, in a few cases, a four-letter low-vision acuity chart), and operative and postoperative complications, were collected.

### Surgical Technique

Donor preparation: The DMEK grafts were initially prepared by the surgeon employing the submerged cornea using the backgrounds away (SCUBA) technique described by Price et al.<sup>12</sup> In this technique, the donor corneoscleral rim is submerged in a corneal storage solution, and Descemet's membrane is scored just inside the trabecular meshwork and peeled off with forceps. Before the membrane is completely peeled off it is floated back into position and cut with a trephine, usually to 8 mm. Once the method was established in our Department, the local eye bank provided the grafts (since 1st January 2017).

Recipient preparation and donor insertion: Laser iridotomy was performed in all cases the day before surgery. The majority of operations were performed under topical anesthesia. The epithelium was marked to indicate the planned graft diameter and Descemet's membrane scored just outside this mark. The graft was stained with trypan blue for 2 minutes. Initially, the graft was inserted with an intraocular lens cartridge but later this was done using a glass tube (Geuder Szurman Single-Use DMEK Cartridge; Geuder AG, Heidelberg, Germany). A hand-held slit lamp was used to determine the orientation of the graft, later to be replaced by intraoperative optical coherence tomography (OCT). After the graft was unrolled it was pressed against the cornea with air for 10 minutes. Then the air was reduced. All patients were checked at the slit lamp 2 hours after surgery.

### Statistical Analysis

Statistical analysis was performed using SPSS, version 27 (SPSS Inc., Chicago, IL, USA).

The BSCVA values were converted to the logarithm of the minimum angle of resolution (logMAR) prior to statistical analysis. Differences between preoperative BSCVA, BSCVA 1 month postoperatively, and BSCVA at the examination time point for cohorts examined 1–2 years, 2–3 years, 3–4 years, 4–5 years, and >5 years postoperatively were compared using Wilcoxon signed-rank test. This was performed separately for eyes with and without ocular comorbidities preoperatively. Differences between primary ECD in the graft and ECD at the examination time point for cohorts examined 1–2 years, 2–3 years, 4–5 years, and > 5 years postoperatively were evaluated using Wilcoxon signed-rank test. A p-value of <0.05 was considered statistically significant. The Spearman rank correlation coefficient between ECD and central corneal thickness (CCT) was calculated.

The influence of variables such as the patient's age and sex, operation side, surgery indication, baseline ECD in the graft, air reinjection (i.e. rebubbling), rejection episodes, cystic macular edema after surgery, increased intraocular pressure (IOP) (defined as >21 mmHg during follow-up time) and time from DMEK surgery were analyzed using

multiple linear regression analysis, method: forward. (criterion for each variable to enter:  $p \leq 0.05$ ). The Bonferroni correction was applied to account for multiple testing. Associations were considered statistically significant when  $p < 0.005$  (0.05/10). For the patients who had bilateral DMEK, only the first operated eye was included in the analysis. Temporary elevation of IOP during the first 3 postoperative days was not included as, according to a recent study, this does not affect the endothelial cell count in non-glaucomatous eyes.<sup>19</sup>

## Results

A total of 251 DMEK procedures in 198 patients were identified during the period 2013–2018. Out of 189 alive patients, 120 (63.5%) participated in the study. Altogether 162 eyes from 120 patients were enrolled. The indication for surgery was Fuchs endothelial dystrophy in 94.5% of cases. When the diagnosis was made and the patient qualified for DMEK, cataract surgery was performed prior to DMEK in most of the eyes (98.8%). Other indications were: bullous keratopathy, failed DSEK surgery, and congenital hereditary corneal dystrophy. The details are presented in Table 1. Thirteen eyes were excluded from both visual outcome and ECD and CCT analysis because they underwent repeat keratoplasty.

## Visual Acuity Outcome

The visual outcome was analyzed separately for eyes with and without ocular comorbidities preoperatively. The results are presented in Figures 1 and 2 respectively. Of altogether 20 eyes with comorbidities, 13 eyes had maculopathy, while one eye was diagnosed with chronic cystic macular edema after cataract surgery, three eyes with amblyopia, one eye with keratoconus, and two with central corneal scarring.

A total of 85.8% of 129 eyes without comorbidities had a visual acuity of 0.1 logMAR (ie 20/25 decimal) or better at the examination time point. The median visual acuity changed from 0.52 logMAR preoperatively to 0 logMAR at the examination time point. For details, see Table 2. The difference in measurements was statistically significant ( $p < 0.001$ ). Also in eyes with ocular comorbidities, a significant change in visual outcome was observed ( $p = 0.002$ ) (Table 3).

A detailed distribution of visual outcomes for cohorts with different follow-up times is shown in Figures 3 and 4.

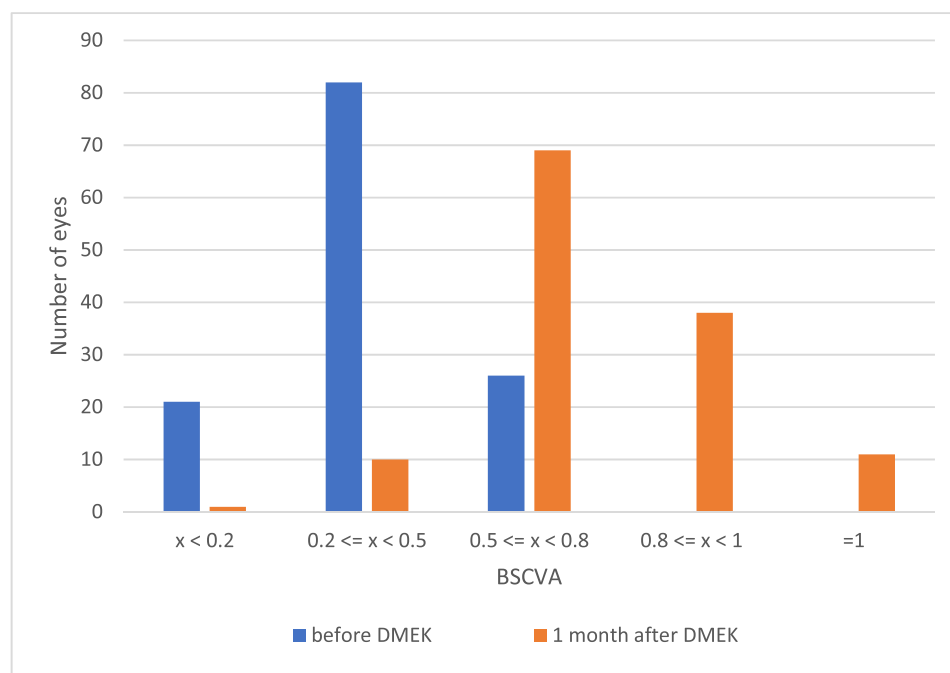
## Endothelial Cell Density

Altogether 144 eyes out of 162 were enrolled in the ECD analysis. As mentioned before, 13 eyes were excluded owing to repeat keratoplasty. Additionally, two eyes were excluded because of a lack of ECD data, and three eyes because of dense corneal opacities that interfered with ECD measurement (of these, two eyes had central stromal scarring, and one had dense band keratopathy).

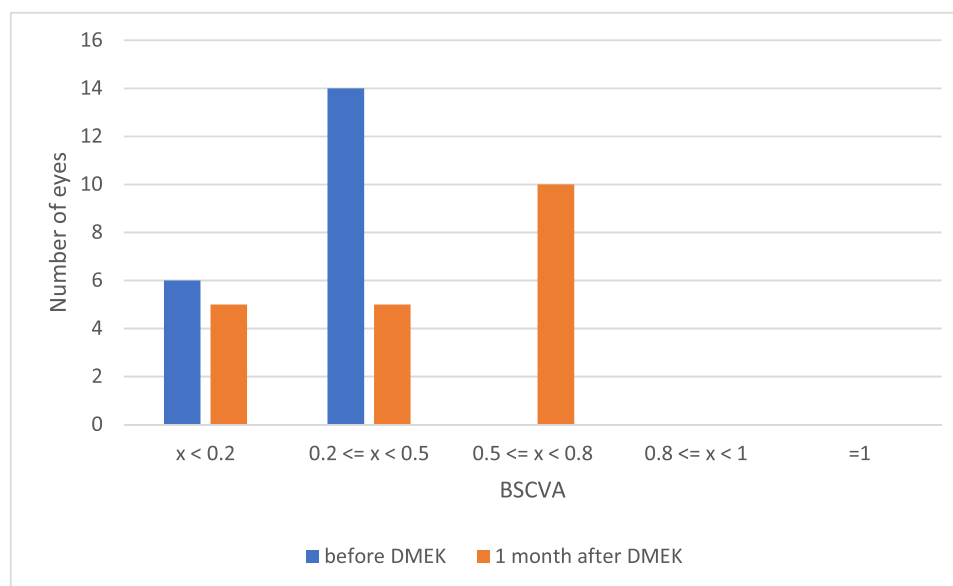
**Table 1** Recipient Demographics and Surgical Procedures in 162 Eyes from 120 Patients

		N
Mean age ( $\pm$ SD), years; range	70 ( $\pm$ 8); 24–86	
Sex (female eyes/ male eyes)	62%/38%	101/61
Indication for DMEK		
• FECD	94.5%	153
• Failed DSEK	4.3%	7
• Bullous keratopathy	0.6%	1
• Congenital hereditary corneal dystrophy	0.6%	1
Preoperative lens status (pseudophakic/phakic)	98.8%/1.2%	160/2
Ocular comorbidity preoperatively	12.3%	20
Surgical procedure		
• DMEK	99.4%	161
• DMEK + phacoemulsification + IOL	0.6%	1

**Abbreviations:** N=number; DMEK=Descemet's membrane endothelial keratoplasty; DSEK=Descemet's stripping endothelial keratoplasty; FECD=Fuchs endothelial corneal dystrophy; IOL= intraocular lens; SD= standard deviation.



**Figure 1** Best spectacle corrected visual acuity (BSCVA) before and 1 month after DMEK (decimal), eyes without comorbidities.



**Figure 2** Best spectacle corrected visual acuity (BSCVA) before and 1 month after DMEK (decimal), eyes with comorbidities.

The baseline donor ECD range was 2125–3375 cells/mm<sup>2</sup>, an average 2655 ( $\pm 253$ ) cells/mm<sup>2</sup>, and a median 2625 cells/mm<sup>2</sup>. Table 4 presents ECD data for cohorts of eyes examined at 1–2, 2–3, 3–4, 4–5, and >5 years postoperatively, the median and interquartile range of ECD, and ECD loss. The differences in measurements for respective cohorts were statistically significant ( $p < 0.001$ ).

Figure 5 shows ECD loss. The Spearman rank correlation coefficient between ECD and CCT was negative ( $r_s = -0.22$ ) and statistically significant ( $p = 0.008$ ).

After excluding the second DMEK-operated eye in patients who had bilateral surgery (37 out of 144 eyes) 107 eyes were enrolled in multivariate linear regression analysis. Parameters associated with ECD at the examination timepoint

**Table 2** Visual Acuity of 129 Eyes Without Comorbidities in logMAR; and Decimal Notation

	Preoperatively	At 1 Month	At the Examination Time Point
25th percentile	0.70; 0.2	0.22; 0.6	0.10; 0.8
Median (range)	0.52 (0.15–2.0); 0.3	0.15 (0–0.8); 0.7	0; (0–0.9); 1.0
75th percentile	0.40; 0.4	0.10; 0.8	0; 1.0

**Notes:** Italicized values show the range of the visual acuity in logMAR.

**Abbreviation:** logMAR= the logarithm of the minimum angle of resolution.

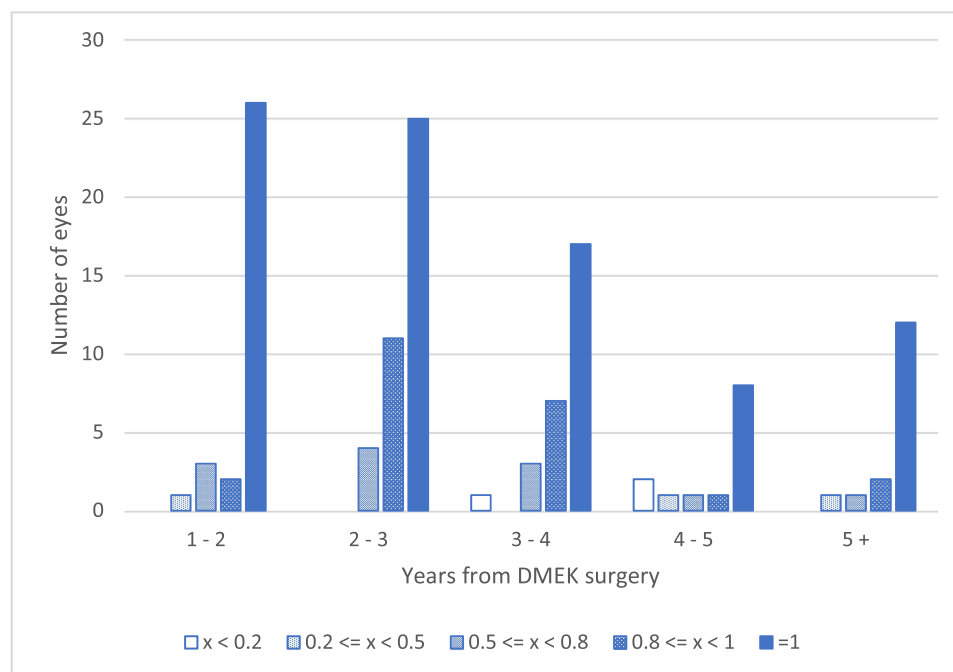
**Table 3** Visual Acuity of 20 Eyes with Comorbidities in logMAR; and Decimal Notation

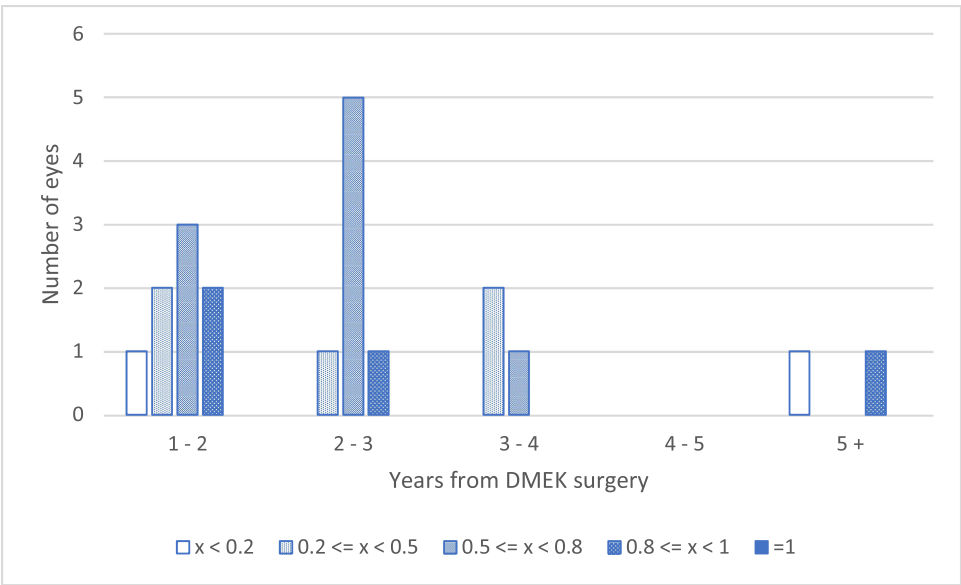
	Preoperatively	At 1 Month	At the Examination Time Point
25th percentile	0.89; 0.13	0.65; 0.22	0.43; 0.37
Median (range)	0.52 (0.4–1.52); 0.3	0.35 (0.15–1.52); 0.45	0.30 (0.1–2.0); 0.50
75th percentile	0.40; 0.4	0.28; 0.52	0.20; 0.63

**Notes:** Italicized values show the range of the visual acuity in logMAR.

**Abbreviation:** logMAR= the logarithm of the minimum angle of resolution.

were: baseline ECD ( $p < 0.001$ ) and time from surgery ( $p < 0.001$ ). No correlation was found between ECD and the variables: age, sex, operation side (right/left eye), air reinjection, rejection episode, cystic macular edema, IOP elevation, and indication for surgery. For details, see [Table 5](#).

**Figure 3** Best spectacle corrected visual acuity (BSCVA) up to 6 years after DMEK (decimal); eyes without comorbidities.



**Figure 4** Best spectacle corrected visual acuity (BSCVA) up to 6 years after DMEK (decimal): eyes with comorbidities.

### Complications

Nineteen eyes out of 162 (11.7%) needed air reinjection (=rebubbling) because of partial graft detachment; two of these eyes underwent this procedure twice. The air reinjection was undertaken when the graft didn't adhere to the stroma centrally or paracentrally at the 1 week review.

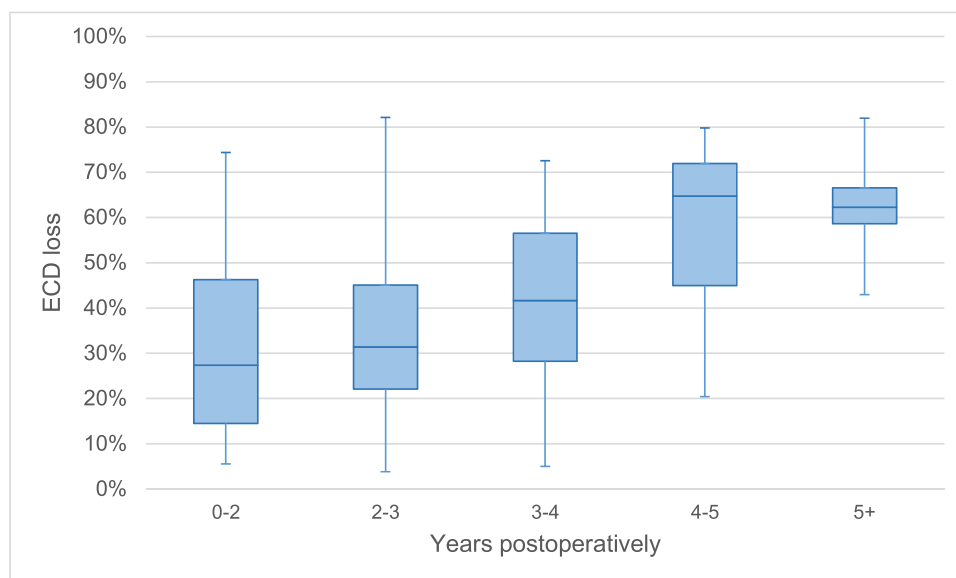
Seven eyes (4.3%) had a primary graft failure and five (3%) had a total graft dislocation. Finally, one eye (0.6%) developed fibrin in the anterior chamber perioperatively and it was not possible to unroll the graft. These 13 eyes (8%) underwent repeat keratoplasty within a few weeks and were subsequently excluded from further analysis.

Of the remaining 149 eyes, four (2.5%) had a clinically proven rejection episode, one of them for the second time. Six eyes (4.02%) developed cystic macular edema. Fifty-five eyes (36.9%) developed ocular hypertension (defined as IOP >21mmHg) during the postoperative follow-up. In most cases, the IOP elevation was steroid-induced. Other complications included iris prolapse (in two eyes; 1.2%), IOL dislocation with vitreous prolapse (one eye; 0.6%), corneal melting at the suture (one eye; 0.6%), and Descemet's membrane wrinkle centrally (one eye; 0.6%).

**Table 4** Endothelial Cell Density (ECD) and Cell Loss – Cross-Sectional Analysis

Years Postoperatively	Number of Eyes	ECD cells/mm <sup>2</sup> Median (Interquartile Range)	ECD loss, % Median (Interquartile Range)
0 (baseline donor)	144	2625 (2500, 2831)	–
1–2	40	2052 (1350, 2402)	27 (15, 46)
2–3	46	1819 (1294, 2178)	31 (22, 45)
3–4	29	1585 (1136, 1949)	42 (29, 57)
4–5	13	822 (703, 1406)	65 (13, 72)
>5	16	982 (830, 1094)	62 (16, 67)

**Abbreviation:** ECD= endothelial cell density;



**Figure 5** Endothelial cell density loss. The boxes are drawn between the 25th and 75th percentiles. The horizontal lines show the median, while the whiskers indicate the minimum and maximum values.

**Abbreviation:** ECD= endothelial cell density.

## Discussion

Endothelial keratoplasty was a developmental milestone in the treatment of endothelial dysfunction diseases.<sup>8</sup> The introduction of DMEK by Melles in 2006<sup>4</sup> provided for additional refining of the surgical technique, with fast visual rehabilitation and a low risk of graft rejection.<sup>6,7</sup>

The Eye Department at the University Hospital in Örebro, Sweden, is the tertiary referral center for corneal diseases in Sweden. The DMEK procedure was introduced at our clinic in 2013 and the number of DMEK surgeries has increased with time. However, the Swedish population of 10.41 million inhabitants is fairly small compared with the population of other countries. This explains why the total number of DMEK procedures in Sweden is relatively small (251 during the period 2013–2018) as compared with larger operation centers abroad. Unlike most of the other studies on the topic<sup>16</sup> we chose to include learning curve cases, which may have impacted our results.<sup>20</sup> Despite that, our visual outcomes are in good agreement with other reports.<sup>11,13,16,21</sup> Altogether 68% of eyes without comorbidities in our cohort achieved 0 logMAR and 17.8% of eyes achieved 0.1 logMAR. This shows that DMEK is an effective technique to restore visual function in our patients.

The median value of 27% and 31%, respectively, for ECD loss 1–2 years and 2–3 years postoperatively corroborates with previous findings.<sup>22,23</sup> After this time, however, the ECD loss in our study was higher than in other reports, especially at >4 years postoperatively (>60%). A possible explanation might be the included learning curve and potential selection bias. Most of the patients lived far from our clinic and those who were completely satisfied with the outcome may have chosen not to participate in the study.

**Table 5** Effects on Endothelial Cell Density (ECD)– Multiple Linear Regression

			95% Confidence Interval for B	
Model	Coefficient B	Significance	Lower Border	Upper Border
(Constant)	−1745,67	0.001	−2793,05	−698,30
Baseline (donor) ECD	1,40	< 0.001	1,04	1,78
Time since surgery (years)	−142,92	< 0.001	−212,27	−73,59

**Notes:** Method: Forward (criterion: probability to enter:  $p \leq 0.05$ ).

**Abbreviation:** Coefficient B= coefficient beta.



Lazaridis et al<sup>24</sup> as well as Hayashi et al<sup>25</sup> reported an association between rebubbling and ECD loss. In contrast to these studies, we found no correlation between rebubbling and diminished ECD. In our study, most eyes received one air reinjection (only one eye out of 19 underwent rebubbling twice). Our finding is in agreement with a previous study by Feng et al<sup>22</sup> in which cell loss was not significantly increased in eyes with a single air reinjection.

Rebubbling rate varies widely from 2.1% reported recently by Fu and Hollick<sup>21</sup>, up to 32.3% in a big cohort of 1541 DMEK surgeries by Siebelmann et al<sup>26</sup> and even higher in earlier studies.<sup>27</sup> We performed rebubbling in 11.7% of cases when the graft was detached centrally or paracentrally at 1 week postoperatively which is earlier as compared to mean 16 days postoperatively according to report by Fu and Hollick.<sup>28</sup> Probably an introduction of a standardized protocol may lead to similar rebubbling rates in different centers in the future.<sup>21</sup>

There were some limitations of the study. The coronavirus pandemic, starting in March 2020, influenced the number of participants and may have contributed to selection bias. There was no continuous follow-up at our clinic as most of the patients had their follow-up at a smaller and less specialized clinic. For this reason, it was not possible to collect ECD data continuously and we performed a cross-sectional study instead. Another limitation of the study was the use of different visual acuity charts preoperatively, at 1 month (Snellen acuity chart), and at the examination time point (ETDRS chart). We decided to use the ETDRS chart in the prospective part of the study as it is a gold standard in clinical research because of the precise quantification of vision and reliable measurements of vision change.<sup>29</sup> The preoperative and 1-month visual acuity data were recorded retrospectively and consequently, we were unable to impact these measurements.

## Conclusions

To sum up, the postoperative DMEK results in Örebro, Sweden, are promising. Further studies with even longer follow-up times are needed to evaluate graft function durability.

## Statement of Ethics

The study was conducted according to the Declaration of Helsinki. The patient consent statement was collected from all participants. The study was approved by the Swedish Ethical Review Authority (Dnr: 2019-01931).

## Acknowledgments

Parts of the study were presented at the Nordic Congress of Ophthalmology 2022.

We would like to thank Yang Cao, Ph.D., Associate Professor in Biostatistics, Clinical Research Centre, Örebro University Hospital, for advice on the statistical method, and Tomasz Kloda, MSc, for assistance with statistics. Our thanks also go to Linnea Forsgren-Piuva, Certified Optician, Department of Ophthalmology at Örebro University Hospital, for examining the patients. We would like to thank Marita Andersson-Grönlund, Professor in Ophthalmology at Örebro University Hospital for practical guidance. We are grateful to Jessica Eriksson and Cecilia Broström, Care Administrators, Department of Ophthalmology, Örebro University Hospital, for the organization and technical support.

## Funding

This research was supported by the Research Committee in Örebro Region, Sweden.

## Disclosure

The authors have no conflicts of interest to declare in this work.

## References

1. Stuart AJ, Romano V, Virgili G, et al. Descemet's membrane endothelial keratoplasty (DMEK) versus Descemet's stripping automated endothelial keratoplasty (DSAEK) for corneal endothelial failure (review). *Cochrane Database Syst Rev*. 2018;6(6):1.
2. Guerra FP, Anshu A, Price MO, et al. Descemet's membrane endothelial keratoplasty. Prospective study of 1-year visual outcomes, graft survival and endothelial cell loss. *Ophthalmol*. 2011;118(12):2368–2373. doi:10.1016/j.ophtha.2011.06.002
3. Maier AK, Gundlach E, Gonnermann J, et al. Retrospective contralateral study comparing Descemet membrane endothelial keratoplasty with Descemet stripping automated endothelial keratoplasty. *Eye*. 2015;29(3):327–332. doi:10.1038/eye.2014.280



4. Melles GRJ, Ong TS, van der Wees J. Descemet membrane endothelial keratoplasty (DMEK). *Cornea*. 2006;25(8):987–990. doi:10.1097/01.ico.0000248385.16896.34
5. Chamberlain W, Lin CC, Austin A, et al. Descemet endothelial thickness comparison trial. A randomized trial comparing ultrathin Descemet stripping automated endothelial keratoplasty with Descemet membrane endothelial keratoplasty. *Ophthalmol*. 2019;126(1):19–26. doi:10.1016/j.ophtha.2018.05.019
6. Anshu A, Price MO, Price FW. Risk of corneal transplant rejection significantly reduced with Descemet's membrane endothelial keratoplasty. *Ophthalmol*. 2012;119(3):536–540. doi:10.1016/j.ophtha.2011.09.019
7. Price DA, Kelley M, Price FW, et al. Five-year graft survival of Descemet membrane endothelial keratoplasty versus Descemet stripping EK and the effect of donor sex matching. *Ophthalmol*. 2018;125(10):1508–1514. doi:10.1016/j.ophtha.2018.03.050
8. Price MO, Feng MT, Price FW. Endothelial keratoplasty update 2020. *Cornea*. 2021;40(5):541–547. doi:10.1097/ICO.0000000000002565
9. Ćirković A, Schlötzer-Schrehardt U, Weller JM, et al. Clinical and ultrastructural characteristics of graft failure in DMEK: 1 year-results after repeat-DMEK. *Cornea*. 2015;34(1):11–17. doi:10.1097/ICO.0000000000000295
10. Tourtas T, Laaser K, Bachmann BO, et al. Descemet membrane endothelial keratoplasty versus Descemet stripping automated endothelial keratoplasty. *Am J Ophthalmol*. 2012;153(6):1082–1090. doi:10.1016/j.ajo.2011.12.012
11. Schlögl A, Tourtas T, Kruse FE, et al. Long-term clinical outcome after Descemet Membrane Endothelial Keratoplasty. *Am J Ophthalmol*. 2016;169:218–226. doi:10.1016/j.ajo.2016.07.002
12. Price MO, Giebel AW, Fairchild KM, et al. Descemet's membrane endothelial keratoplasty: prospective multicenter study of visual and refractive outcomes and endothelial survival. *Ophthalmol*. 2009;116(12):2361–2368. doi:10.1016/j.ophtha.2009.07.010
13. Dunker SL, Armitage WJ, Armitage M, et al. Practice patterns of corneal transplantation in Europe: first report by the European cornea and cell transplantation registry. *J Cataract Refract Surg*. 2021;47(7):865–869. doi:10.1097/j.jcrs.0000000000000574
14. Deng SX, Lee WB, Hammersmith KM, et al. Descemet Membrane Endothelial Keratoplasty: safety and outcomes, a report by the American Academy of ophthalmology. *Ophthalmol*. 2018;125(2):295–310. doi:10.1016/j.ophtha.2017.08.015
15. Jansen C, Zetterberg M. Descemet membrane endothelial keratoplasty versus Descemet stripping automated keratoplasty – outcome of one single surgeon's more than 200 initial consecutive cases. *Clin Ophthalmol*. 2021;15:909–921. doi:10.2147/OPTH.S289730
16. Birbal RS, Dhuhghaill SN, Bourgonje VJ, et al. Five-year survival and clinical outcomes of 500 consecutive cases after Descemet membrane endothelial keratoplasty. *Cornea*. 2020;39(3):290–297. doi:10.1097/ICO.0000000000002120
17. Official Statistics of Sweden, population by region 1968–2021. Available from: [www.statistikdatabasen.scb.se](http://www.statistikdatabasen.scb.se). Accessed December 19, 2023.
18. Low vision acuity chart start. Available from: [www.syntavlor.se/SYNTAVLOR/produktbeskrivningar/lagvisus.html](http://www.syntavlor.se/SYNTAVLOR/produktbeskrivningar/lagvisus.html). Accessed December 19, 2023.
19. Lentzsch AM, Adler W, Siebelmann S, et al. Impact of early intraocular pressure elevation on postoperative outcomes after Descemet membrane endothelial keratoplasty in non-glaucoma patients. *Cornea*. 2022;41(1):83–88. doi:10.1097/ICO.0000000000002778
20. Monnereau C, Quilendrin R, Dapena I, et al. Multicenter study of DMEK: the first case series of 18 surgeons. *JAMA Ophthalmol*. 2014;132(10):1192–1198. doi:10.1001/jamaophthalmol.2014.1710
21. Fu L, Hollick EJ. Comparison of long-term outcomes of DSEK and DMEK in Fuchs endothelial dystrophy. *Cornea*. 2024;43(2):184–189. doi:10.1097/ICO.0000000000003310
22. Feng MT, Price MO, Miller JM, et al. Air reinjection and endothelial cell density in Descemet membrane endothelial keratoplasty: five-year follow-up. *J Cataract Refract Surg*. 2014;40(7):1116–1121. doi:10.1016/j.jcrs.2014.04.023
23. Gorovoy IR, Gorovoy MS. Descemet membrane endothelial keratoplasty postoperative year 1 endothelial cell counts. *Am J Ophthalmol*. 2015;159(3):597–600. doi:10.1016/j.ajo.2014.12.008
24. Lazaridis A, Fydanaki O, Giallouras E, et al. Recovery of corneal clarity after DMEK followed by rebubbling versus uneventful DMEK. *Cornea*. 2018;37(7):840–847. doi:10.1097/ICO.0000000000001554
25. Hayashi T, Schrittenlocher S, Siebelmann S, et al. Risk factors for endothelial cell loss after Descemet membrane endothelial keratoplasty (DMEK). *Sci Rep*. 2020;10(1):11086. doi:10.1038/s41598-020-68023-0
26. Siebelmann S, Kolb K, Scholz P, et al. The Cologne rebubbling study: a reappraisal of 624 rebubbings after Descemet membrane endothelial keratoplasty. *Br J Ophthalmol*. 2021;105(8):1082–1086. doi:10.1136/bjophthalmol-2020-316478
27. Laaser K, Bachmann BO, Horn FK, et al. Descemet membrane endothelial keratoplasty combined with phacoemulsification and intraocular lens implantation: advanced triple procedure. *Am J Ophthalmol*. 2012;154:47–55. doi:10.1016/j.ajo.2012.01.020
28. Fu L, Hollick EJ. Rebubbling and graft detachment in Descemet membrane endothelial keratoplasty using a standardised protocol. *Eye*. 2023;37(12):2494–2498. doi:10.1038/s41433-022-02362-2
29. Kaiser PK. Prospective evaluation of visual acuity assessment: a comparison of Snellen versus ETDRS charts in clinical practice. *Trans Am Ophthalmol Soc*. 2009;107:311–324.

## Clinical Ophthalmology

Dovepress

## Publish your work in this journal

Clinical Ophthalmology is an international, peer-reviewed journal covering all subspecialties within ophthalmology. Key topics include: Optometry; Visual science; Pharmacology and drug therapy in eye diseases; Basic Sciences; Primary and Secondary eye care; Patient Safety and Quality of Care Improvements. This journal is indexed on PubMed Central and CAS, and is the official journal of The Society of Clinical Ophthalmology (SCO). The manuscript management system is completely online and includes a very quick and fair peer-review system, which is all easy to use. Visit <http://www.dovepress.com/testimonials.php> to read real quotes from published authors.

Submit your manuscript here: <https://www.dovepress.com/clinical-ophthalmology-journal>