

Intravitreal Injection of Conbercept Combined with Dexamethasone for Macular Edema Following Central Retinal Vein Occlusion

Peipei Wu¹, Panpan Zhang¹, Jing Xu¹, Wenhui Ma¹, Longfei Li², Haifeng Xu¹

¹Department of Uveitis, Eye Institute of Shandong First Medical University, Qingdao Eye Hospital of Shandong First Medical University, Qingdao, People's Republic of China; ²College of Energy and Mining Engineering, Shandong University of Science and Technology, Qingdao, People's Republic of China

Correspondence: Haifeng Xu, Qingdao Eye Hospital, Shandong Eye Institute, Shandong First Medical University & Shandong Academy of Medical Science, 5 Yanerdao Road, Qingdao, 266071, People's Republic of China, Tel +86 13906391451, Fax +86 0532 85891110, Email chxhf@126.com

Background: To compare the efficacy of intravitreal injections of Conbercept combined with dexamethasone (DEX) for macular edema (ME) following central retinal vein occlusion (CRVO).

Methods: This was a prospective, single-masked, randomised, controlled clinical trial. Patients with ME following CRVO were randomised into groups to receive intravitreal injections of 0.5 mg Conbercept plus 0.2 mg DEX or 0.5 mg Conbercept alone on day 0 followed by repeat injections as indicated. The primary outcome measure was the change in best-corrected visual acuity (BCVA) from baseline to month 12. Secondary outcome measures included decrease in central retinal thickness (CRT), injection frequency and interval and percentage of patients who gained more than 15 ETDRS letters or achieved a CRT of < 250 µm at month 12.

Results: 33 males (51%) and 32 females (49%) were initially recruited with an average age of 56.64 ± 13.88 years. Patients in the Conbercept and Conbercept + DEX groups gained an average of 14.55 ± 19.19 and 14.88 ± 17.68 ETDRS letters, respectively, at months 12 ($t = 4.221$, $P = 0.000$; and $t = 4.834$, $P = 0.000$) with no significant difference between the two groups ($t = 0.071$, $P = 0.943$). In the Conbercept group, the mean reduction in CRT from baseline to month 12 was 435.26 ± 293.37 µm ($t = 8.261$, $P = 0.000$) compared to 431.36 ± 294.55 ($t = 8.413$, $P = 0.000$) in the Conbercept + DEX group. There was no significant difference between the two groups ($t = 0.053$, $P = 0.958$). The Conbercept + DEX group received fewer intravitreal injections. No major complications occurred.

Conclusion: Conbercept, alone or with DEX, can improve BCVA and reduce CRT in ME following CRVO without serious adverse events. The treatment interval was longer in the Conbercept + DEX group.

Trial Registration: The study was registered with the Chinese Clinical Trial Registry at 5 July 2017. (<http://www.chictr.org.cn>, 05/07/2017 Registration Number: ChiCTR-INR-17011877).

Keywords: conbercept, dexamethasone, macular edema, retinal vein occlusion

Background

The prevalence of retinal vein occlusion (RVO) is estimated to be 5.20 per 1000, with a central RVO (CRVO) prevalence of 0.80 per 1000.¹ CRVO is characterised by retinal vein tortuosity, extensive retinal haemorrhaging, optic disc haemorrhaging and macular oedema (ME). One of the most common complications is secondary ME, which often leads to an abrupt decrease in visual acuity (VA). If CRVO is not promptly treated, the prognosis in terms of vision is poor, and complications such as neovascular glaucoma may occur.

Previous studies found that vascular endothelial growth factor (VEGF), the main factor promoting vascular leakage and secondary ME, was significantly increased in various types of retinal ischaemic diseases, including CRVO.^{2,3} Multicentre randomised controlled clinical trials have shown that intravitreal anti-VEGF injections can effectively reduce ME and improve VA.^{4–6}

In eyes with CRVO, activated and migrated microglia release many inflammatory cytokines. Additionally, inflammation causes Muller cell dysfunction, decreased intracellular fluid clearance and aggravated retinal intracellular oedema.⁷ Dexamethasone is a corticosteroid that stabilises retinal vessel tight junctions and decreases ME by inhibiting inflammation and indirectly activating anti-VEGF.⁸ Currently, the intravitreal injection of corticosteroids (sustained-release dexamethasone, Ozurdex) and anti-VEGF drugs is recommended as the first-line treatment for ME secondary to CRVO.^{5–7,9–12}

Conbercept is a recombinant anti-VEGF fusion protein engineered from a full human cDNA sequence in Chinese hamster ovary cells. In China, Conbercept has been approved for choroidal neovascularisation secondary to wet age-related macular degeneration and pathological myopia. Conbercept's in vivo safety and efficacy as an angiogenesis inhibitor have been confirmed.^{13–17}

Dexamethasone sodium phosphate injection is a sterile medication that contains dexamethasone, a synthetic glucocorticoid hormone. It possesses anti-inflammatory, anti-allergic, and immunosuppressive capabilities. This medication can suppress the inflammatory response, curtail the migration and activation of inflammatory cells, and lower the release of inflammatory mediators, thereby reducing the immune reactions associated with autoimmune diseases.

Intractable ME secondary to CRVO often recurs after anti-VEGF treatment, requiring repeated treatments to maintain VA. At present, the recommended treatment for anti-VEGF drugs is 3–6 monthly treatments at first, followed by pro re nata (PRN) treatment.^{6,7} The Standard Care vs The Corticosteroid for Retinal Vein Occlusion (SCORE) study demonstrated that Ozurdex (0.7 mg dexamethasone) implants every 4 months could improve VA and central retinal thickness (CRT) relative to the values in the observation group.^{9–12} Although many clinical trials have demonstrated the effectiveness and safety of anti-VEGF drugs and dexamethasone implants, repeated therapy imposes a considerable financial burden on patients and society.

Therefore, we designed a trial to assess the efficacy of intravitreal injections of Conbercept combined with 0.04 mL: 0.2 mg DEX sodium phosphate injection in the treatment of ME secondary to CRVO to determine whether the combined therapy could extend the treatment interval and reduce the number of injections while maintaining the benefits of VA.

Methods

Study Design

This study was a prospective, randomised clinical trial that involved initial intravitreal injections for treatment-naïve ME secondary to CRVO. All injections were undertaken at the Shandong Eye Institute, Qingdao Eye Hospital, between July 2017 and May 2022. The study was approved by the Institutional Review Board of Shandong Eye Institute, Qingdao Eye Hospital and was conducted in accordance with the tenets of the Declaration of Helsinki. The study included a 7-day baseline and a 12-month follow-up period. In the 7-day baseline period, all participants underwent detailed ophthalmic examinations. Clinical and demographic variables, including age, interval between onset and treatment and history of hypertension and diabetes mellitus, were recorded. Patients who met the inclusion criteria and provided informed consent were randomly assigned to the Conbercept (Lumitin, Chengdu Kang Hong Biotech Co, Ltd., Sichuan, People's Republic of China) or the Conbercept+DEX group and received the intravitreal injection. In order to evaluate the optimal intervals between injections, the study adopted a protocol of a single initial intravitreal injection complemented by subsequent injections on a pro re nata (as needed) basis, denoted as 1+PRN. BCVA and the average CRT before, 1 week after and 1 month after each injection were recorded. Patients with three injections and VA worse than the 20 Early Treatment Diabetic Retinopathy Study (ETDRS) letters were examined by fluorescein fundus angiography (FFA) and administered photocoagulation if the nonperfusion areas (NPA) were more than 10 optic disk areas.

Screening, Eligibility and Randomisation

Eligibility was determined by the investigators according to the diagnostic criteria of ME secondary to CRVO; the criteria were as follows: the rapid decrease of VA, a tortuous retinal vein, optic disc haemorrhaging and oedema, extensive retinal haemorrhaging and ME. Inclusion criteria were as follows: (1) age > 18 years; (2) diagnosis of ME secondary to CRVO; (3) BCVA < 20/40 and (4) mean CRT > 250 µm. BCVA was measured by the ETDRS vision chart at 2 m; mean CRT was measured by optical coherence tomography (OCT) scans within a scope of 1 mm in diameter. Exclusion criteria were as follows: (1) participation in other clinical trials within 3 months before the study; (2) previous

intraocular surgical laser for any other retinal diseases, intravitreal anti-VEGF in the fellow eye or steroid treatment in any form within 3 months; (3) obvious afferent pupillary defect; (4) any previous ocular condition that may be associated with the risk of ME, such as diabetic retinopathy and uveitis; (5) uncontrolled hypertension, renal failure or mental illness and (6) any medical history that may interfere with the results of the trial or increase the patient risk, such as primary glaucoma and severe cataract.

Eyes were randomly allocated into either group by computer-generated random number table. Participants, care providers and those who assessing outcomes were blinded after assignment to interventions. One eye was chosen as the study eye for each patient. If both eyes met the inclusion criteria, the eye with the worse BCVA was selected. The patients, VA and CRT examiners and evaluating clinicians were masked during the treatment. We certify that all applicable institutional and governmental regulations concerning the ethical use of human volunteers were followed during this trial.

Intravitreal Injections

Patients received an intravitreal injection on day 0 and then as and when required. Injection procedures were performed in accordance with previously established guidelines.¹⁸ Antibiotic eye drops (more than 8 administrations) were used 3 days before treatment. The conjunctival sac was cleaned with 5% povidone iodine, and anaesthesia was induced with 2% lidocaine before injection. A 30-gauge needle was inserted through the pars plana. In the Conbercept+DEX group, the patient received intravitreal injection of Conbercept and DEX for each injection. Initially, 0.5 mg of Conbercept was injected at the 10 o'clock position, followed by the injection of 0.2 mg DEX at the 11 o'clock position. The Conbercept group received intravitreal injection of 0.5 mg Conbercept and a needleless hub as the second injection. VA and intraocular pressure (IOP) were examined after injection.

Follow-Up and Repeated Treatment

All participants received detailed ophthalmic examinations at 1 day, 7 days and 1 month after each intravitreal injection during the 12-month follow-up period. The clinical data collected included BCVA and CRT. All participants were monitored daily for visual acuity. In cases of vision deterioration, the decision to proceed with intravitreal injections was guided by established repeat treatment criteria. The criteria for repeated treatment were a central macular thickness ≥ 250 μm measured on OCT accompanied by visual loss > 5 ETDRS letters from the previous follow-up. At month 12 (the last follow-up), BCVA, CRT and other ophthalmic parameters were recorded. If the patient received photocoagulation, FFA was conducted, and supplementary photocoagulation was performed if needed.

Outcome Measures

The primary outcome measure was the mean change in BCVA from baseline to month 12. Secondary outcome measures included the decrease in the mean CRT from baseline to month 12, injection frequency and intervals, percentage of patients who gained more than 15 letters at month 12 and percentage of patients with CRT less than 250 μm at month 12. The safety outcome measures included secondary elevation of IOP, neovascular glaucoma and intercurrent cataracts. Other ocular and systemic adverse events or serious adverse events were also recorded.

CRT was measured by spectral domain OCT (Spectralis, Heidelberg Engineering, Heidelberg, Germany). The OCT image was based on the average of 100 scans derived using an automatic averaging function to reduce speckle noise and a real-time eye tracking system. The mean CRT was measured as the average macular thickness within a 1 mm circle centred on the fovea.

Safety evaluations included severity evaluations of cataracts on biomicroscopy using the Age-Related Eye Disease Study Clinical Lens Grading System¹⁹ at baseline and the 12-month follow-up. VA was measured using ophthalmic examinations with an ETDRS standard visual acuity chart, and IOP was measured with a Goldmann applanation tonometer before and 1 day, 7 days and 1 month after intravitreal injections. A treatment emergent adverse event (TEAE) was defined as an adverse event that occurred during treatment having not been absent at baseline or worsened relative to the pre-treatment state.

Statistical Analysis

Variables are expressed as mean \pm standard deviation (SD) or median (range or interquartile range). The last observation carried forward was used to impute missing values in the follow-up periods, but no significant differences were observed using other approaches to account for missing data. Changes in CRT and BCVA between time points within each treatment group were analysed using a mixed model for repeated measurements and compared using Wilcoxon test results. Student's *t*-test was used to evaluate differences in the changes in CRT and BCVA from baseline between the two treatment groups. The chi-squared test was used to evaluate baseline differences between the two groups. Injection frequency and intervals were compared using the Mann–Whitney test. Pearson's correlation analysis was used to analyse the correlation between treatment intervals. The null hypothesis was rejected for *P*-values less than 0.05.

Results

Sixty-five eyes were initially recruited into the clinical trial; the patients included 33 males (51%) and 32 females (49%) with an average age of 56.64 ± 13.88 years (range 21–83). Forty-one (63%) patients had hypertension, and 10 (15%) patients had a history of diabetes, but no diabetic retinopathy or diabetic ME was detected. There was no dysfunction in coagulation or infectious disease such as HIV or infection caused by *Treponema pallidum*, hepatitis B virus or hepatitis C virus at the baseline. The mean time from conscious loss of VA to intravitreal injection was 21 (3–185) days. The mean baseline BCVA letter score for the study eyes was 37.06 ± 16.75 , and the mean baseline CRT was 730.17 ± 259.89 μ m. The demographic and clinical characteristics of the two groups were similar (Table 1). Forty-one patients received more

Table 1 Demographic and Baseline Characteristics of Patients Who Received Conbercept Plus Dexamethasone (DEX) or Conbercept Alone for Macular Edema Secondary to Central Retinal Vein Occlusion

| | Conbercept (n = 32) | Conbercept+DEX (n = 33) |
|---------------------------------------|------------------------|----------------------------|
| Age | | |
| Mean \pm SD | 55.31 \pm 12.14 | 57.91 \pm 15.42 |
| Median | 56 | 59 |
| Range | 27–77 | 21–83 |
| Sex, n (%) | | |
| Male | 17 (53%) | 16 (48%) |
| Female | 15 (47%) | 17 (53%) |
| Hypertension, n (%) | 18 (56%) | 23 (70%) |
| DM, n (%) | 5 (16%) | 5 (15%) |
| Days from CRVO diagnosis to screening | | |
| Median | 24 | 28 |
| Range | 7–183 | 5–180 |
| Distribution, n (%) | | |
| \leq 1 month | 21 (66%) | 22 (67%) |
| 1–3 months | 9 (28%) | 9 (27%) |
| \geq 3 months | 2 (6%) | 2 (6%) |
| BCVA | | |
| ETDRS letter score | | |
| Mean \pm SD | 37.97 \pm 17.38 | 35.85 \pm 16.09 |
| Distribution, n (%) | | |
| \leq 34 | 14 (44%) | 16 (48%) |
| 35–54 | 11 (34%) | 10 (30%) |
| \geq 55 | 7 (22%) | 7 (21%) |
| CRT (μ m) | | |
| Mean \pm SD | 742.59 \pm 275.83 | 718.48 \pm 247.70 |

Abbreviations: DM, diabetes mellitus; BCVA, best-corrected visual acuity; CRT, central retinal thickness; ETDRS, Early Treatment Diabetic Retinopathy Study; CRVO, central retinal vein occlusion; SD, standard deviation.

than three intraocular injections, and 26 of them underwent FFA. Six patients with NPA >10 PD in FFA were treated with panretinal laser photocoagulation (three patients per group), and four cases of neovascular glaucoma were detected during the 12-month follow-up, with an average of 291 days from baseline to neovascular glaucoma.

The follow-up study included 64 eyes, as one patient from the initial cohort in the Conbercept group was lost to follow-up because he relocated to another city.

Visual Acuity

Patients in the Conbercept and Conbercept + DEX groups gained an average of 14.55 ± 19.19 and 14.88 ± 17.68 ETDRS letters, respectively, at the final follow-up (12 months; resp. $t = 4.221$, $P = 0.000$; and $t = 4.834$, $P = 0.000$) with no significant difference between the two groups ($t = 0.071$, $P = 0.943$). Fifteen patients in the Conbercept group (48%) and 15 in the Conbercept + DEX group (45%) gained ≥ 15 ETDRS letters from baseline. Four participants (6%), including two (6%) in the Conbercept group and two (6%) in the Conbercept + DEX group, lost more than 15 ETDRS letters at the final follow-up. The percentage of participants who obtained more than 60 ETDRS letters (equivalent to 20/40 in the Snellen chart) was 42% in the Conbercept group and 42% in the Conbercept + DEX group. There was no significant difference between the two groups ($\chi^2 = 0.500$, $P = 0.779$).

BCVA at 1 week and 1 month after each intravitreal injection was improved compared to that before therapy ($P < 0.01$). There were no significant differences in BCVA between 1 week and 1 month, except after the second injection in the Conbercept + DEX group and the fourth injection in the Conbercept group. BCVA changes throughout the 12 months in the two groups are shown in Table 2. BCVA changes at 1 week and 1 month after each injection are shown in Supplemental Digital Content 1.

Central Retinal Thickness

Each intravitreal injection led to a reduction in CRT for all patients. At day 7 after the first intravitreal injection, the mean CRT reduction was 384.16 ± 237.85 μm , while it was 393.58 ± 275.70 μm at 1 month. At month 12, the mean reduction in CRT was $296.92.00 \pm 146.15$ μm . In the Conbercept group, the mean reduction in CRT from baseline to month 12 was 435.26 ± 293.37 μm ($t = 8.261$, $P = 0.000$) compared to 431.36 ± 294.55 ($t = 8.413$, $P = 0.000$) in the Conbercept + DEX group. There was no significant difference between the two groups ($t = 0.053$, $P = 0.958$). The mean CRT was $297.00 \pm$

Table 2 Changes in the Best-Corrected Visual Acuity from Baseline to Month 12 in Patients Who Received Conbercept Plus Dexamethasone (DEX) or Conbercept Alone for Macular Edema Secondary to Central Retinal Vein Occlusion

| | Conbercept (n= 31) | Conbercept+DEX (n= 33) |
|---|---------------------------|---------------------------|
| ETDRS Letter | | |
| Mean \pm SD | 51.61 ± 20.90 | 51.42 ± 23.78 |
| Difference in means (vs baseline) | 14.55 ± 19.19 | 14.88 ± 17.68 |
| t, P (vs baseline) | $t = 4.221$, $P = 0.000$ | $t = 4.834$, $P = 0.000$ |
| Distribution of BCVA change at month 6, n (%) | | |
| Gain (ETDRS letters) | | |
| ≥ 15 | 15 (48%) | 15 (45%) |
| 10–14 | 5 (16%) | 6 (18%) |
| 5–9 | 2 (6%) | 5 (15%) |
| No change, ± 4 ETDRS letters | 3 (10%) | 3 (9%) |
| Loss (ETDRS letters) | | |
| 5–9 | 3 (10%) | 2 (6%) |
| 10–14 | 1 (3%) | 0 |
| ≥ 15 -letter loss | 2 (6%) | 2 (6%) |
| ≥ 15 -letter gain | | |

(Continued)

Table 2 (Continued).

| | Conbercept (n= 31) | Conbercept+DEX (n= 33) |
|------------------|-----------------------|---------------------------|
| First injection | | |
| N | 31 | 33 |
| 7-day | 11 (35%) | 16 (48%) |
| 1-month | 16 (52%) | 17 (52%) |
| Second injection | | |
| N | 29 | 31 |
| 7-day | 11 (38%) | 12 (39%) |
| 1-month | 14 (48%) | 16 (52%) |
| Third injection | | |
| N | 17 | 24 |
| 7-day | 9 (53%) | 13 (54%) |
| 1-month | 7 (41%) | 16 (67%) |

119.21 μm in the Conbercept group and $296.85 \pm 169.50 \mu\text{m}$ in the Conbercept + DEX group after 12 months ($t = 0.004$, $P = 0.997$). The percentage of patients with CRT less than 250 μm at month 12 was 42% in the Conbercept + DEX group and 45% in the Conbercept group. At 1 month after injection, CRT was significantly reduced relative to that at 1 week after the first and third intravitreal injections in the Conbercept + DEX group ($P < 0.05$); following the second injection for the Conbercept group, CRT at 1 month was higher than at 1 week ($360.97 \pm 167.57 \mu\text{m}$ vs $297.69 \pm 55.62 \mu\text{m}$, $P < 0.05$). CRT before treatment and at 1 week and 1 month after intravitreal injection in the first three therapies is shown in [Supplemental Digital Content 2](#).

Injection Frequency and Intervals

Sixty-four patients received 5.13 ± 1.96 intravitreal injections, and 60 eyes (94%) received repeat treatments. The mean treatment interval was 70.48 ± 48.52 days. The second, third and fourth intravitreal injections were administered at 60.10 ± 22.96 , 114.20 ± 33.14 and 182.18 ± 62.49 days, respectively. Patients in the Conbercept + DEX group received 4.82 ± 1.94 intravitreal injections compared to 5.45 ± 1.95 intravitreal injections in the Conbercept group ($Z = -2.674$, $P = 0.007$). Patients in the Conbercept + DEX group received the third and fourth intravitreal injections later than patients in the Conbercept group (125.13 ± 20.72 , 209.40 ± 67.59 in the Conbercept + DEX group; 92.82 ± 32.09 , 161.14 ± 52.32 in the Conbercept group; $P < 0.01$, $P = 0.032$, respectively). The first injection interval (injection 1 to 2) was positively correlated with the second injection interval (injection 2 to 3; Pearson's $r = 0.464$, $P = 0.002$; [Figure 1](#)). The second injection interval in the Conbercept + DEX group was longer than in the Conbercept group ($P = 0.000$). Intravitreal injection frequency and intervals in the two groups are shown in [Table 3](#).

Safety

A total of 328 intravitreal injections was carried out in this study, with 169 for the Conbercept group and 159 for the Conbercept + DEX group, respectively. The most frequent TEAEs were conjunctival haemorrhaging and conjunctival hyperaemia. There was no systemic treatment-related adverse event. Obviously aggravated cataracts were reported in four of the 64 patients (6.25%) and two cases in each group. No study eye accepted cataract surgery during the 12-month study period. Four patients in each group had an increase in IOP ($>25 \text{ mmHg}$) on the first day after intravitreal injection; in one case, the elevated IOP persisted for more than one week. IOP elevations were controlled with IOP-lowering medication. No glaucoma surgeries were performed during the 12-month study period. One case of vitreous haemorrhaging was recorded in the Conbercept group, which completely resolved without therapy during the 12-month follow-up period.

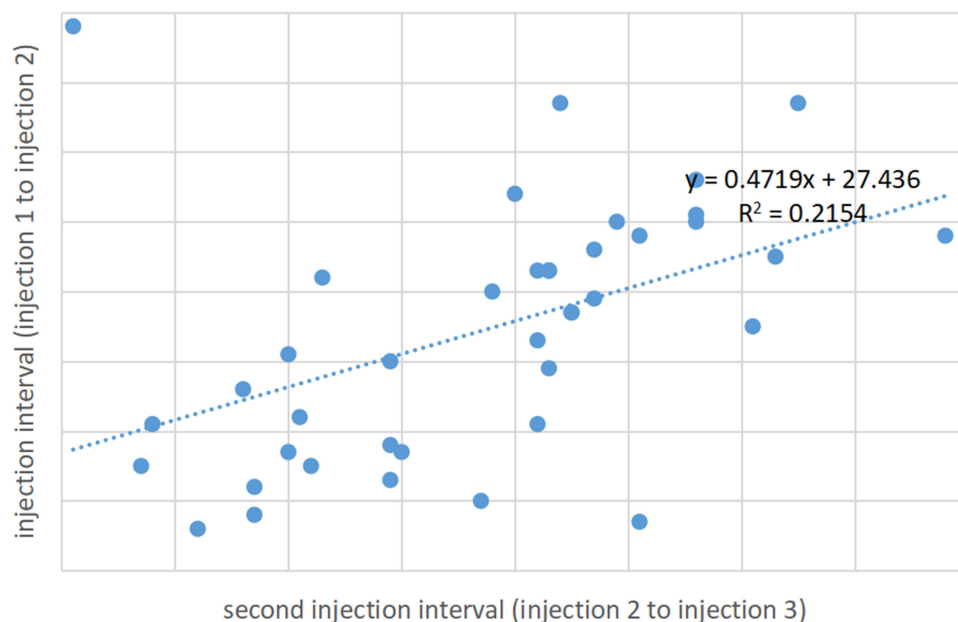


Figure 1 Correlation between the first and second intravitreal injection intervals in patients who received Conbercept + dexamethasone or Conbercept alone for macular oedema secondary to central retinal vein occlusion.

Discussion

This trial explored the safety and efficacy of intraocular injection of Conbercept, alone or combined with DEX, in a 1 + PRN regimen in the treatment of Chinese patients with ME secondary to CRVO. VA improved and ME decreased in both groups at 12 months. Compared to the CRUISE study in which a monthly injection in the first 6 months and PRN afterwards of 0.5 mg ranibizumab led to a mean gain of 13.9 ETDRS letters, patients in this trial gained 14.55 ± 19.19 ETDRS letters after 5.52 ± 1.96 intravitreal injections. We adopted a 1 + PRN administration schedule rather than monthly injections to reduce the economic burden. Although BCVA fluctuated during the 12-month follow-up, patients gained BCVA improvement with fewer injections compared with the CRUISE study. The better BCVA benefits are probably attributable to the younger age of participants (56.64 ± 13.88 compared to 67.6 ± 12.4 in the CRUISE study) and the shorter duration of onset to intravitreal injection (21 (3–185) days) compared with 3.3 ± 3.7 months in the CRUISE study.⁵ Corticosteroids reduce vascular permeability and inhibit blood–retinal barrier destruction by down-regulating ICAM-1 and VEGF, reducing leukocyte adhesion and increasing tight junction protein levels in retinal endothelial cells.^{20,21} Glucocorticoids bind to retinal Muller cell receptors to clear extracellular fluid and alleviate ME. Therefore, intravitreal corticosteroids have been employed in the treatment of secondary ME since the early 2000s.²² We chose DEX rather than triamcinolone acetonide (TA) as an adjuvant drug in the current study because DEX has a shorter half-life in the vitreous body and causes fewer corticosteroid-related complications than TA. Furthermore, several studies have demonstrated the efficacy of DEX implants for the treatment of ME associated with CRVO.^{23–25} Although

Table 3 Intravitreal Injection Frequency and Intervals for Patients Who Received Conbercept Plus Dexamethasone (DEX) or Conbercept Alone for Macular Edema Secondary to Central Retinal Vein Occlusion

| | Conbercept group (n = 31) | Conbercept+DEX group (n = 33) | t | P |
|--|---------------------------|-------------------------------|-------|-------|
| Frequency, Mean \pm SD | 5.52 \pm 1.96 | 4.82 \pm 1.94 | 1.302 | 0.198 |
| Second intravitreal injection (First injection interval) | 59.14 \pm 30.90 | 61.00 \pm 11.98 | 0.304 | 0.763 |
| Third intravitreal injection | 92.82 \pm 32.09 | 125.13 \pm 20.72 | 3.919 | <0.01 |
| Fourth intravitreal injection | 161.14 \pm 52.32 | 209.40 \pm 67.59 | 2.239 | 0.032 |
| Second injection interval | 45.29 \pm 16.84 | 65.75 \pm 12.57 | 4.457 | 0.000 |

Conbercept + DEX treatment required more injections compared to DEX implants, it led to a greater gain in terms of BCVA letters, and its effect was faster than that of DEX implants. Additionally, the main TEAEs, such as conjunctival haemorrhaging, conjunctival hyperaemia, conjunctival oedema, pain, and vitreous haemorrhaging, were injection related TEAEs rather than drug related TEAEs. Complications of cataracts and an increase in IOP, which were reported in Ozurdex recipients,²⁶ did not differ between the two groups in this case series.

We observed a significant positive correlation between the intervals of the first and second intravitreal injections, indicating that patients whose treatment intervals were longer after the initial injection also experienced longer intervals before their second injection (*Pearson's* $r = 0.464$, $P = 0.002$). This finding suggests that the response to the initial injection of Conbercept, with or without DEX, may influence the subsequent treatment schedule. Notably, the Conbercept + DEX group exhibited a longer second injection interval compared to the Conbercept group alone ($P = 0.000$), which may reflect the combined therapy's enhanced efficacy in controlling the disease progression and thus allowing for a more extended period between treatments.

The extended treatment intervals observed in the Conbercept + DEX group could have significant implications for patient care, potentially reducing the frequency of office visits and injections, and improving patient compliance and quality of life. However, it is important to continue monitoring patients closely to ensure timely intervention when necessary. These results underscore the importance of personalized treatment schedules based on individual patient responses. Future studies may benefit from investigating the factors that contribute to these varying treatment intervals, including the role of combined therapy with Conbercept and DEX in sustained disease management.

During the natural course of RVO, the occlusion of retinal capillaries resulting from ischaemia might be gradually aggravated. In a previous study [9], non-ischaemic CRVOs converted to ischaemic ones, defined as NPA > 10 PD, in 15% of the patients in the first 4 months of follow-up, while the proportion increased to 34% at the end of 3 years. In our study, six eyes (9%) met the criteria for ischaemic CRVO. They were treated with panretinal laser photocoagulation, and four cases of neovascular glaucoma were detected after 291 days on average during the 12 months of follow-up. Therefore, intravitreal injection of Conbercept reduces the occurrence of nonischaemic–ischaemic shifts and the risk of neovascularisation. The introduction of DEX did not help improve retina reperfusion and avoid photocoagulation, as there was no difference between the two groups. However, the proportion of patients needing panretinal photocoagulation in the Conbercept + DEX group was smaller than that reported for Ozurdex implantation (9% vs 15%).²³

Conclusions

In summary, although there was no difference in BCVA improvement and CRT reduction between Conbercept alone and Conbercept + DEX at 12 months, patients in the Conbercept + DEX group received fewer intraocular injections. The combined therapy thus extends the intervals between treatments, leading to a decrease in the economic burden and physical suffering of the patients. In this trial, we also observed that the first injection interval was positively correlated with the second injection interval. These results can help ophthalmologists develop personalised therapies for each patient. The introduction of DEX in the treatment of ME secondary to CRVO while receiving anti-VEGF therapy did not cause corticosteroid-related complications. The main limitation of this study was that the follow-up period was too short. To overcome such limitations, we are currently continuing the study to obtain long-term results.

Abbreviations

DEX, Dexamethasone; ME, Macular edema; CRVO, Central retinal vein occlusion; BCVA, Best-corrected visual acuity; CRT, Central retinal thickness; RVO, Retinal vein occlusion; VA, Visual acuity; VEGF, Vascular endothelial growth factor; PRN, Pro re nata; ETDRS, Early Treatment Diabetic Retinopathy Study; FFA, Fluorescein fundus angiography; NPA, Nonperfusion areas; OCT, Optical coherence tomography; IOP, Intraocular pressure; TEAE, Treatment emergent adverse event; SD, Standard deviation; TA, Triamcinolone acetonide.

Data Sharing Statement

The datasets generated during and/or analyses during the current study are available in the database of the Chinese Clinical Trial Registry and the library of Qingdao Eye Hospital, Shandong Eye Institute, Shandong First Medical University & Shandong Academy of Medical Science.

Ethics Approval and Consent to Participate

The experimental protocol was established, according to the ethical guidelines of the Helsinki Declaration and was approved by the Human Ethics Committee of Qingdao Eye Hospital. Written informed consent was obtained from individual or guardian participants.

Acknowledgments

I would like to express my gratitude to professor Xu Haifeng, for her instructive advice and useful suggestions on my thesis. I also owe a special debt of gratitude to all the colleague who helped me during the enrolment and data collection. This paper has been uploaded to Research Square as a preprint: <https://www.researchsquare.com/article/rs-1166617/v1>.

Author Contributions

All authors made a significant contribution to the work reported, whether that is in the conception, study design, execution, acquisition of data, analysis and interpretation, or in all these areas; took part in drafting, revising or critically reviewing the article; gave final approval of the version to be published; have agreed on the journal to which the article has been submitted; and agree to be accountable for all aspects of the work.

Funding

This study received funding from the Foundation for Outstanding Young Scientist in Shandong Province (BS2014SF003) and the Bethune Lumitin Research Foundation for the Young and Middle-aged Ophthalmologist (BJ-M2016008L).

Disclosure

The authors declare no conflicts of interest in this work.

References

1. Rogers S, McIntosh RL, Cheung N, et al. The prevalence of retinal vein occlusion: pooled data from population studies from the United States, Europe, Asia, and Australia. *Ophthalmology*. 2010;117(2):313–9.e1. doi:10.1016/j.ophtha.2009.07.017
2. Miller JW, Le CJ, Strauss EC, Ferrara N. Vascular endothelial growth factor A in intraocular vascular disease. *Ophthalmology*. 2013;120(1):106–114. doi:10.1016/j.ophtha.2012.07.038
3. Funk M, Kriechbaum K, Prager F, et al. Intraocular concentrations of growth factors and cytokines in retinal vein occlusion and the effect of therapy with bevacizumab. *Invest Ophthalmol Vis Sci*. 2009;50(3):1025–1032. doi:10.1167/iovs.08-2510
4. Brown DM, Campochiaro PA, Singh RP, et al. Ranibizumab for macular edema following central retinal vein occlusion: six-month primary end point results of a Phase III study. *Ophthalmology*. 2010;117(6):1102–1112.e1. doi:10.1016/j.ophtha.2010.02.021
5. Campochiaro PA, Brown DM, Awh CC, et al. Sustained benefits from ranibizumab for macular oedema following central retinal vein occlusion: twelve-month outcomes of a phase III study. *Ophthalmology*. 2011;118(10):2041–2049. doi:10.1016/j.ophtha.2011.02.038
6. Scott IU, VanVeldhuisen PC, Ip MS, et al. Baseline factors associated with 6-month visual acuity and retinal thickness outcomes in patients with macular oedema secondary to central retinal vein occlusion or hemiretinal vein occlusion: SCORE2 Study Report 4. *JAMA Ophthalmol*. 2017;135:639–649. doi:10.1001/jamaophthalmol.2017.1141
7. Klaassen I, Van Noorden CJ, Schlingemann RO. Molecular basis of the inner blood-retinal barrier and its breakdown in diabetic macular edema and other pathological conditions. *Prog Retin Eye Res*. 2013;34:19–48. doi:10.1016/j.preteyeres.2013.02.001
8. Antonetti DA, Wolpert EB, DeMaio L, Harhaj NS, Scaduto RC. Hydrocortisone decreases retinal endothelial cell water and solute flux coincident with increased content and decreased phosphorylation of occludin. *J Neurochem*. 2002;80:667–677. doi:10.1046/j.0022-3042.2001.00740.x
9. Eter N, Mohr A, Wachtlin J, et al. Dexamethasone intravitreal implant in retinal vein occlusion: real-life data from a prospective, multicenter clinical trial. *Graefes Arch Clin Exp Ophthalmol*. 2017;255(1):77–87. doi:10.1007/s00417-016-3431-x
10. Campochiaro PA, Hafiz G, Mir TA, et al. Pro-permeability factors after dexamethasone implant in retinal vein occlusion; the Ozurdex for Retinal Vein Occlusion (ORVO) study. *Am J Ophthalmol*. 2015;160(2):313–321.e19. doi:10.1016/j.ajo.2015.04.025
11. Hoerauf H, Feltgen N, Weiss C, et al. Clinical efficacy and safety of Ranibizumab versus dexamethasone for central retinal vein occlusion (COMRADE C): a European label study. *Am J Ophthalmol*. 2016;169:258–267. doi:10.1016/j.ajo.2016.04.020
12. Nghiem-Buffet S, Baillif S, Regnier S, Skelly A, Yu N, Sodi A. Treatment patterns of ranibizumab intravitreal injection and dexamethasone intravitreal implant for retinal vein occlusion in the USA. *Eye*. 2017;31(4):551–559. doi:10.1038/eye.2016.269
13. Zhang M, Zhang Z, Yan M, Hong L, Yang C, Dechao Y. Recombinant anti-vascular endothelial growth factor fusion protein efficiently suppresses choroidal neovascularization in monkeys. *Mol Vis*. 2008;14:37–49.
14. Zhang M, Dechao Y, Yang C, et al. The pharmacology study of a new recombinant human VEGF receptor-fc fusion protein on experimental choroidal neovascularization. *Pharm Res*. 2009;26(1):204–210. doi:10.1007/s11095-008-9718-9
15. Wang Q, Tao L, Zhigang W, et al. Novel VEGF decoy receptor fusion protein Conbercept targeting multiple VEGF isoforms provide remarkable anti-angiogenesis effect in vivo. *PLoS One*. 2013;8(8):e70544. doi:10.1371/journal.pone.0070544

16. Li X, Xu G, Wang Y, et al. Safety and efficacy of Conbercept in neovascular age-related macular degeneration. Results from a 12-month randomized Phase 2 study: aurora study. *Ophthalmology*. 2014;121(9):1740–1747. doi:10.1016/j.ophtha.2014.03.026
17. Sun Z, Zhou H, Lin B, et al. Efficacy and safety of intravitreal Conbercept injections in macular edema secondary to retinal vein occlusion. *Retina*. 2017;37(9):1723–1730. doi:10.1097/MD.0000000000002022
18. Rosenfeld PJ, Brown DM, Heier JS, et al.; MARINA Study Group. Ranibizumab for neovascular age-related macular degeneration. *N Engl J Med*. 2006;355(14):1419–1431. doi:10.1056/NEJMoa054481
19. Chew EY, Jonghyeon K, Sperduto RD, et al. Evaluation of the age-related eye disease study clinical lens grading system. AREDS report no. 31. *Ophthalmology*. 2010;117(11):2112–9.e3. doi:10.1016/j.ophtha.2010.02.033
20. Nauck M, Roth M, Tamm M, et al. Induction of vascular endothelial growth factor by platelet-activating factor and platelet-derived growth factor is downregulated by corticosteroids. *Am J Respir Cell Mol Biol*. 1997;16(4):398–406. doi:10.1165/ajrcmb.16.4.9115750
21. Tamura H, Miyamoto K, Kiryu J, et al. Intravitreal injection of corticosteroid attenuates leukostasis and vascular leakage in experimental diabetic retina. *Invest Ophthalmol Vis Sci*. 2005;46(4):1440–1444. doi:10.1167/iovs.04-0905
22. Ip MS, Kumar KS. Intravitreal triamcinolone acetonide as treatment for macular edema from central retinal vein occlusion. *Arch Ophthalmol*. 2002;120(9):1217–1219.
23. Haller JA, Bandello F, R B Jr, et al. Randomized, sham-controlled trial of dexamethasone intravitreal implant in patients with macular edema due to retinal vein occlusion. *Ophthalmology*. 2010;117(6):1134–1146.e3. doi:10.1016/j.ophtha.2010.03.032
24. Bezatis A, Spital G, Höhn F, et al. Functional and anatomical results after a single intravitreal Ozurdex injection in retinal vein occlusion: a 6-month follow-up—The SOLO study. *Acta Ophthalmol*. 2013;91(5):e340–7. doi:10.1111/aos.12020
25. Central Vein Occlusion Study Group. Natural history and clinical management of central retinal vein occlusion. The central vein occlusion study group. *Arch Ophthalmol*. 1997;115(10):1275. doi:10.1001/archophth.1997.01100150488006
26. Sweta VD, Shibi Dev BN, Sandhya R. Secondary glaucoma after intravitreal dexamethasone implant (Ozurdex) injection in patients with retinal disorder: a retrospective study. *Indian J Ophthalmol*. 2022;70(2):585–589. doi:10.4103/ijo.IJO_684_21

Clinical Ophthalmology

Dovepress

Publish your work in this journal

Clinical Ophthalmology is an international, peer-reviewed journal covering all subspecialties within ophthalmology. Key topics include: Optometry; Visual science; Pharmacology and drug therapy in eye diseases; Basic Sciences; Primary and Secondary eye care; Patient Safety and Quality of Care Improvements. This journal is indexed on PubMed Central and CAS, and is the official journal of The Society of Clinical Ophthalmology (SCO). The manuscript management system is completely online and includes a very quick and fair peer-review system, which is all easy to use. Visit <http://www.dovepress.com/testimonials.php> to read real quotes from published authors.

Submit your manuscript here: <https://www.dovepress.com/clinical-ophthalmology-journal>