

Evaluating a Sustained-Release Dexamethasone Insert as Adjunctive Therapy for Inflammation and Pain Post-Corneal Transplantation

Hasan Alsetri^{1,2}, Nicole Fram^{2,3}, Orly Shiler²

¹Weill Cornell Medicine-Qatar, Education City, Qatar Foundation, Doha, Qatar; ²Advanced Vision Care, Los Angeles, CA, USA; ³Stein Eye Institute, David Geffen School of Medicine, UCLA, Los Angeles, CA, USA

Correspondence: Hasan Alsetri, Advanced Vision Care, 2080 Century Park East Suite #911, Los Angeles, CA, 90067, USA, Tel +1 310 229 1220, Fax +1 310 229 1222, Email hassanalsetri@gmail.com

Purpose: To assess the efficiency and safety of an intracanalicular dexamethasone insert (Dextenza, Ocular Therapeutix, Inc) supplemented with a reduced-frequency topical drop regimen in mitigating pain and inflammation post-penetrating keratoplasty (PKP), Descemet stripping endothelial keratoplasty (DSEK), and Descemet membrane endothelial keratoplasty (DMEK), compared to standard topical corticosteroid therapy.

Patients and Methods: Eyes were categorized within the DSEK, DMEK, or PKP groups based on ocular characteristics and surgical indications. Randomized in a 1:1 ratio, the intervention group received Dextenza alongside a lowered drop frequency, while the control group followed a conventional drop protocol with no Dextenza. Primary outcomes included average pain scores and absence of anterior chamber cell and flare. Secondary outcomes included delayed re-epithelialization, corneal rejection episodes, instances of intraocular pressure (IOP) elevation >10mmHg above baseline, cystoid macular edema (CME) occurrence, and the necessity for steroid rescue.

Results: The study included 30 eyes (10 PKP, 10 DSEK, 10 DMEK). Mean pain scores (0–100 scale; (0–39 = mild pain, 40–69 = moderate pain, 70–100 = severe pain) in the Dextenza group were 3.6 (PKP), 12 (DSEK), 8 (DMEK), compared to 1.2 (PKP), 0 (DSEK), and 4 (DMEK) in controls. PKP control (n=5): 1 delayed re-epithelialization, 1 IOP elevation, 2 CME. DSEK control (n=5): 1 corneal rejection, 1 IOP elevation, 1 CME. DMEK control (n=5): 1 IOP elevation, 1 CME. DMEK Dextenza (n=5): 1 delayed re-epithelialization, 1 CME. No cases required steroid rescue, and no cell or flare was observed one-week post-surgery. There were no statistically significant differences in pain, delayed re-epithelialization, IOP elevation, corneal rejection, or CME between the Dextenza and control groups regardless of the type of corneal transplantation performed.

Conclusion: Dextenza, when combined with a lower-frequency drop regimen, demonstrates a safety profile comparable to that of a traditional higher-frequency drop protocol in terms of pain management and the adverse events explored in this study, potentially enhancing postoperative drop adherence.

Keywords: corneal transplantation, PKP, DSEK, DMEK, Dextenza

Introduction

Corneal transplantation is one of the most common and successful allogeneic transplant procedures performed worldwide.¹ Indications for corneal transplantation include corneal scarring, dystrophy, and edema. The type of corneal transplant performed depends on the location and extent of the pathology. Penetrating Keratoplasty (PKP) involves removal of the full-thickness diseased cornea and replacement with a full-thickness donor tissue. Lamellar keratoplasty is performed when the pathology is limited to specific layers of the cornea.

The three most common lamellar keratoplasty procedures include Deep Anterior Lamellar Keratoplasty (DALK), Descemet's Stripping Endothelial Keratoplasty (DSEK), and Descemet's Membrane Endothelial Keratoplasty (DMEK). DALK involves the removal of diseased stroma, while healthy endothelium is maintained. DSEK and DMEK are performed when the disease is limited to the patient's corneal endothelium.

Approximately 49,110 corneas were transplanted in the US in 2021 with the following breakdown: 33% PKP, 32% DSEK, and 29% DMEK.² Immune-mediated corneal graft failure is a major concern following corneal transplantation, necessitating immune suppression through topical steroid administration, often indefinitely. One study comparing the rejection rates of PKP, DSEK and DMEK found the rejection rate was highest after PKP (17%), followed by DSEK (9%), and lowest following DMEK (0.7%).³ Another study reported a 6% rejection rate in patients who discontinued topical steroid use 1 year after DMEK, compared with a 0% rejection rate in patients who continued topical steroid use once a day.⁴

The immediate postoperative period requires a complex dosing regimen and repeated daily administration. In fact, a routine topical steroid regimen following corneal transplantation can begin with topical steroid administration every 2 hours initially, which is then slowly tapered overtime.⁵ This dosing regimen can be especially laborious for elderly patients who struggle with topical drop instillation. An epidemiological study in Brazil found that those above 60 years of age represented the most significant age group requiring corneal transplantation.⁶ In addition, 96% of the inexperienced patients have been estimated to display improper topical drop administration techniques following cataract surgery,⁷ and such errors are presumably compounded following corneal transplant surgery due to the relatively increased frequency of the topical drop regimen during the immediate postoperative period. Additionally, topical steroid use has been found to potentially delay corneal epithelial healing, particularly in the setting of a neurotrophic cornea.⁸

The sustained-release intracanalicular 0.4mg dexamethasone insert (Dextenza, Ocular Therapeutix, Inc) is placed in the punctum of the eyelid, and is designed to deliver preservative free dexamethasone to the ocular surface for up to thirty days.⁹ Three Phase III clinical trials have demonstrated the safety and efficacy of Dextenza in the treatment of ocular pain and inflammation post-cataract surgery.^{10,11} Another study reported a reduction in postoperative inflammation and pain in their Dextenza group that was comparable to controls using only topical steroid drop regimens, albeit the findings were derived from a relatively small sample size of 60 eyes.¹² Additionally, a study evaluating the effectiveness and safety of Dextenza following photorefractive keratectomy (PRK), found no significant differences in pain, healing time and visual outcomes between eyes with Dextenza and eyes using a topical steroid drop regimen. In their study, preference for Dextenza over the topical steroid regimen was reported in 70% of the patients.¹³

Despite the extensive research available investigating Dextenza, there appears to be a paucity of the literature exploring its utility following corneal transplantation. In a recent publication, we reported our outcomes following Dextenza insertion in 6 patients who underwent corneal transplant procedures. The Dextenza insert was found to be safe if intraocular pressure (IOP) was appropriately monitored, and patients were screened for past histories of punctal plug insertions prior to selection as Dextenza candidates.¹⁴ Due to the small sample size of that study and its retrospective nature, we felt the potential of Dextenza as a means to safely mitigate the burdens of high-dose topical steroid regimens could be further elucidated in the setting of corneal transplantation.

Materials and Methods

This randomized, controlled, prospective study encompassed 30 eyes of 30 patients who underwent PKP, DSEK and DMEK procedures in a private practice setting by N.F and S.N between October 2020 and January 2022. Institutional review board approval was obtained by the WCG Institutional Review Board and written informed consent from all patients was obtained before beginning any study-related procedures. This study complied with the declaration of Helsinki.

Patient Grouping

The patients were divided into 3 groups based on the corneal transplantation method they underwent, which was determined based on each patient's ocular characteristics as well as their indication for surgery. Once the surgical method was established, patients in each group were randomly assigned to the treatment arm or the control arm using a 1:1 randomization ratio. Patients in the treatment arm received Dextenza immediately prior to their corneal transplantation surgery. Patients in the control group received nothing (no Dextenza) prior to their corneal transplantation surgery (Figure 1). All patients were followed up for 90 days following the corneal transplant procedure.

Study Metrics

Patient eligibility was determined at the screening visit where demographic data and medical history were recorded, a dilated ophthalmic examination was performed, and baseline measurements were obtained. IOP was measured using a Goldmann

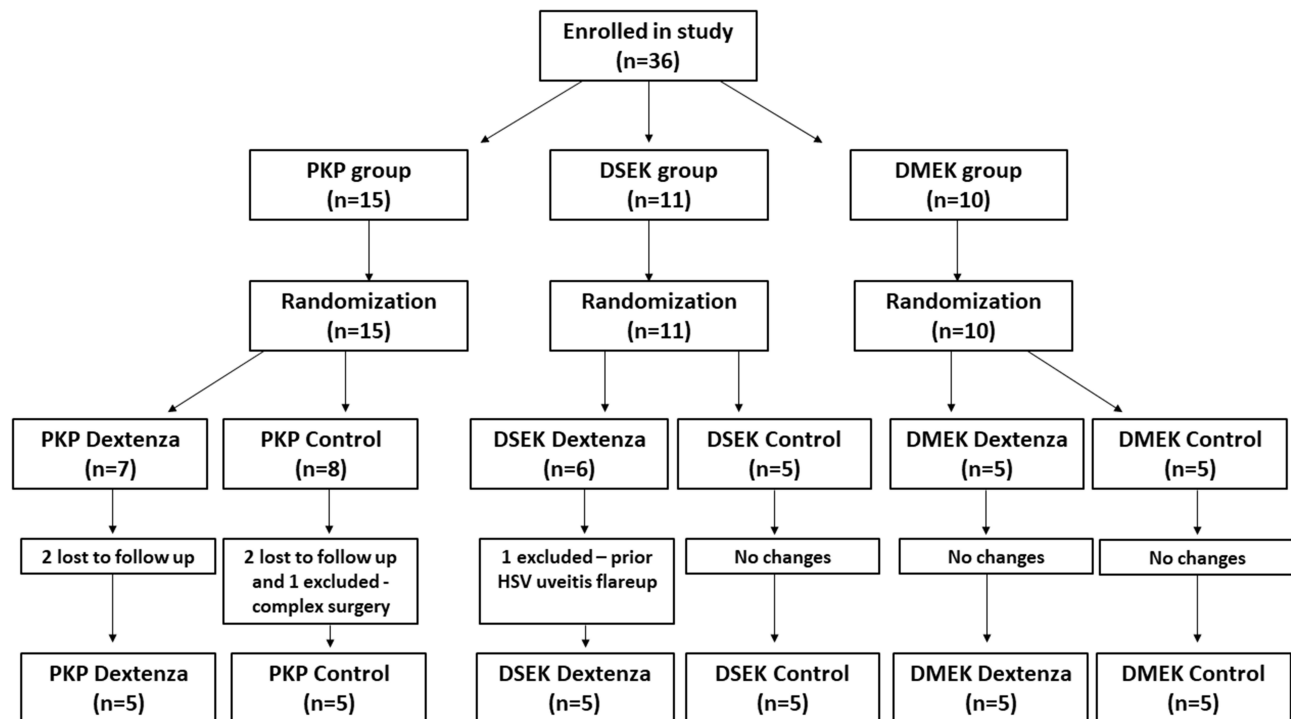


Figure 1 Randomization flow chart depicting the allocation of participants within our study. Participants were first enrolled and then placed into the PKP, DSEK, or DMEK groups based on their ocular characteristics and surgical indications. Within each of these groups, participants were randomized to either the Dextenza or control arm. The numbers indicate the participants at each stage, including those lost to follow up or excluded for specific reasons mentioned.

applanation tonometer. The presence of anterior chamber (AC) cell and flare, used as a marker for AC inflammation, was assessed at a slit lamp, and graded from 0 to 4+ using the standardization of uveitis nomenclature (SUN) working group grading scheme.¹⁵ Best corrected distance visual acuity (BCDVA) was measured at a distance of 4 meters using an early treatment diabetic retinopathy study (ETDRS) chart. Ocular pain was assessed by visual analogue scale (VAS) using a numerical rating scale from 0–100, where 0–39 = mild pain, 40–69 = moderate pain, and 70–100 = severe pain. These measurements were obtained, and adverse events were recorded at all follow up visits which were scheduled for 1 day, 7 days, 30 days, 60 days, and 90 days following the corneal transplant procedure.

Treatment Regimens

To test the efficiency of Dextenza, patients receiving the insert were placed on a reduced topical drop regimen relative to the clinic's standard of care. Patients who received Dextenza in the 3 groups were placed on a topical steroid regimen as follows: prednisolone acetate 1% 4 times a day for 1 month, 3 times a day for 1 month, 2 times a day for 1 month, 1 time a day for 1 month and then loteprednol etabonate 0.5% 1 time a day thereafter. Patients who did not receive Dextenza in the 3 groups were placed on a topical regimen as follows: prednisolone acetate 1% every 2 hours for 2 weeks, 4 times a day for 1 month, 3 times a day for 1 month, 2 times a day for 1 month, 1 time a day for 1 month and then loteprednol etabonate 0.5% 1 time a day thereafter (Figure 2). All patients received topical moxifloxacin 0.5% for 2 weeks following surgery. The steroid regimen was adjusted at the surgeon's discretion if it was deemed necessary. Steroid rescue was defined as: new CME, intraocular inflammation, graft failure/rejection, or evidence of worsening corneal edema >1+ requiring an increase in steroid frequency or potency.

Outcome Measures

The primary outcome measures for this study included mean pain score, absence of AC cell, and absence of AC flare between 7 days and 90 days following the procedure. Secondary outcome measures included delayed re-epithelization > 1 month post-surgery, delayed clearing of corneal edema > 2 months post-surgery, corneal rejection episodes, incidence

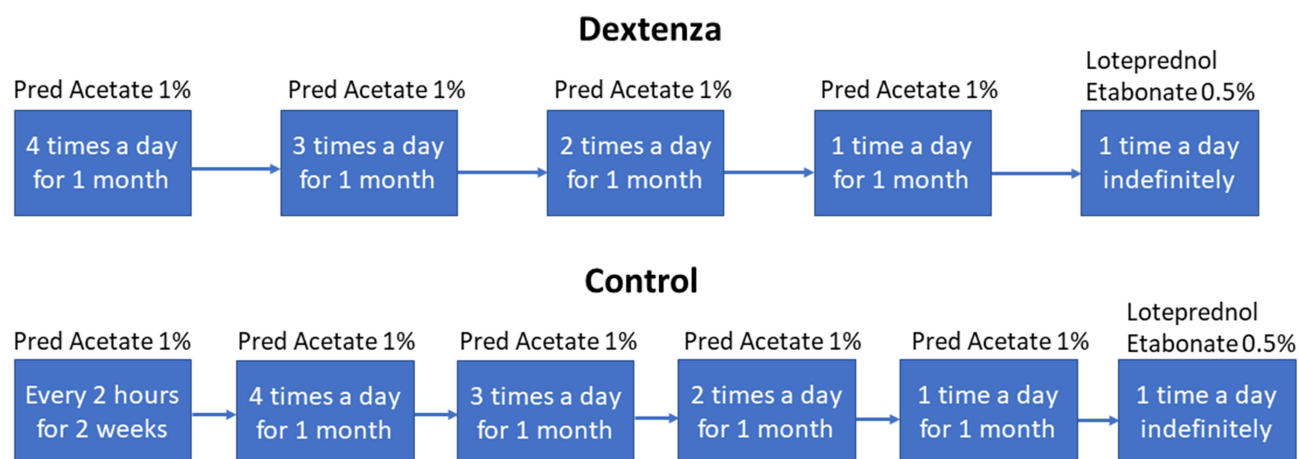


Figure 2 Steroid tapering protocols for Dextenza-treated and control groups post-corneal transplantation.

of IOP elevation > 10mmHg above baseline or > 22mmHg, incidence of cystoid macular edema (CME) postoperatively, improvement in BCDVA, and proportion of patients who needed steroid rescue.

Statistical Analysis

The Fisher's exact test and the paired Student's *T*-test were performed to determine whether differences between the Dextenza and control arms of the PKP, DSEK, and DMEK groups were significant, using GraphPad Prism version 8.0.0 for Windows, GraphPad Software, San Diego, California, USA, www.graphpad.com. A *P* value less than 0.05 was considered statistically significant.

Sample Size

The sample size in this study was determined by the number of eligible participants available during the study period. We did not perform power calculations to predetermine the sample size due to these constraints.

Results

Of the 30 patients in the study, 10 underwent PKP, 10 underwent DSEK and 10 underwent DMEK. Half of the patients in each group received Dextenza and the other half did not and served as controls (Figure 3). Table 1 shows the study demographics. Mean age at the time of the surgery was 71 ± 12.6 years. Fifty-three percent of the patients were male.

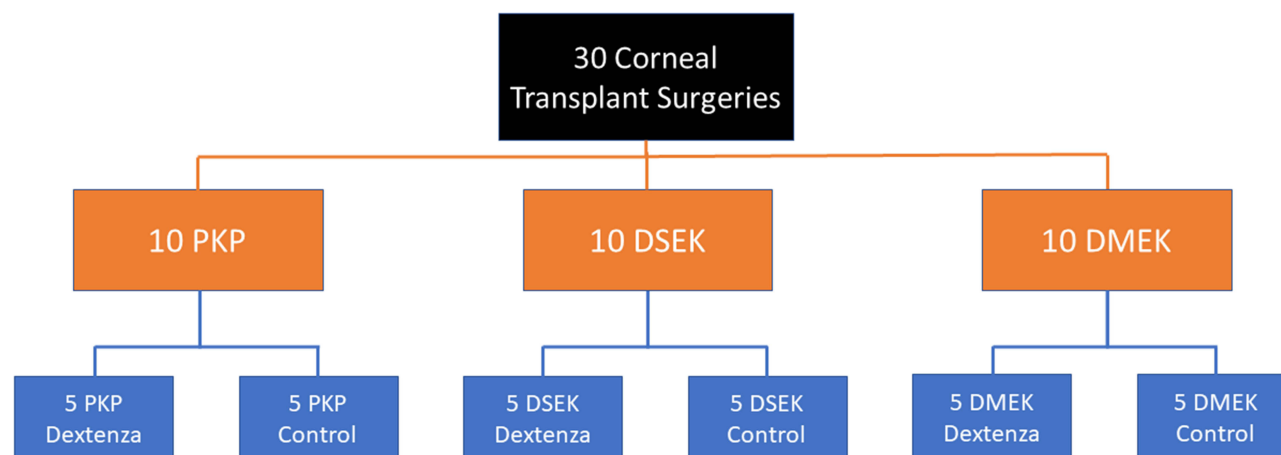


Figure 3 Study groupings showing the distribution of 30 corneal transplant surgeries into PKP, DSEK, and DMEK, each further subdivided into Dextenza-treated and control groups.

Table 1 Patient Demographics

Number of Patients	30
Number of Eyes	30
Male, n (%)	16 (53%)
Age, mean \pm SD	71 \pm 12.6

Abbreviation: SD, standard deviation.

Post-Operative Safety Measures (Tables 2 and 3)

Pain Score

The mean pain score as assessed using the 0–100 VAS (0–39 = mild pain, 40–69 = moderate pain, 70–100 = severe pain) at 1 month postoperative in the PKP group was 3.6 for the Dextenza arm, and 1.2 for the control arm. In the DSEK group the Dextenza arm's mean pain score was 12, while the control arm's score was 0. In the DMEK group the Dextenza arm's mean pain score was 8, while the control arm's score was 4 (Table 2). None of the patients in the study had AC cell or flare 1 week after surgery. We found no statistical significance in pain scores between the Dextenza and control groups.

Table 2 Ocular Pain Scores Using Visual Analogue Scale at 1 Month Postoperative

		Mean Pain Score
PKP	Dextenza	3.6
	Control	1.2
DSEK	Dextenza	12
	Control	0
DMEK	Dextenza	8
	Control	4

Notes: 0–39 = mild pain, 40–69 = moderate pain, 70–100 = severe pain.

Abbreviations: PKP, penetrating keratoplasty; DSEK, Descemet stripping endothelial keratoplasty; DMEK, Descemet membrane endothelial keratoplasty (DMEK).

Table 3 Postoperative Safety Outcome Measures Across the 3-Month Study Period

		Delayed Re-Epithelialization	Corneal Rejection Episodes	IOP Elevation	Incidence of CME
PKP	Dextenza	0	0	0	0
	Control	1	0	1	2*
DSEK	Dextenza	0	0	0	0
	Control	0	1	1	1*
DMEK	Dextenza	1	0	0	1*
	Control	0	0	1	1

Notes: *h/o of CME prior to corneal transplant, 1/2 of the patients with CME in the control arm of the PKP group had a h/o of CME prior to their PKP.

Abbreviations: CME, cystoid macular edema; IOP, intraocular pressure; PKP, penetrating keratoplasty; DSEK, Descemet stripping endothelial keratoplasty; DMEK, Descemet membrane endothelial keratoplasty (DMEK).

Delayed Re-Epithelialization > 1 Month

One patient in the control arm of the PKP group and 1 patient in the Dextenza arm of the DMEK group experienced delayed re-epithelialization > 1 month (Table 3).

Corneal Rejection Episode Within 3 Months

One patient in the control arm of the DSEK group experienced a corneal rejection episode (Table 3).

IOP Elevation >10 mmHg Baseline

One patient in the control arm of the PKP group, 1 patient in the control arm of the DSEK group, and 1 patient in the control arm of the DMEK group experienced IOP elevation (Table 3).

CME

Two patients in the control arm of the PKP group experienced postoperative CME, one of those patients had a prior history of CME. One patient in the control arm of the DSEK group experienced postoperative CME and had a history of prior CME. One patient in the Dextenza arm of the DMEK group experienced postoperative CME and had a history of prior CME. One patient in the control arm of the DMEK group experienced postoperative CME with no prior history (Table 3).

Rescue with Steroid Drops

None of the patients required any steroid rescue (an increase in the frequency or potency of the administered steroid due to new CME, intraocular inflammation, graft failure/rejection, or evidence of worsening corneal edema >1+).

Delayed Corneal Edema

None of the patients experienced a delay in clearing of corneal edema.

Improvement in BCDVA

All patients experienced an improvement in BCDVA 3 months postoperatively as measured by the ETDRS chart at a distance of 4 meters (Table 4).

Discussion

Steroid use to prevent immune mediated corneal graft rejection is imperative following corneal transplant procedures. Particularly, the immediate postoperative period requires intensive steroid administration, with routine topical steroid regimens starting with administration every 2 hours.⁵ This high frequency of topical steroid use can lead to a decrease in patient compliance and an increase in errors administering the drops, ultimately resulting in a reduction in the

Table 4 Postoperative Month Three Best Corrected Distance Visual Acuity

		Preop mean ETDRS score	Postop mean ETDRS score	P-value
PKP	Dextenza	12	28.6	0.005
	Control	0	24	0.009
DSEK	Dextenza	15.2	28.4	0.03
	Control	17.4	32.2	0.03
DMEK	Dextenza	19.2	40.8	0.005
	Control	28.8	36	0.05

Notes: Best corrected distance visual acuity assessed using the Early Treatment Diabetic Retinopathy Study (ETDRS) chart, P-value obtained using the paired Student's T-test.

effectiveness of the steroid regimen. Additionally, topical steroid drops have been found to potentially delay corneal epithelial healing, particularly in the setting of a neurotrophic cornea.⁸

Dextenza is a sustained-release intracanalicular 0.4mg dexamethasone ophthalmic insert and is designed to deliver preservative free dexamethasone to the ocular surface for up to thirty days.⁹ Three Phase III trials showed that Dextenza was a safe and effective treatment for managing ocular pain and inflammation following cataract surgery.^{10,11} A study (PREPARE, n=60 eyes) evaluating Dextenza as a steroid delivery system following cataract surgery found a reduction in pain and inflammation comparable to topical steroid regimen controls.¹² Another study (RESTORE, n=20 subjects) evaluating Dextenza after PRK found that safety and visual outcomes were comparable with the topical steroid drop controls, with 70% preference for Dextenza reported among patients in the study.¹³ Our recent publication exploring Dextenza as an adjunct to therapy, following corneal transplantation in 6 patients found Dextenza to be safe and comparable to the standard of care, as long as IOPs were monitored, and patients were screened for a past ocular history of punctal plug insertions.¹⁴ Due to the small sample size and retrospective nature of that study, as well as a scarcity of the literature exploring applications of Dextenza for corneal transplantation, we evaluated the safety and compatibility of Dextenza as an adjunct to therapy, following PKP, DSEK and DMEK in a randomized, controlled, prospective study.

In our study, we found no statistically significant differences in mean ocular pain score, as assessed using the VAS, between the control and Dextenza arms of the PKP, DSEK, and DMEK groups (Table 2). Similarly, there were no statistically significant differences in delayed re-epithelialization, corneal rejection episodes, IOP elevation, and incidence of CME (Table 3). No AC cell or flare was reported in any patient in the past postoperative week 1. The similar outcomes observed between the Dextenza and control groups across these various measures support the non-inferiority of Dextenza compared to conventional drop therapy. However, the absence of statistically significant differences may be influenced by the small sample size, which could limit our ability to detect small differences that are clinically important.

None of the patients in the study required steroid rescue (an increase in the frequency or potency of the administered steroid due to new CME, intraocular inflammation, graft failure/rejection, or evidence of worsening corneal edema >1+). There were deviations from the drop protocols that were not considered steroid rescues for 7 patients as follows. Three patients with recalcitrant CME present before the transplants, were placed on higher frequency drop protocols for management: one from the PKP control group, one from the DSEK control group, and one from the DMEK control group. One patient developed corneal neovascularization in the PKP Dextenza group, necessitating a higher frequency drop protocol. One patient in the DSEK control group was placed on a higher frequency drop protocol due to trace edema which resolved. One patient in the DSEK control group experienced a prolonged corneal abrasion, requiring an increase in steroid frequency until resolution. One patient in the control arm of the DSEK group experienced a corneal rejection episode 2 months postoperatively due to documented non-compliance with their topical steroid regimen. Their steroid frequency was increased until the corneal graft stabilized one month later.

As mentioned, 3/5 patients with postoperative CME had a history of recalcitrant CME present before the corneal transplant. Postoperative month 3 BCDVA at 4 meters, assessed using the ETDRS chart, showed statistically significant increases compared to the preoperative BCDVA in both the control and Dextenza arms of the PKP, DSEK and DMEK groups (Table 4).

Throughout our study, the regimen utilizing Dextenza, and a lower drop protocol showed no statistically significant difference when compared to the clinic's standard of care, higher topical steroid drop regimen for inflammation management and graft rejection prevention. Additionally, the Dextenza groups showed a similar safety and visual outcome profile compared to the control groups. Limitations of the study include a small sample size, which was constrained by the availability of participants, potentially limiting the power to detect small effect sizes, and that the cases were limited to a single practice with two surgeons. Investigations with larger sample sizes, longer follow up periods, or different topical steroid drop protocols are encouraged to be performed in order to further understand the findings. Future considerations could evaluate implanting an additional Dextenza insert after the initial insert has bioresorbed to explore its utility in reducing the topical drop burden beyond the first postoperative month.

Conclusion

Based on the study findings, which revealed no statistically significant differences between the Dextenza and control groups across key outcomes including pain, anterior chamber inflammation, intraocular pressure, incidence of CME, and

other postoperative complications, Dextenza demonstrates the potential to mitigate the burdens associated with intensive, high-frequency topical steroid drop regimens that patients undergoing corneal transplant procedures endure in the immediate postoperative period. The results indicate that Dextenza maintains effectiveness and safety, potentially enhancing patient compliance with their treatment plans.

Data Sharing Statement

We intend to share individual deidentified participant data. Specifically, we will share the raw data collected during the trial, including demographic information, clinical measurements, and outcome data. Additionally, we will make available the study protocol. The data will be accessible upon reasonable request by emailing the corresponding author. The data will be available immediately after publication and for a period of 5 years.

Funding

This study was funded by Ocular Therapeutix, Inc, which has a commercial interest in the Dextenza insert evaluated in this research. The authors declare that, while Ocular Therapeutix, Inc provided financial support for this work, all authors maintained full independence in the study design, data collection, analysis, and interpretation of results.

Disclosure

The authors report no conflicts of interest in this work.

References

1. Singh R, Gupta N, Vanathi M, Tandon R. Corneal transplantation in the modern era. *Indian J Med Res*. 2019;150(1):7–22. PMID: 31571625; PMCID: PMC6798607. doi:10.4103/ijmr.IJMR_141_19
2. Eye Bank Association of America. 2022 eye banking statistical report; 2022. Available from: <https://restoresight.org/members/publications/statistical-report/#~:text=49%2C110%20intermediate%2Dterm%20preserved%20corneas,were%20exported%20internationally%20in%202021.> Accessed February 12, 2023.
3. Anshu A, Price MO, Price FW. Risk of corneal transplant rejection significantly reduced with Descemet's membrane endothelial keratoplasty. *Ophthalmology*. 2012;119(3):536–540. PMID: 22218143. doi:10.1016/j.ophtha.2011.09.019
4. Price MO, Scanameo A, Feng MT, Price FW. Descemet's membrane endothelial keratoplasty: risk of immunologic rejection episodes after discontinuing topical corticosteroids. *Ophthalmology*. 2016;123(6):1232–1236. PMID: 26983976. doi:10.1016/j.ophtha.2016.02.001
5. Azevedo Magalhaes O, Shalaby Bardan A, Zarei-Ghanavati M, Liu C. Literature review and suggested protocol for prevention and treatment of corneal graft rejection. *Eye*. 2020;34(3):442–450. PMID: 31332293; PMCID: PMC7042259. doi:10.1038/s41433-019-0517-9
6. Cruz GKP, Azevedo IC, Carvalho DP, Vitor AF, Santos VEP, Ferreira MA. Clinical and epidemiological aspects of cornea transplant patients of a reference hospital. *Rev Lat Am Enfermagem*. 2017;25:e2897. PMID: 28614429; PMCID: PMC5492649. doi:10.1590/1518-8345.1537.2897
7. An JA, Kasner O, Samek DA, Lévesque V. Evaluation of eyedrop administration by inexperienced patients after cataract surgery. *J Cataract Refract Surg*. 2014;40(11):1857–1861. PMID: 25248295. doi:10.1016/j.jcrs.2014.02.037
8. Renfro L, Snow JS. Ocular effects of topical and systemic steroids. *Dermatol Clin*. 1992;10(3):505–512. PMID: 1617809. doi:10.1016/S0733-8635(18)30318-8
9. Ocular therapeutix; 2021. Available from: <https://www.ocutx.com/products/dextenza/>. Accessed February 8, 2023.
10. Tyson SL, Bafna S, Gira JP, et al. Dextenza Study Group. Multicenter randomized Phase 3 study of a sustained-release intracanalicular dexamethasone insert for treatment of ocular inflammation and pain after cataract surgery. *J Cataract Refract Surg*. 2019;45(2):204–212. doi:10.1016/j.jcrs.2018.09.023
11. Walters T, Bafna S, Vold S, et al. Efficacy and safety of a sustained release dexamethasone insert for the treatment of ocular pain and inflammation after cataract surgery: results from two phase 3 studies. *J Clin Exp Ophthalmol*. 2016;7:4. doi:10.4172/2155-9570.1000572
12. Ibach MJ, Zimprich L, Wallin DD, Olevson C, Puls-Boever K, Thompson V. In clinic optometrist insertion of dextenza (Dexamethasone Ophthalmic Insert 0.4mg) Prior to Cataract Surgery: the PREPARE Study. *Clin Ophthalmol*. 2022;16:2609–2615. doi:10.2147/OPHTH.S374405
13. Ibach MJ, Shafer BM, Wallin DD, Puls-Boever KR, Thompson VM, Berdahl JP. The effectiveness and safety of dextenza 0.4 mg for the treatment of postoperative inflammation and pain in patients after photorefractive keratectomy: the RESTORE trial. *J Refract Surg*. 2021;37(9):590–594. PMID: 34506241. doi:10.3928/1081597X-20210610-05
14. Fram N, Alsetri H, Shiler O, Paterno PJ, Cabang J. Retrospective study of a sustained-release intracanalicular dexamethasone insert for treatment of ocular inflammation after cataract and corneal surgery. *Clin Ophthalmol*. 2022;16:4065–4074. PMID: 36532822; PMCID: PMC9749497. doi:10.2147/OPHTH.S386702
15. Jabs DA, Nussenblatt RB, Rosenbaum JT; Standardization of Uveitis Nomenclature (SUN) Working Group. Standardization of uveitis nomenclature for reporting clinical data. results of the first international workshop. *Am J Ophthalmol*. 2005;140(3):509–516. PMID: 16196117; PMCID: PMC8935739. doi:10.1016/j.ajo.2005.03.057

Clinical Ophthalmology

Dovepress

Publish your work in this journal

Clinical Ophthalmology is an international, peer-reviewed journal covering all subspecialties within ophthalmology. Key topics include: Optometry; Visual science; Pharmacology and drug therapy in eye diseases; Basic Sciences; Primary and Secondary eye care; Patient Safety and Quality of Care Improvements. This journal is indexed on PubMed Central and CAS, and is the official journal of The Society of Clinical Ophthalmology (SCO). The manuscript management system is completely online and includes a very quick and fair peer-review system, which is all easy to use. Visit <http://www.dovepress.com/testimonials.php> to read real quotes from published authors.

Submit your manuscript here: <https://www.dovepress.com/clinical-ophthalmology-journal>