

Scheimpflug Tomography as a Predictor of Corneal Edema After Phacoemulsification in Fuchs Endothelial Corneal Dystrophy

Taher K Eleiwa^{1,2}, Mona Abd El-Azim Mohammed³, Ahmed Sherin M Bayoumy¹

¹Department of Ophthalmology, Benha University, Benha, Egypt; ²Department of Ophthalmology, Magrabi Eye and Dental Hospital, Qassim, Kingdom of Saudi Arabia; ³Department of Ophthalmology, Mansoura Ophthalmic hospital, Mansoura, Egypt

Correspondence: Taher K Eleiwa, Email taher.eleiwa@fmed.bu.edu.eg

Purpose: To determine if Scheimpflug tomography pachymetry map and posterior elevation map patterns can predict the occurrence of corneal edema following uneventful phacoemulsification surgery in Fuchs endothelial corneal dystrophy (FECD).

Design: Observational prospective case-control study.

Participants: Fifty FECD eyes (50 patients) with visually significant cataract: 25 with subclinical corneal edema (SCE) versus 25 without SCE.

Methods: Preoperatively, FECD was clinically assessed, and only patients devoid of clinical corneal edema were enrolled. Utilizing the Mayo Clinic classification for subclinical corneal edema (SCE), eligible FECD eyes were stratified based on Scheimpflug imaging pachymetry map and posterior elevation map characteristics, including loss of regular isopachs, displacement of the cornea's thinnest point, and the presence of posterior surface depression, into two groups: Group A representing FECD with SCE, and Group B: FECD without SCE. One week postoperatively, clinical and tomographic evaluation was performed. Regression analysis was conducted to evaluate predictors of corneal edema after uneventful phacoemulsification surgery in both groups.

Results: All patients were successfully imaged before and 1 week after surgery. Visual acuity was significantly improved in both groups ($P < 0.001$). No postoperative clinical edema was observed in Group B, while 23 (92%) had mild edema and 2 (8%) had moderate edema in Group A. Both groups showed a significant increase in postoperative central corneal thickness (CCT) and thinnest corneal thickness (TCT) (both $P < 0.001$). Compared to Group B, Group A showed a significant central flattening of the anterior corneal surface ($P = 0.007$ and $P = 0.04$ for K1 and K2 respectively), and a significant increase in the postoperative posterior surface depression. Multivariate analysis showed that 94% of postoperative corneal edema could be predicted by the presence of preoperative posterior surface depression ($P = 0.04$, ARR = 5.8 (1.89–35.7)).

Conclusion: Scheimpflug tomography pachymetry map and posterior elevation map patterns can predict corneal edema after uneventful phacoemulsification surgery in FECD with subclinical corneal edema.

Keywords: phacoemulsification, cataract surgery, corneal edema, Scheimpflug tomography, pentacam, Fuchs endothelial corneal dystrophy

Introduction

Cataract surgery stands as the prevailing ocular procedure worldwide among adults aged 50 and above.¹ Among the various complications that may occur following cataract surgery, corneal edema is frequently encountered. Post-phacoemulsification corneal edema can result from endothelial pump failure, which may be triggered by mechanical or chemical injury, subsequent infection or inflammation, or concurrent or pre-existing endothelial compromise.²

Fuchs endothelial corneal dystrophy (FECD) is described as a progressive bilateral asymmetric condition affecting the corneal endothelium. It is characterized by the loss of endothelial cells, disruption of the endothelial barrier, thickening of the Descemet's membrane (DM), and the development of excrescences called guttae. These manifestations

can lead to corneal edema and a decline in visual acuity.³ Currently, an estimated 300 million individuals aged 30 years and above are believed to have FECD worldwide, with projections indicating a rise to 415 million by 2050.⁴

Gradual corneal thickening progresses over time, often accompanied by a phase of subclinical edema, which refers to edema not readily apparent during slit-lamp biomicroscopy but may manifest symptoms such as glare and subjective visual haziness.⁵ While diagnosing FECD is typically straightforward through the detection of guttae via slit-lamp examination, identifying subclinical corneal edema poses more challenges. Awareness of this condition is crucial in general ophthalmology as patients may experience symptoms related to subclinical edema and require counseling regarding the potential progression of FECD, particularly in the context of cataract surgery.⁶

Prognostic indicators for FECD are currently lacking in clinical practice, often relying on subjective judgment. Decision-making for cataract surgery alone or combined with keratoplasty in FECD is challenging, with suggested methods like assessing central corneal thickness (CCT) and endothelial cell density being deemed misleading.^{5,7–9} Corneal backscatter cutoffs measured by confocal microscopy have been proposed but present challenges in clinical implementation.⁸

Patel et al introduced a Scheimpflug imaging classification for FECD, categorizing it into clinically obvious edema, subclinical corneal edema, or no edema independently of central corneal thickness (CCT). Their study identified specific tomographic patterns, including irregular isopachs, displacement of the cornea's thinnest point, and focal posterior surface depression, associated with subclinical corneal edema in FECD. The classification recommends diagnosing FECD clinically with slit-lamp biomicroscopy, further refining it with Scheimpflug tomography when edema is not clinically evident.⁵

In this study, we utilized the Scheimpflug tomography to explore the potential of the aforementioned tomographic patterns in predicting corneal edema after uneventful phacoemulsification surgery in cataractous eyes with early FECD.

Methods

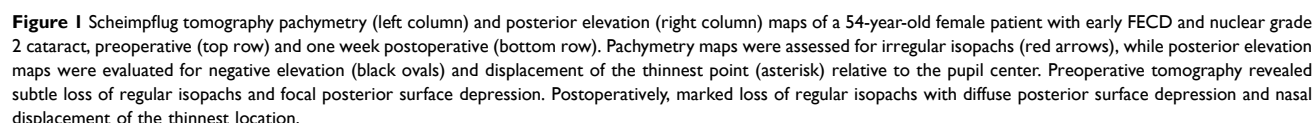
This was an observational prospective case–control study that was conducted on patients with early FECD who had visually significant cataract and underwent uneventful phacoemulsification surgery between November 2022 and November 2023. The study was approved by the Benha Faculty of Medicine Research Ethics Committee (MS 19-9-2021) and complied with the principles of declaration of Helsinki. Informed consent was taken from all patients prior to the study.

Study Participants

All patients were subjected to full ophthalmic evaluation. Visual acuity was recorded using logMAR unit. Each eye underwent slit-lamp examination conducted by a cornea specialist (T.K.E), and FECD eyes were graded clinically based on the following criteria: grade 1 represented non-confluent guttae; grade 2 indicated the presence of any area with confluent guttae but without evident clinical edema; grade 3 denoted confluent guttae accompanied by clinical edema; grade 4 signified edema coupled with whitening or haze.¹⁰ We only included grades 1 and 2 as early-stage FECD, while grades 3 and 4 were indicated for combined phacoemulsification and endothelial keratoplasty (EK), thus excluded from our study. Further, contact lens users, those with prior corneal surgeries (including keratorefractive procedures), corneal trauma, prior or current non-FECD corneal pathology, inflammatory ocular diseases, ocular surface diseases, glaucoma, systemic diseases with ocular involvement, or those using topical (except artificial tears) or systemic medications that could impact the cornea were excluded from our study.

Imaging

Before and one week after surgery, Scheimpflug tomography (Pentacam, software version 1.20r 112; Oculus, Wetzlar, Germany) was utilized to image patients, following procedures outlined elsewhere.¹¹ Image acquisition occurred at any time within regular clinic hours (9:30 am to 12:30 pm). The “4 Maps Refractive” display, generated by the instrument's software from enrolled eyes, was exported as a high-resolution image, following previously outlined methods;⁵ only images meeting the quality criteria of the instrument's software were considered. De-identified images were randomly presented to a trained ophthalmology resident (M.A.M) and cornea specialist (T.K.E), blinded to patient outcomes, for independent evaluation of the tomography maps, assessing the loss of regular isopachs and the displacement of the thinnest point of the cornea, and focal posterior surface depression (Figure 1).



The sample size was calculated using G* power software version 3.1.9.2, based on a study by Abdelbary et al which reported a change in corneal thickness with an effect size of 0.957.¹³ Using *t*-tests for dependent means, with an effect size of 0.957, α error of 0.05, and power of 0.8, the required sample size was determined to be 11 cases. To account for dropouts or missed data, the sample size was increased to 50 cases.

Surgical Procedure

All 2.8-mm phacoemulsification procedures were conducted, using Geuder Megatron S4 (Germany) machine, by two experienced surgeons (T.K.E and A.S.B). The surgeries took place with patients' eyes under peribulbar anesthesia, employing a standard dispersive-cohesive viscoelastic soft-shell technique, as previously outlined.¹⁴ Following surgery, 0.3% tobramycin and 0.1% dexamethasone eye drops were administered four times daily throughout the initial week and gradually tapered over the subsequent three weeks. At the second postoperative visit (postoperative day 7), patients' corneas were clinically graded by the cornea specialist (T.K.E) and trained resident (M.A.M), blinded to the tomographic outcomes, as absent, mild (striate keratopathy or Descemet's folds but iris details can be clearly seen), moderate (iris details partially seen through corneal edema) or severe (iris details cannot be seen) corneal edema. If disagreement found, a third masked cornea specialist (A.S.B) would be brought to assess. The follow-up Pentacam imaging was done at the same visit and analyzed as previously mentioned. In cases of postoperative corneal edema observed through slit-lamp examination, 50% compounded glycerin ophthalmic drops were utilized and continued until the patient reported improvement.

Statistical Analysis

Data analysis utilized SPSS software version 25 (SPSS Inc., PASW Statistics for Windows version 25, Chicago: SPSS Inc). Qualitative data were presented using numbers and percentages. For quantitative data, mean \pm standard deviation (SD) was used to describe parametric data, while the median (range) was used for non-parametric data after assessing normality with the Kolmogorov-Smirnov test. Significance was determined at the ≤ 0.05 level, and Bonferroni correction method was used to adjust P values when multiple significance tests were conducted. For comparisons, Chi-Square and Monte Carlo tests assessed qualitative data between groups, and the McNemar test compared pre- and post-treatment. Wilcoxon-signed-rank test was used to compare two paired readings for non-normally distributed data within the same group and Mann-Whitney *U*-test to compare two studied groups with non-normally distributed data. Paired *t*-tests compared two paired readings for normally distributed data, and Student's *t*-tests compared two studied groups with normally distributed data. The Spearman's rank-order correlation gauged the strength and direction of a linear relationship between two non-normally distributed continuous or ordinal variables. Binary logistic regression, employing the Stepwise/Forward Wald/Enter technique, evaluated the impact of combinations of more than two independent variables on dichotomous outcomes.

Results

Our study included 25 FECD eyes with SCE (25 patients), versus age and gender-matched 25 FECD eyes without SCE (25 patients) who underwent uneventful phacoemulsification surgery and were successfully imaged perioperatively. A trend with higher age in the SCE-group was found, but age was adjusted for in the regression models. Differences in cumulative dissipated energy and ultrasound time during phacoemulsification between groups were not statistically significant. [Table 1](#) summarizes demographics and baseline clinical characteristics of both groups. No disagreement was found between both observers regarding the perioperative tomographic evaluation in the studied eyes.

The visual acuity had significantly improved for FECD-SCE group and FECD without SCE group ($P < 0.001$, effect size = 4.25 and $P < 0.001$ with effect size = 3.64, respectively) ([Table 2](#)). Clinically, no postoperative corneal edema was observed in FECD without SCE group, while 23 (92%) had mild edema, and 2 (8%) had moderate edema in FECD-SCE group ($P = 0.001$). No disagreement was found in clinical evaluation of postoperative corneal edema. All cases with corneal edema had resolved with topical glycerin 50% every 8 hours by the third postoperative visit (14 ± 2.1 days).

Compared to preoperative, there was a significant increase in CCT and TCT in both groups (both $P < 0.001$; [Table 2](#)), associated with significant central flattening of the anterior corneal surface only in FECD-SCE group ($P = 0.07$), compared to Group B ($P = 0.55$).

[Table 3](#) illustrates the frequency of tomographic patterns in both groups pre- and post-operatively. No significant increase in the frequency of irregular isopachs and posterior surface depression was observed in both groups compared to the preoperative one ([Figure 1](#)). However, there was a statistically significant increase in the frequency of displacement of the thinnest point in FECD-SCE group compared to preoperatively ($P = 0.008$).

Table 1 Demographic, Clinical and Tomographic Characteristics of the Studied Cases

	FECD-SCE Group N = 25	FECD without SCE Group N = 25	Test of Significance
Age (years) Mean \pm SD (median, range)	67.04 \pm 8.11 (70, 43–75)	58.80 \pm 21.89 (66, 39–74)	Z = 0.49 P = 0.62
Sex N (%)			
Male	10(40%)	10(40%)	$\chi^2 = 0.0$
Female	15(60%)	15(60%)	P = 1.0
Side N (%)			
Right	15(60%)	19(76%)	$\chi^2 = 1.47$
Left	10(40%)	6(24%)	P = 0.22
Phacoemulsification time (seconds) Mean \pm SD (median, range)	3.12 \pm 1.44 (3, 1.1–6.9)	3.76 \pm 4.51 (3, 0.9–13.1)	Z = 1.22 P = 0.22
Visual acuity (LogMAR), Mean \pm SD (median, range)	0.97 \pm 0.15 (1, 0.6–1.08)	1.02 \pm 0.14 (1.08, 0.6–1.18)	Z = 1.23 P = 0.21
Mean Anterior keratometry (Diopter), Mean \pm SD	44.47 \pm 2.18	43.11 \pm 2.05	t = 3.95 P = 0.1
Central corneal thickness (microns), Mean \pm SD (median, range)	520.16 \pm 27.19 (534, 470–547)	513.96 \pm 50.97 (516, 436–619)	Z = 1.52 P = 0.12
Thinnest location (microns), Mean \pm SD (median, range)	512.12 \pm 26.22 (525, 465–539)	503.08 \pm 64.23 (515, 448–613)	Z = 2.4 P = 0.03*

Notes: t: Student t test; *: Statistically significant; χ^2 : Chi-Square test, Z: Mann Whitney U-test.

Table 2 Comparison Between Both Groups Regarding Pre- and Post-Operative Visual Acuity, Central and Thinnest Corneal Locations

		FECD-SCE Group N = 25	FECD without SCE Group N = 25	Test of Significance
Visual acuity (logMAR)	Pre-operative	1(0.6–1.08)	1.08(0.6–1.18)	Z = 1.23 P = 0.22
	Post-operative	0.477(0.3–0.60)	0.477(0.18–0.78)	Z = 0.28 P = 0.78
Comparison of pre- and post-operative data		P < 0.001*	P < 0.001*	
Central corneal thickness (microns)	Pre-operative	534(470–547)	516(436–619)	Z = 1.52 P = 0.13
	Post-operative	584(531–686)	548(450–634)	Z = 2.36 P = 0.018*
Comparison of pre- and post-operative data		P < 0.001*	P < 0.001*	
Thinnest location (microns)	Pre-operative	525(465–539)	515(448–613)	Z = 2.4 P = 0.03*
	Post-operative	558(527–675)	536(360–625)	Z = 2.6 P = 0.02*
Comparison of pre- and post-operative data		P < 0.001*	P < 0.001*	

Note: *Statistically significant.

Table 3 Tomographic Patterns of the Studied Groups Pre- & Post-Operative

			FECD-SCE Group N = 25	FECD without SCE Group N = 25	Test of Significance
Irregular isopachs	Pre-operative	No Yes	11(44.0) 14(56.0)	25(100.0) 0(0.0)	$\chi^2 = 19.44$ P = 0.001*
	Post-operative	No Yes	6(24.0) 19(76.0)	25(100.0) 0(0.0)	$\chi^2 = 30.64$ P = 0.001*
Comparison of pre and post operative data			P = 0.062	P = 1.0	
Posterior surface depression	Pre-operative	No Yes	9(60.0) 16(40.0)	25(100.0) 0(0.0)	$\chi^2 = 23.59$ P < 0.001*
	Post-operative	No Yes	6(60.0) 19(40.0)	25(100.0) 0(0.0)	$\chi^2 = 30.65$ P < 0.001*
Comparison of pre- and post-operative data			P = 0.083	P = 1.0	
Displacement of thinnest point	Pre-operative	No Yes	19(76.0) 6(24.0)	25(100.0) 0	$\chi^2 = 6.82$ P = 0.009*
	Post-operative	No Yes	8(32.0) 17(68.0)	25(100.0) 0	MC = 25.76 P = 0.001*
Comparison of pre- and post-operative data			P = 0.008*	P = 1.0	

Notes: χ^2 : Chi-Square test, *statistically significant, MC: Monte Carlo test.

Univariate analysis revealed that the loss of regular isopachs (P = 0.003, CRR: 16.0 (2.16–40.6)) and posterior surface depression (P = 0.036, CRR: 6.0 (1.96–37.4)) were significant predictors of postoperative corneal edema. However, multivariate analysis showed that 94% of postoperative corneal edema could be predicted by the presence of posterior surface depression alone (P = 0.04, ARR = 5.8 (1.89–35.7)) (Table 4).

Table 4 Univariate & Multivariate Regression Analysis for Predictors of Corneal Edema Among Studied Cases

	Univariate		Multivariate	
	P value	CRR (95% CI)	P value	ARR (95% CI)
Age (years)	0.85	1.02(0.831–1.25)		
Sex Male (R) Female	0.13	1 2.44(0.764–7.82)		
Phacoemulsification time (seconds)	0.20	0.318(0.054–1.86)		
Mean keratometry (D)	0.42	5.76(0.075–44.1)		
Central corneal thickness (microns)	0.06	0.985(0.969–1.0)		
Thinnest corneal thickness (microns)	0.81	0.994(0.942–1.05)		
Irregular isopachs	0.003*	16.0(2.16–40.6)	0.15	10.56(0.66–39.68)
Displacement of thinnest point	0.69	1.52(0.85–9.19)		
Posterior surface depression	0.036*	6.0(1.96–37.4)	0.04*	5.8(1.89–35.7)
Overall % predicted = 94.0%				

Note: *Statistically significant, R: reference group.

Abbreviations: CRR, Crude relative risk; ARR, Adjusted relative risk.

Discussion

Our study is the first to report using Scheimpflug tomography patterns to predict corneal edema after phacoemulsification surgery in early FECD. We revealed that while uneventful phacoemulsification surgery in both Fuchs endothelial corneal dystrophy (FECD) groups, with and without subclinical corneal edema (SCE), showed no significant differences in surgical parameters, distinct outcomes emerged postoperatively (Figure 1). Visual acuity significantly improved in both groups, in agreement with Viberg et al, who reported improved visual function in patients with cornea guttata after cataract surgery.¹⁵ However, corneal edema was notably absent in the FECD without SCE group. Conversely, the FECD-SCE group exhibited a high incidence of mild-to-moderate edema. Tomographic analysis demonstrated increased frequency of displacement of the thinnest point in the FECD-SCE group. Notably, posterior surface depression emerged as a significant predictor of postoperative corneal edema, contributing to 94% predictability. These findings underscore the importance of identifying specific tomographic patterns, particularly posterior surface depression, as potential predictors for postoperative outcomes in FECD patients, shedding light on crucial considerations for surgical decision-making and patient management strategies.

Endothelial imaging's utility in assessing FECD severity is restricted, largely due to the interference caused by guttae,¹⁶ therefore considered not optimal for clinical-decision making.⁵ In the presence of guttae, not all endothelial cells are discernible for analysis. Confluent guttae obscure cell visibility entirely, necessitating specialized analysis methods that make assumptions based on the guttae-occupied image area to quantify cell density.¹⁶ Moreover, significant regional discrepancies in guttae distribution can lead to wide variations in cell density measurements within the same cornea, contingent upon the measurement method and location. Consequently, endothelial cell density may not consistently correlate with endothelial function.⁹ On the other hand, several studies had recently reported that corneal tomography may serve as an effective tool for objectively grading disease severity in FECD and aiding in surgical decision-making.^{5,6,9,17–19}

In 2019, Sun et al studied 93 eyes with varying degrees of Fuchs endothelial corneal dystrophy (FECD) and 74 normal corneas. They aimed to evaluate Scheimpflug tomography's ability to detect subclinical corneal edema in FECD and propose a new FECD classification. Three tomographic features—loss of regular isopachs, displacement of the thinnest corneal point, and posterior surface depression—were found in all FECD corneas with definite edema, over 81% of suspected subclinical edema cases, and less than 42% of non-edematous cases. Less than 5% of normal corneas showed these features. Corneas with suspected subclinical edema that underwent endothelial keratoplasty (EK) showed improvements post-EK, confirming preoperative subclinical edema.⁵

In 2020, Patel et al recommended evaluating pachymetry and posterior elevation maps in FECD when patients present with visual symptoms or are considering cataract surgery. This method is more clinically significant than measuring CCT alone, especially if prior FECD evaluation has not been done and corneal edema is not evident.⁶ They identified loss of regular isopachs, displacement of the thinnest point, and focal posterior surface depression as risk factors for FECD progression, whereas CCT was not.⁶ They also developed a predictive model for corneal improvement after Descemet membrane endothelial keratoplasty (DMEK) that outperformed preoperative CCT predictions, offering potential clinical and research applications.¹⁷

In a retrospective study of 115 eyes undergoing DMEK for FECD, Santana et al used Scheimpflug-derived parameters preoperatively and 6 months postoperatively to assess DMEK's impact based on FECD severity and subclinical edema. Eyes without preoperative edema showed more parameters reversing to “normal” than those with subclinical edema.¹⁸ In a prospective study, Arnalich-Montiel et al established a risk prediction model for EK post-cataract surgery using Scheimpflug imaging. The risk for EK within two years significantly increased with more tomographic features.¹⁹ These studies support using Scheimpflug measurements to grade FECD and predict edema, aiding preoperative decisions.

One limitation of the study pertained to the utilization of the Pentacam system, which may not necessarily offer interchangeable predictions for corneal edema compared to other commonly employed systems. Consequently, further investigation into these variations is warranted. Additionally, the absence of a definitive standard for determining the necessity of topical hygroscopic agents posed another limitation. Nevertheless, our evaluation encompassed factors such as phacoemulsification time, intraoperative manipulations, and assessment of visual acuity. While our study was of short duration and small sample size, precluding definitive conclusions regarding the long-term effects of cataract surgery based on tomographic map features, most events within our cohort occurred within the initial 7 days. Although tomographic maps did not measure

the influence of guttae on corneal edema prediction, the risk for corneal edema remained consistent across patients having tomographic features, including those with guttae but with subclinical edema, indicating a need for further investigation into this possibility.

In essence, our findings endorse the use of tomographic patterns for early identification of FECD eyes susceptible to corneal edema following uncomplicated cataract surgery, thereby optimizing visual outcomes. The widespread accessibility and straightforward interpretation of the Pentacam system make tomographic maps a valuable resource for clinicians in patient counseling, consent acquisition, and surgical planning, particularly in cases where corneal edema is not readily apparent. This predictive capability can be readily integrated into routine clinical practice, facilitating proactive measures to ensure postoperative corneal clarity or prompt referral to specialists in EK if necessary. External validation of our findings with longer-term follow-up is imperative for further validation.

Data Sharing Statement

All data generated or analyzed during this study are available upon request from the corresponding author.

Acknowledgment

We thank Dr. Hend Magdy, assistant professor of public health and biostatistics at Mansoura University, for conducting the statistical analysis.

Funding

There is no funding to report.

Disclosure

The authors report no conflicts of interest in this work.

References

1. Prokofyeva E, Wegener A, Zrenner E. Cataract prevalence and prevention in Europe: a literature review. *Acta Ophthalmol.* 2013;91(5):395–405. doi:10.1111/j.1755-3768.2012.02444.x
2. Sharma N, Singhal D, Nair S, et al. Corneal edema after phacoemulsification. *Ind J Ophthalmol.* 2017;65(12):1381. doi:10.4103/ijo.IJO_871_17
3. Rodrigues MM, Krachmer JH, Hackett J, et al. Fuchs' corneal dystrophy: a clinicopathologic study of the variation in corneal edema. *Ophthalmology.* 1986;93(6):789–796. doi:10.1016/S0161-6420(86)33674-1
4. Aiello F, Gallo Afflitto G, Ceccarelli F, Cesareo M, Nucci C. Global prevalence of fuchs endothelial corneal dystrophy (FECD) in adult population: a systematic review and meta-analysis. *J Ophthalmol.* 2022;2022(1):3091695.
5. Sun SY, Wacker K, Baratz KH, et al. Determining subclinical edema in Fuchs endothelial corneal dystrophy: revised classification using Scheimpflug tomography for preoperative assessment. *Ophthalmology.* 2019;126(2):195–204. doi:10.1016/j.ophtha.2018.07.005
6. Patel SV, Hodge DO, Treichel EJ, et al. Predicting the prognosis of Fuchs endothelial corneal dystrophy by using Scheimpflug tomography. *Ophthalmology.* 2020;127(3):315–323. doi:10.1016/j.ophtha.2019.09.033
7. Seitzman GD, Gottsch JD, Stark WJ. Cataract surgery in patients with Fuchs' corneal dystrophy: expanding recommendations for cataract surgery without simultaneous keratoplasty. *Ophthalmology.* 2005;112(3):441–446. doi:10.1016/j.ophtha.2004.10.044
8. van Cleynenbreugel H, Remeijer L, Hillenaar T. Cataract surgery in patients with Fuchs' endothelial corneal dystrophy: when to consider a triple procedure. *Ophthalmology.* 2014;121(2):445–453. doi:10.1016/j.ophtha.2013.09.047
9. Patel SV. Towards clinical trials in Fuchs endothelial corneal dystrophy: classification and outcome measures—the Bowman Club Lecture 2019. *BMJ Open Ophthalmol.* 2019;4(1):e000321.
10. Adamis AP, Filatov V, Tripathi BJ, et al. Fuchs' endothelial dystrophy of the cornea. *Surv Ophthalmol.* 1993;38(2):149–168. doi:10.1016/0039-6257(93)90099-S
11. Wacker K, McLaren JW, Amin SR, et al. Corneal high-order aberrations and backscatter in Fuchs' endothelial corneal dystrophy. *Ophthalmology.* 2015;122(8):1645–1652. doi:10.1016/j.ophtha.2015.05.005
12. Liu Z, Huang AJ, Pflugfelder SC. Evaluation of corneal thickness and topography in normal eyes using the Orbscan corneal topography system. *Br J Ophthalmol.* 1999;83(7):774–778. doi:10.1136/bjo.83.7.774
13. Abdelbary R, Kamel R, Elkhoully HE. Quantitative evaluation of corneal edema after phacoemulsification surgery using corneal densitometry. *Egypt J Ophthalmol.* 2022;2(2):99–110.
14. Arshinoff SA. Dispersive-cohesive viscoelastic soft shell technique. *J Cataract Refract Surg.* 1999;25(2):167–173. doi:10.1016/S0886-3350(99)80121-7
15. Viberg A, Liv P, Behndig A, et al. The impact of corneal guttata on the results of cataract surgery. *J Cataract Refract Surg.* 2019;45(6):803–809. doi:10.1016/j.jcrs.2018.12.023
16. McLaren JW, Bachman LA, Kane KM, et al. Objective assessment of the corneal endothelium in Fuchs' endothelial dystrophy. *Invest Ophthalmol Visual Sci.* 2014;55(2):1184–1190. doi:10.1167/iovs.13-13041

17. Patel SV, Camp JJ, Hodge DO, et al. Predicting corneal improvement after Descemet membrane endothelial keratoplasty for Fuchs endothelial corneal dystrophy. *Ophthalmol Sci.* **2022**;2(2):100128. doi:10.1016/j.xops.2022.100128
18. Santana SV, Vasiliauskaitė I, van Dijk K, et al. Impact of Fuchs Endothelial Corneal Dystrophy Severity on Scheimpflug-Derived Parameters After Descemet Membrane Endothelial Keratoplasty. *Cornea.* **2023**;42(8):970–979. doi:10.1097/ICO.0000000000003115
19. Arnalich-Montiel F, de-Arriba-Palomero P, Muriel A, et al. A risk prediction model for endothelial keratoplasty after uncomplicated cataract surgery in Fuchs endothelial corneal dystrophy. *Am J Ophthalmol.* **2021**;231:70–78. doi:10.1016/j.ajo.2021.04.016

Clinical Ophthalmology

Dovepress

Publish your work in this journal

Clinical Ophthalmology is an international, peer-reviewed journal covering all subspecialties within ophthalmology. Key topics include: Optometry; Visual science; Pharmacology and drug therapy in eye diseases; Basic Sciences; Primary and Secondary eye care; Patient Safety and Quality of Care Improvements. This journal is indexed on PubMed Central and CAS, and is the official journal of The Society of Clinical Ophthalmology (SCO). The manuscript management system is completely online and includes a very quick and fair peer-review system, which is all easy to use. Visit <http://www.dovepress.com/testimonials.php> to read real quotes from published authors.

Submit your manuscript here: <https://www.dovepress.com/clinical-ophthalmology-journal>