

Familial Acute Promyelocytic Leukemia: A Case Report and Review of the Literature

Mingqi Yang^{1,2}, Lian Bai³, Yunju Ma^{1,2}, Xuanqi Cao^{1,2}, Qingya Cui^{1,2}, Depei Wu^{1,2}, Xiaowen Tang^{1,2}

¹National Clinical Research Center for Hematologic Diseases, Jiangsu Institute of Hematology, The First Affiliated Hospital of Soochow University, Suzhou, People's Republic of China; ²Institute of Blood and Marrow Transplantation, Collaborative Innovation Center of Hematology, Soochow University, Suzhou, People's Republic of China; ³Canglang Hospital of Suzhou, Suzhou, People's Republic of China

Correspondence: Xiaowen Tang; Depei Wu, Department of Hematology, The First Affiliated Hospital of Soochow University, Jiangsu Institute of Hematology, Suzhou, People's Republic of China, Tel +8613913538266; +8613951102021, Email xwtang1020@163.com; drwudepei@163.com

Abstract: Acute promyelocytic leukemia (APL) is characterized by a reciprocal translocation t(15;17)(q24;q21), which leads to the fusion of PML and RAR α genes known as PML-RAR α fusion. A few cases of potentially hereditary leukemia-related genes in APL have been reported, but no instances of familial aggregation of APL have been documented. Here, we describe a family in whom two members successively affected by APL. The potential familial association observed in these two cases of APL highlights the need for further investigation and more definitive genetic lineage tracing in order to understand the genetic basis of this disease.

Keywords: familial, acute promyelocytic leukemia, APL differentiation syndrome, hereditary predisposition, germline mutation

Introduction

Acute promyelocytic leukemia (APL) is known for its aggressive onset, characterized by distinct coagulopathy and a high risk of severe bleeding, leading to a significant early mortality rate.^{1,2} Management of hyperleukocytosis without delay is essential especially in critical cases. The combined use of all-trans retinoic acid (ATRA) and arsenic trioxide (ATO) during induction therapy has substantially improved the prognosis of APL, resulting in a long-term survival rate of nearly 90%.³

Despite this remarkable therapeutic progress, it is still unclear whether hereditary aspects play a potential role in the occurrence and development of this disease. Familial leukemia is generally inherited through genetic mutations. Reports of fusion genes are more common in familial CML (Chronic Myeloid Leukemia).^{4,5} While a few cases of potentially hereditary leukemia-related genes in APL have been reported,⁶ no instances of familial aggregation of APL have been documented. It is worth noting that The 2016 revision of the WHO classification of myeloid neoplasms and acute leukemia added a section on myeloid neoplasms with germline predisposition, including the germline *RUNX1* gene mutation which the patients shared in this case. In this report, we present a case of adult male APL patient whose daughter suffered from the same disease successively.

Case Presentation

Case 1 (Father)

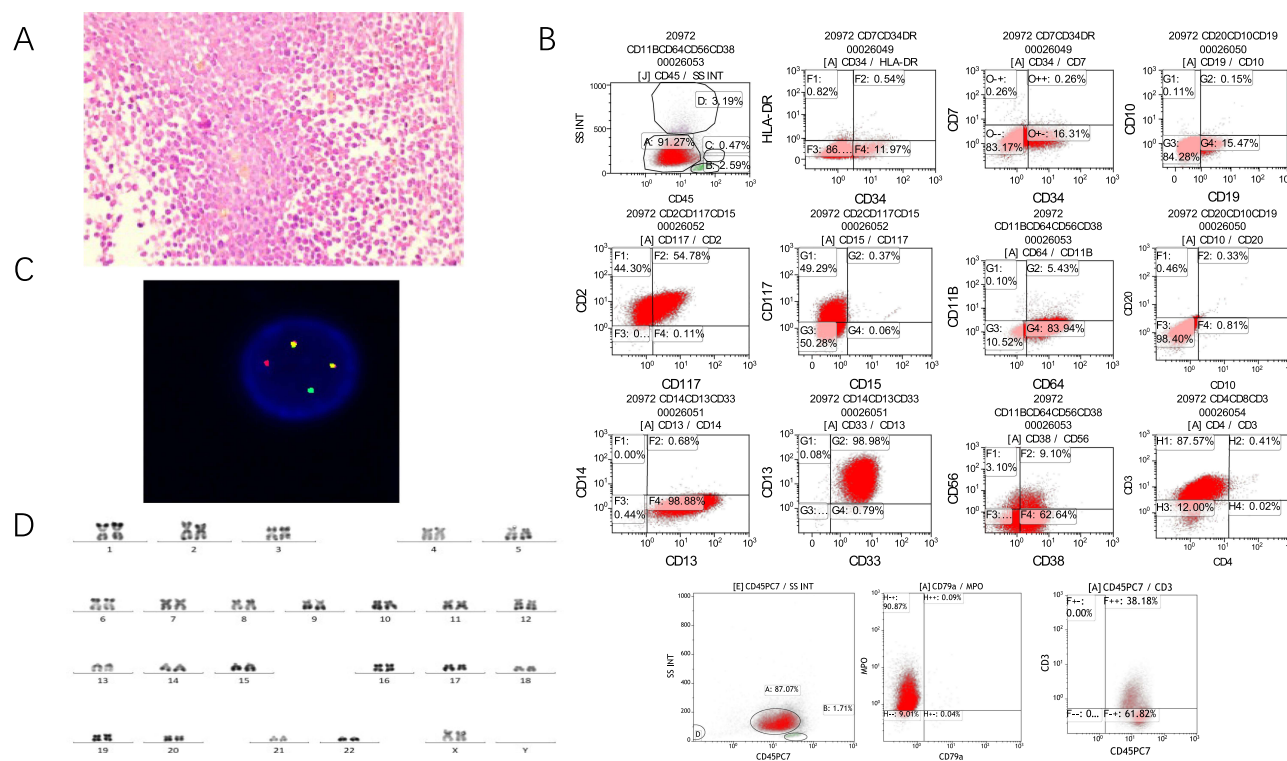
In May 2012, a 36-year-old man (patient 1) presented to the hematology department of our hospital with a several-day history of sore throat and low-grade fevers. His white blood cells (WBC) count was $3.54 \times 10^9/L$, hemoglobin (Hgb) 137g/L, and platelets (PLT) $126 \times 10^9/L$. Coagulation function tests indicated no significant abnormalities. Morphological examination and flow cytometric immunotyping of bone marrow (BM) were consistent with the phenotype of APL, with the typical L-type PML-RAR α fusion gene transcript caused by t(15;17)(q24;q21) translocation. Next-generation sequencing (NGS) identified a heterozygous germline mutation of *RUNX1* on chromosome 21q22.12 (47.8%). Based on these results, this patient was diagnosed with APL. After being classified as a low-risk group,⁷ this patient underwent ATRA

induction chemotherapy (20 mg once daily) combined with ATO (10 mg once daily) and achieved complete remission in one month, followed by seven courses of idarubicin (20mg d1, 10mg d2-3) monotherapy consolidation regimen. Maintenance chemotherapy consists of the sequential use of ATRA, 6-Mercaptopurine (6-MP), and methotrexate (MTX).⁷ The patient remains in minimum residual disease (MRD) negative remission at the cellular and molecular (*PML-RARα*) levels, with a leukemia-free survival (LFS) of 11 years and 5 months to date.

Case 2 (Daughter)

Patient 2 is a 23-year-old woman (and daughter of patient 1), who presented to her local emergency department in June 2023 with a history of intermittent fevers lasting seven days. She reported a peak temperature (Tmax) of 39.7°C, as well as chest tightness and cough. The results of a blood routine examination showed hyperleucocytosis (WBC: $179.67 \times 10^9/L$), anemia (hemoglobin: 99g/L) and thrombocytopenia (PLT: $23 \times 10^9/L$). These findings were accompanied by splenomegaly (about 8 rib units) and coagulopathy, including diffuse systemic mucocutaneous bleeding. A peripheral blood smear indicated a high percentage of promyelocytes (96%). Coagulation function tests showed a prolonged prothrombin time (PT) of 21.01s (normal: 9.8–12.1s), decreased fibrinogen levels of 1.01g/L (normal: 1.8–3.5g/L), and elevated fibrinogen degradation products (FDP) of 38.78mg/L (normal: 0–5mg/L). Despite undergoing chemotherapy with hydroxyurea, the patient's WBC count remained high. Additionally, the patient experienced dizziness and headaches. Neurological examination revealed drowsiness and incoherent speech. An urgent head CT scan showed bilateral cerebellar hemisphere hemorrhage, fourth ventricular hemorrhage, and potential leukemic infiltration of the cerebellum.

Considering this clinical emergency, the patient was transferred to our hospital's hematology intensive care unit (HICU) for further treatment. BM aspirates revealed a high percentage of abnormal promyelocytes, accounting for approximately 97% of the total nucleated cells [Figure 1A]. Flow cytometry showed the blasts (CD34±CD11+HLA-DR-) co-expressed myeloid (myeloperoxidase, CD117, CD13, CD33, and CD64) and T-lineage (cytoplasmic CD3, and CD2) markers, suggestive of mixed-phenotype acute leukemia (MPAL), T/myeloid [Figure 1B].



Cytogenetic analysis showed an abnormal karyotype of 46,XX, t(15,17)(q24;q21) [Figure 1C and D]. Molecular genetic analysis detected a typical S-type *PML-RARα* fusion transcript, approximately 91% in abundance. At the time of diagnosis, the expression of *WT1* fusion gene was 253.43%, and NGS revealed an internal tandem duplication of the *FLT3* gene (*FLT3-ITD*). It is noticeable that germline *RUNX1* mutation on chromosome 21q22.12 was also detected just like the proband patient. Other two variants of probable germline origin were identified in *FAT1* (48.20%), and *MGA* (48.20%). A diagnosis of APL, classified as high-risk, was confirmed. The patient presented with multiple comorbidities including intracranial hemorrhage and disseminated intravascular coagulation (DIC), posing significant therapeutic challenges. Along with all prompt and comprehensive supportive measures, the patient was administered hydroxyurea 500mg three times a day (TID) as cytoreductive chemotherapy together with induction therapy consisting of ATRA (20mg/day) in combination with CHDT (1.08g TID). However, after one day, the patient was in a drowsy state, and developed a fever with a Tmax of 37.8°C without any infectious etiology. The blood routine examination showed extreme hyperleukocytosis, with the WBC count continuing to rise and reaching a peak of $238.04 \times 10^9/L$. The patient developed respiratory failure and underwent high-flow oxygen therapy. These symptoms raised suspicion of severe differentiation syndrome (DS), also known as retinoic acid syndrome (RAS).⁸ Consequently, ATRA induction therapy was immediately stopped, and treatment was initiated with intravenous dexamethasone at a dose of 5mg twice daily, and Janus kinase (JAK) inhibitor ruxolitinib oral tablet at a dose of 10mg twice daily. Continuous renal replacement therapy (CRRT) was provided at the bedside to support the major organs. These interventions led to an overall improvement in the patient's condition.

Due to the limited cytoreductive effectiveness of hydroxyurea, low-dose venetoclax was added to the therapy regimen, with the dosage adjusted according to the WBC count. The WBC count gradually decreased, and remained stable at a relatively low level of $10 \times 10^9/L$. Finally, the induction differentiation therapy was initiated, consisting of ATRA (20mg once daily) in combination with ATO (10 mg once daily).

Following completion of a course of induction therapy, the peripheral blood counts stabilized. Bone marrow aspiration demonstrated 3.5% promyelocytes. MRD was found to be less than 6.6×10^{-5} . No *PML-RARα* fusion gene or somatic mutations were detected. The examinations of cerebrospinal fluid showed no abnormalities. These findings indicated that the patient achieved deep molecular CR following the induction therapy. Currently, the patient has received one course of idarubicin (20mg on day 1, 10mg on days 2–3) as monotherapy for consolidation. The patient will continue to be followed up in our clinic for further treatment.

Discussion

We have described a rare instance of familial cases of APL in this report. In this familial case of APL, the risk stratification and clinical treatment difficulty differed significantly between the father and daughter [Table 1]. The daughter's APL was characterized by a high WBC count at diagnosis, categorizing her as high-risk. Flow cytometry showed an unusual immunophenotype with co-expression of myeloid and T-lineage differentiation, which is extremely rare in APL.^{9–11} It is worth noting that the presence of an internal tandem duplication (ITD) of the FMS-like tyrosine kinase 3 gene (*FLT3-ITD*) is detected in 13–40% of APL patients and is associated with a higher WBC count and a poorer prognosis compared to those without this mutation.^{12–14} However, additional prospective trials are required to confirm these findings.

There are three major isoforms of the typical *PML-RARα* fusion gene resulting from different breakpoints within the PML gene: intron 6, bcr-1 (L, long form); exon 6, bcr-2 (V, variable form) and intron 3, bcr-3 (S, short form).¹⁵ The prognostic features associated with these isoforms are still controversial. However, patients expressing the S-type isoform have been observed to have shorter leukemia-free and overall survival durations compared to those expressing the L-type isoform.¹⁶ These suggest the daughter (patient 2) a more challenging treatment process for her than her father (patient 1) due to the combination of numerous comorbidities.

Both patients had no other oncologic malignancy during their lifetime, and we noticed that a germline *RUNX1* gene mutation on 21q22.12 was found in both patients, which has been confirmed and reported to be responsible for syndromic thrombocytopenia and predisposition to AML.^{17–19} Most of the familial platelet disorder with predisposition to myeloid malignancy (FPDMM) families harbor germline *RUNX1* variants, which have been found in up to 20–60% of

Table I Laboratory Features of the Two Patients at Diagnosis

	Patient 1 (May 2012)	Patient 2 (June 2023)
WBC/Hb/PLT($\times 10^9/L$ / g/L / $\times 10^9/L$)	3.54/137/126	179.67/99/23
Morphology	APL	APL
Immunophenotype	Specific reports are not available	Immature cells with mixed expression of myeloid and T-lymphoid markers expressed CD19,CD20,CD38,CLL-I,CD22
Cytogenetics	46,XY, t(15,17)(q24;q21)	46,XX, t(15,17)(q24;q21)
Molecular biomarkers		
PML-RAR α	Positive (L-type)	Positive (S-type)
FLT3-ITD	Positive	Negative
RUNX1 germline mutations	Positive	Positive
FAT1 germline mutations	Positive	Negative
MGA germline mutations	Positive	Negative

Abbreviations: WBC, white blood cells; Hb, hemoglobin; PLT, platelets; APL, acute promyelocytic leukemia.

sporadic cases of MDS/AML.^{20,21} Translational investigations of mechanisms of familial platelet disorder with propensity to myeloid malignancy (FPD) offers the potential to benefit these patients.²² The genes encoding these transcription factors often have recurrent somatic mutations in MDS or AML,²³ and carriers of the same *RUNX1* mutation exhibit heterogeneity in phenotype, resulting in different genetic fusions genes.²⁴ Therefore, the proband patient had the detectable L-type *PML-RAR α* fusion gene transcript, while his daughter had the S-type *PML-RAR α* fusion gene transcript. The 2016 revision of the WHO classification of myeloid neoplasms and acute leukemia added a section on myeloid neoplasms with germline predisposition, such as *CEBPA*, *DDX41*, *RUNX1*, *ANKRD26*, *ETV6*, and *GATA2* mutations.²⁵ These examples offer a unique insight into the underlying etiology of hematological malignancies. Since the latent mechanisms related have not been thoroughly investigated in the current study, we need more researches to explore the issues related to clinical heterogeneity cases, and to consider whether transplantation donors with these kinds of mutations may affect the implantation of hematopoietic stem cells, and even the possibility of recurrence.

For high-risk APL patients with hyperleukocytosis, the rational utilization of cytoreduction therapy promptly before initiating induction therapy plays a crucial role in reducing early mortality rates. Venetoclax, a BCL-2inhibitor, has been reported to be a more favorable option as a cytoreduction therapy for APL patients, as it can reduce reliance on platelet and plasma infusion, and has a lower incidence of DS.²⁶ In this case, we ultimately decided to add low-dose venetoclax during treatment, and achieved encouraging effect.

Rigorous monitoring of vital signs, weight, urine output, and electrolyte levels is necessary during ATRA plus ATO induction therapy to detect any signs of ATRA-induced differentiation. In cases of aggressive coagulopathy, immediate administration of fibrinogen, platelet transfusions, and fresh-frozen plasma should be performed to correct the condition.

In the literature, few articles reporting previous cases of familial APL occurring in immediate generations have been published. Further research in this direction is essential to uncover the underlying candidate genes involved in order to establish a systematic targeted sequencing of genealogy in families with members diagnosed with hematologic malignancies.

Data Sharing Statement

The datasets supporting the conclusions are included within this article.

Ethics Approval Consent to Participate

This study was approved by the Ethics Committee of the First Affiliated Hospital of Soochow University and was conducted in accordance with the Declaration of Helsinki principles. All patients provided written informed consent.

Consent for Publication

Both patients provided written informed consent for their case details to be published. The institutional approval of the First Affiliated Hospital of Soochow University was obtained for the study of the case.

Acknowledgments

The authors would like to thank all members of the study team, the patients and their family.

Author Contributions

Mingqi yang wrote and edited the manuscript; Yunju ma revised the paper; Xiaowen Tang, Qingya Cui and Lian Bai treated the patients; Depei Wu and Xiaowen Tang conceived of the study and revised the paper. All authors made a significant contribution to the work reported, whether that is in the conception, study design, execution, acquisition of data, analysis and interpretation, or in all these areas; took part in drafting, revising or critically reviewing the article; gave final approval of the version to be published; have agreed on the journal to which the article has been submitted; and agree to be accountable for all aspects of the work.

Funding

This work was supported by research grants from National Natural Science Foundation of China (82070162), Frontier Clinical Technical Project of Suzhou Science and Technology plan (SKY2022001), Bethune Charitable Foundation (BCF-IBW-XY-20220930-13), Suzhou diagnosis and treatment project of Clinical Key Diseases (LCZX202201), China International Medical Foundation (Z-2018-31-2102-4), Boxi clinical research project of The First Affiliated Hospital of Soochow University (BXL005), the Priority Academic Program Development of Jiangsu Higher Education Institutions (PAPD).

Disclosure

All authors declare there are no conflicts of interest to report in this work.

References

1. Grimwade D, Lo Coco F. Acute promyelocytic leukemia: a model for the role of molecular diagnosis and residual disease monitoring in directing treatment approach in acute myeloid leukemia. *Leukemia*. 2002;16(10):1959–1973. doi:10.1038/sj.leu.2402721
2. Park JH, Qiao B, Panageas KS, et al. Early death rate in acute promyelocytic leukemia remains high despite all-trans retinoic acid. *Blood*. 2011;118(5):1248–1254. doi:10.1182/blood-2011-04-346437
3. Hu J, Liu YF, Wu CF, et al. Long-term efficacy and safety of all-trans retinoic acid/arsenic trioxide-based therapy in newly diagnosed acute promyelocytic leukemia. *Proc Natl Acad Sci USA*. 2009;106(9):3342–3347. doi:10.1073/pnas.0813280106
4. Caocci G, Atzeni S, Vacca A, Orrù N, Ledda A, La Nasa G. Familial occurrence of chronic myeloid leukemia. *Leuk Lymphoma*. 2009;50(5):854–856. doi:10.1080/10428190902842634
5. Aitken M, Benton CB, Issa GC, Sasaki K, Yilmaz M, Short NJ. Two cases of possible familial chronic myeloid leukemia in a family with extensive history of cancer. *Acta Haematol*. 2021;144(5):585–590. doi:10.1159/000513925
6. Yuan W, Shang Z, Shen K, et al. Case report: germline RECQL mutation potentially involved in hereditary predisposition to acute leukemia. *Front Oncol*. 2023;13:1066083. doi:10.3389/fonc.2023.1066083
7. Chinese Society of Hematology CM, Chinese Medical Association, Chinese Medical Doctor Association. Chinese guidelines for diagnosis and treatment of acute promyelocytic leukemia (2018). *Zhonghua Xue Ye Xue Za Zhi*. 2018;39(3):179–183. doi:10.3760/cma.j.issn.0253-2727.2018.03.002
8. Stahl M, Tallman MS. Differentiation syndrome in acute promyelocytic leukaemia. *Br J Haematol*. 2019;187(2):157–162. doi:10.1111/bjh.16151
9. Liu W, Xu J. Microgranular acute promyelocytic leukemia with expression of T-cell markers mimicking mixed-phenotype acute leukemia. *Blood*. 2020;135(11):880. doi:10.1182/blood.2019004434
10. Singh ZN, Duong VH, Koka R, et al. High-risk acute promyelocytic leukemia with unusual T/myeloid immunophenotype successfully treated with ATRA and arsenic trioxide-based regimen. *J Hematop*. 2018;11(3):67–74. doi:10.1007/s12308-018-0329-z
11. Chapiro E, Delabesse E, Asnafi V, et al. Expression of T-lineage-affiliated transcripts and TCR rearrangements in acute promyelocytic leukemia: implications for the cellular target of t(15;17). *Blood*. 2006;108(10):3484–3493. doi:10.1182/blood-2005-09-009977

12. Breccia M, Loglisci G, Loglisci MG, et al. FLT3-ITD confers poor prognosis in patients with acute promyelocytic leukemia treated with AIDA protocols: long-term follow-up analysis. *Haematologica*. 2013;98(12):e161–3. doi:10.3324/haematol.2013.095380
13. Niu C, Yan H, Yu T, et al. Studies on treatment of acute promyelocytic leukemia with arsenic trioxide: remission induction, follow-up, and molecular monitoring in 11 newly diagnosed and 47 relapsed acute promyelocytic leukemia patients. *Blood*. 1999;94(10):3315–3324. doi:10.1182/blood.V94.10.3315.422k16_3315_3324
14. Picharski GL, Andrade DP, Fabro A, et al. The impact of Flt3 gene mutations in acute promyelocytic leukemia: a meta-analysis. *Cancers (Basel)*. 2019;11(9):1311. doi:10.3390/cancers11091311
15. González M, Barragán E, Bolufer P, et al. Pretreatment characteristics and clinical outcome of acute promyelocytic leukaemia patients according to the PML-RAR alpha isoforms: a study of the PETHEMA group. *Br J Haematol*. 2001;114(1):99–103. doi:10.1046/j.1365-2141.2001.02915.x
16. Jurcic JG, Nimer SD, Scheinberg DA, DeBlasio T, Warrell RP Jr, Miller WH Jr. Prognostic significance of minimal residual disease detection and PML/RAR-alpha isoform type: long-term follow-up in acute promyelocytic leukemia. *Blood*. 2001;98(9):2651–2656. doi:10.1182/blood.V98.9.2651
17. Shinawi M, Erez A, Shardy DL, et al. Syndromic thrombocytopenia and predisposition to acute myelogenous leukemia caused by constitutional microdeletions on chromosome 21q. *Blood*. 2008;112(4):1042–1047. doi:10.1182/blood-2008-01-135970
18. Palma-Barqueros V, Bastida JM, López Andreo MJ, et al. Platelet transcriptome analysis in patients with germline RUNX1 mutations. *J Thromb Haemost*. 2023;21(5):1352–1365. doi:10.1016/j.jtha.2023.01.023
19. Förster A, Decker M, Schlegelberger B, Ripperger T. Beyond pathogenic RUNX1 germline variants: the spectrum of somatic alterations in RUNX1-familial platelet disorder with predisposition to hematologic malignancies. *Cancers (Basel)*. 2022;14(14):3431. doi:10.3390/cancers14143431
20. Babushok DV, Bessler M, Olson TS. Genetic predisposition to myelodysplastic syndrome and acute myeloid leukemia in children and young adults. *Leuk Lymphoma*. 2016;57(3):520–536. doi:10.3109/10428194.2015.1115041
21. Rio-Machin A, Vulliamy T, Hug N, et al. The complex genetic landscape of familial MDS and AML reveals pathogenic germline variants. *Nat Commun*. 2020;11(1):1044. doi:10.1038/s41467-020-14829-5
22. West AH, Godley LA, Churpek JE. Familial myelodysplastic syndrome/acute leukemia syndromes: a review and utility for translational investigations. *Ann NY Acad Sci*. 2014;1310(1):111–118. doi:10.1111/nyas.12346
23. Klcio JM, Mullighan CG. Advances in germline predisposition to acute leukaemias and myeloid neoplasms. *Nat Rev Cancer*. 2021;21(2):122–137. doi:10.1038/s41568-020-00315-z
24. Arber DA, Orazi A, Hasserjian R, et al. The 2016 revision to the World Health Organization classification of myeloid neoplasms and acute leukemia. *Blood*. 2016;127(20):2391–2405. doi:10.1182/blood-2016-03-643544
25. Godley LA. Inherited predisposition to acute myeloid leukemia. *Semin Hematol*. 2014;51(4):306–321. doi:10.1053/j.seminhematol.2014.08.001
26. Qi P, Wang L, Li H, et al. Venetoclax as a cytoreduction therapy for acute promyelocytic leukaemia: a single-centre experience. *Br J Haematol*. 2023;203(5):892–895. doi:10.1111/bjh.19119

OncoTargets and Therapy

Dovepress

Publish your work in this journal

OncoTargets and Therapy is an international, peer-reviewed, open access journal focusing on the pathological basis of all cancers, potential targets for therapy and treatment protocols employed to improve the management of cancer patients. The journal also focuses on the impact of management programs and new therapeutic agents and protocols on patient perspectives such as quality of life, adherence and satisfaction. The manuscript management system is completely online and includes a very quick and fair peer-review system, which is all easy to use. Visit <http://www.dovepress.com/testimonials.php> to read real quotes from published authors.

Submit your manuscript here: <https://www.dovepress.com/oncotargets-and-therapy-journal>