

# Rituximab in the Treatment of Non-Infectious Uveitis: A Review

Haixing Cao , Xiang Ma 

Department of Ophthalmology, The First Affiliated Hospital of Dalian Medical University, Dalian, Liaoning Province, People's Republic of China

Correspondence: Xiang Ma, Department of Ophthalmology, the First Affiliated Hospital of Dalian Medical University, 222 Zhongshan Road, Dalian City, Liaoning Province, People's Republic of China, Tel +8618098876399, Email xma9467@vip.sina.com

**Abstract:** Non-infectious uveitis (NIU) is an immune-mediated disorder manifesting as ocular pain, redness, floaters, and photophobia, and is a leading cause of preventable blindness. Managing NIU presents considerable challenges due to the condition's resistance to high-dose corticosteroids and various immunotherapies. This review assesses the efficacy and safety of rituximab (RTX) in the treatment of NIU, based on individual case reports and small-scale studies. A cohort of 78 patients (20 males, 58 females), with a mean onset age of 32.3 years (range 8–72), was analyzed. Juvenile idiopathic arthritis (JIA) was the most frequently associated comorbidity, affecting 28 patients, while anterior uveitis was the predominant subtype, observed in 26 of 47 cases. Prior to RTX therapy, patients had been treated with an average of 1.7 conventional immunosuppressive agents (range 0–5) and 1.1 biologics (range 0–4). RTX was introduced following the failure of high-dose corticosteroids, immunosuppressive drugs, and biologics to control the uveitis. The median time from diagnosis to RTX initiation was 7.7 years (range 0.25–21). Post-RTX, 44.2% of patients experienced improvement in visual acuity, 79.5% achieved resolution of ocular inflammation, and 8.9% showed partial improvement. Additionally, 81.1% were able to reduce their corticosteroid dosage. Overall, 88.6% (69 out of 78) demonstrated a positive response to RTX treatment. These findings indicate that RTX may serve as an effective therapeutic option for NIU unresponsive to steroids and multiple immunotherapies. It may also warrant consideration as a potential first-line treatment in certain cases.

**Keywords:** non-infectious uveitis, Uveitis, rituximab, RTX, CD20 targeting

## Introduction

Non-infectious uveitis (NIU) is an immune-mediated disorder presenting with symptoms such as ocular pain, redness, floaters, and photophobia, and is recognized as a leading cause of preventable blindness.<sup>1</sup> NIU encompasses various conditions, including juvenile idiopathic arthritis (JIA), Behçet's disease, sarcoidosis, multifocal choroiditis, multiple sclerosis, granulomatous polyangiitis, rheumatoid arthritis, serpiginous choroiditis, sympathetic ophthalmia, Vogt-Koyanagi-Harada syndrome (VKH), and birdshot retinochoroidopathy.<sup>2,3</sup>

The complications of uveitis, which can result in vision loss, include early manifestations such as cystoid macular edema and vitreous haze, and late-stage complications like cataracts, glaucoma,<sup>3</sup> and irreversible retinal damage.<sup>4</sup> Prompt and accurate diagnosis, involving the exclusion of masquerade syndromes, is crucial for initiating early and effective intervention.<sup>5,6</sup>

Corticosteroids are the cornerstone of initial NIU management, delivered systemically, locally via periocular or intravitreal routes, or through intravitreal implants. However, systemic corticosteroids are associated with significant adverse effects, including cataracts, glaucoma, diabetes, and osteoporosis, making their long-term use unfavorable.<sup>4,7–10</sup> For patients with severe or chronic NIU who exhibit inadequate response to corticosteroids, or for those unable to tolerate them or experiencing disease recurrence upon steroid tapering, second-line therapies involve immunosuppressants such as methotrexate, mycophenolate mofetil, and cyclosporine.<sup>11–13</sup> These agents allow for corticosteroid-sparing regimens, reducing related complications. In cases where disease activity persists or these treatments are not tolerated, particularly

in patients with a high risk of vision loss or systemic diseases linked to uveitis, biologics like adalimumab may be employed.<sup>14,15</sup>

Adalimumab has demonstrated particular efficacy in managing uveitis associated with pediatric rheumatic diseases,<sup>16</sup> with pooled response rates approximating 68.0% (95% CI: 65.4–70.6%).<sup>17</sup> While anti-TNF $\alpha$  therapies generally induce clinical improvement, they may fail to control intraocular inflammation in some patients, may be contraindicated, or discontinued due to adverse effects, posing substantial clinical challenges.<sup>18</sup>

Rituximab (RTX), a chimeric mouse/human monoclonal antibody targeting the CD20 antigen on naive and memory B cells, has emerged as a potent therapy for autoimmune diseases resistant to conventional immunosuppressive regimens, through its ability to deplete pathogenic B cells.<sup>19–23</sup> The efficacy of anti-CD20-mediated B-cell depletion in autoimmune disease management highlights the pivotal role B cells play in the pathogenesis and progression of these disorders.<sup>24</sup>

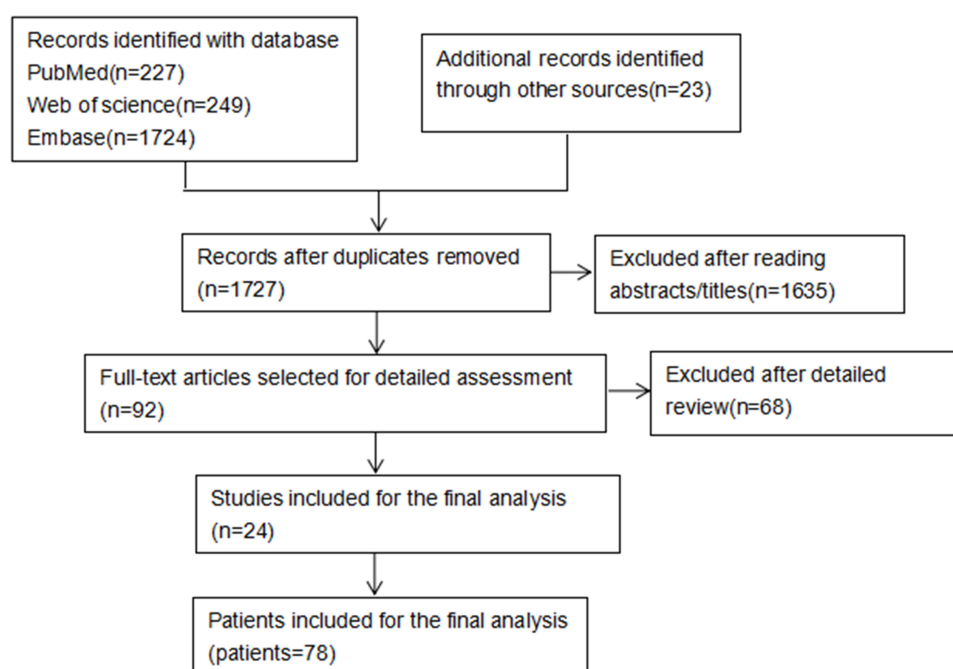
Initially approved for non-Hodgkin B-cell lymphoma, RTX has since become widely utilized in treating B-cell malignancies,<sup>25</sup> primary central nervous system lymphoma,<sup>26</sup> and autoimmune conditions such as rheumatoid arthritis (RA),<sup>27</sup> systemic lupus erythematosus (SLE),<sup>28</sup> and anti-synthetase syndrome.<sup>29</sup> Moreover, RTX has shown promise in managing ocular inflammatory disorders, including refractory peripheral ulcerative keratitis, scleritis, and uveitis.<sup>30</sup>

Recently, RTX has gained increasing attention for its application in the treatment of NIU, as evidenced by case reports and small-scale studies. This review seeks to assess the efficacy and safety of RTX in managing NIU.

## Methods

### Search Strategy

A systematic review was conducted by searching PubMed, Embase, and Web of Science for case reports and case series on patients with NIU treated with RTX up until April 2024, without language restrictions. The search strategy employed terms including “non-infectious uveitis”, “uveitis”, “RTX”, “rituximab”, and “CD20 targeting”. Additionally, a manual review of references from relevant articles was performed to ensure comprehensive coverage. Initial searches and data extraction were carried out by H.C. and X.M., with subsequent review and revision by both to ensure accuracy and rigor in the analysis. Figure 1 presents the flowchart outlining the paper selection process.



**Figure 1** Flowchart of Study Selection Process.

## Inclusion and Exclusion Criteria

Uveitis was classified anatomically according to the International Uveitis Study Group (IUSG) criteria.<sup>31</sup> Two main criteria guided the inclusion of patients: (a) A confirmed NIU diagnosis, meeting IUSG standards, and treatment with RTX; (b) Exclusion of uveitis cases associated with conditions such as syphilis, tuberculosis, herpes simplex virus, varicella-zoster virus, toxoplasmosis, Epstein-Barr virus, and cytomegalovirus. Cases with comprehensive epidemiological data, detailed clinical manifestations, and full therapeutic information were included, while studies reporting large patient cohorts without individual data were excluded.

## Data Collection

Data extracted for analysis included age, sex, clinical features such as uveitis location and the affected eye, and visual acuity both at baseline and post-therapy, reported in Snellen equivalents. Ocular complications were recorded, as well as any prior use of immunosuppressants and biologics. Additional data encompassed the time between initial symptom onset and RTX initiation (in months), RTX treatment protocols, and any adverse reactions or side effects experienced during RTX therapy. This comprehensive dataset facilitated an in-depth assessment of RTX's efficacy and safety in treating NIU.

## Response Criteria

Responsiveness to RTX was evaluated based on the following criteria: (a) Achievement of an inactive disease state or a two-step or greater reduction in inflammation, as graded by the Standardization of Uveitis Nomenclature (SUN) group;<sup>32</sup> (b) A reduction in prednisone dosage to 10 mg per day or less (or an equivalent corticosteroid dose), while maintaining uveitis remission; (c) The original authors' assessment of the patient's clinical status.

## Statistical Analysis

The extracted data were compiled into a database and analyzed using SPSS version 22.0. Continuous variables were described by the number of observations and reported as mean and standard deviation or median and range, as appropriate. Qualitative variables were presented as counts and percentages for the most relevant parameters. McNemar's test was used to evaluate trends across groups for qualitative data, with statistical significance set at an alpha level of 0.05. This methodological approach allowed for robust identification of significant trends and differences within the study population.

## Results

### Baseline Characteristics of the Sample

By April 2024, our comprehensive search across PubMed, Embase, and Web of Science identified 2,200 potentially relevant articles. An additional 23 articles were found through the manual review of bibliographies from the retrieved papers. From these sources, clinical data were extracted for 78 patients who met the inclusion criteria, spanning 24 reports (Table 1). The cohort comprised 10 retrospective studies involving between two and ten patients, 13 case reports, and one randomized single-blind controlled trial.

The key epidemiological features of the 78 patients are summarized in Table 2. The cohort displayed a higher prevalence of females, with 58 women and 20 men. The average age at the commencement of RTX therapy was 32.3 years, with a standard deviation of 17.3, ranging from 8 to 72 years. JIA was the most common comorbid condition associated with uveitis, affecting 28 patients.<sup>35–39</sup> Among the 47 patients with documented uveitis locations, anterior uveitis was the most frequent, present in 26 cases. Other subtypes included intermediate uveitis in 4 patients, posterior uveitis in 11, and panuveitis in 5. Additionally, 2 patients exhibited both anterior and intermediate uveitis, while 3 had both anterior and posterior uveitis. Out of 53 patients with available data on ocular involvement, 41 presented with bilateral uveitis, and 12 with unilateral. The median time from uveitis diagnosis to the initiation of RTX therapy was 7.7 years, with a range from 0.25 to 21 years. Prior to RTX treatment, common ocular complications included synechiae in 29 patients, cataracts in 27, and band keratopathy in 24.

**Table 1** Essential Details and Pre-RTX Information

<b>Patient number</b>	78
<b>Age at the time of therapy (mean, range; years)</b>	31.70
<b>Sex (female/male)</b>	58/20
<b>Immunosuppressants prior to RTX: Common galenic form, dosage, and number of users (n)</b>	
Corticosteroid: Pills; 1–1.5mg/kg/d	75
Methotrexate: Pills, IM, subcut, IV, or intravitreal injections; Initially 7.5–15 mg/week, then 20–25 mg/week.	40
Cyclosporine: Initially capsules, later a micro-emulsion; 50–200 mg/day	34
Mycophenolate Mofetil: pills; 1000–2000 mg/day	24
Cyclophosphamide: Pills: 1–5 mg/kg/day; IV: 500 mg-2 g/dose, every 1–4 weeks	9
Azathioprine; Pills; 2mg/kg/day	9
Leflunomide; Pills; Loading dose 100 mg/day × 3 days, <sup>33</sup> then 20 mg/day	4
Interferon: Subcutaneous; No consensus; Park et al <sup>34</sup> suggested 6–9 MIU/day × 7 days, then 3 MIU 3×/week. Duration: 3–58 months.	3
Tacrolimus: Pills; 0.05 mg/kg/day	2
Chlorambucil: Pills; 0.1–0.2 mg/kg/day.	2
Indomethacin: Pills; 25–50 mg 2–3×/day	1
Hydroxychloroquine: Pills; 200–400 mg/day, 1–2x	2
Sulfasalazine: Pills; 500 mg-1 g 2–3×/day	1
<b>Biological inhibitors prior to RTX (n)</b>	
Infliximab: IV; Initial 5 mg/kg at weeks 0, 2, and 6, then 4–8 week intervals based on response	30
Adalimumab: Subcutaneous; 40mg every 2 weeks	28
Etanercept: Subcutaneous; 0.08 mg/kg/week	24
Abatacept: infusions; 10 mg/kg at 0, 2, and 4 weeks, then every 4–6 weeks	4
Ranibizumab: IV; 0.5 mg (0.05 mL) every 4 weeks × 3 months, then every 4–8 weeks	3
Bevacizumab: IV; 5–10 mg/kg every 2–3 weeks	1
<b>Complications prior to RTX (n)</b>	
Synechiae	29
Cataract	27
Band keratopathy	24
Glaucoma	16
Macular edema	12
Scleritis	6
Epiretinal membrane	5
Retinal vasculitis	3
Phthisis bulbi	2
Peripheral ulcerative keratitis	2
BRVO	2
Serous retinal detachment	2
Opacification of the posterior capsule	1
Optic atrophy	1
Opacification of the posterior capsule	1
Foveal fibrotic scar	1
Choroidal atrophic scars	1
Foveal atrophy secondary	1

## Therapeutic Schemes Before RTX Onset

Before starting RTX therapy, the vast majority of patients (75/78) had undergone intraocular corticosteroid treatment. Additionally, most were treated with conventional immunosuppressive agents, averaging 1.7 agents per patient (range 0–5). The most frequently used immunosuppressants were methotrexate (n=40) and cyclosporine (n=34). Biologic agents were also commonly employed, with an average of 1.1 agents per patient (range 0–4), including infliximab (n=30) and adalimumab (n=28). The switch to RTX was driven by the failure of high-dose corticosteroids, conventional immunosuppressants, or biologics to adequately control active uveitis.

**Table 2** Clinical Course of Patients with NIU Receiving RTX

Ref.	Patient no./Age at Entry, Years/Sex		Disease-Causing Uveitis	Uveitis Type	Visual Acuity Before RTX	Visual Acuity at Last Visit	RTX Treatment Schedule	Steroids Before Rituximab and at the Last Visit	Inflammatory Reaction	RTX Response
1 <sup>35</sup>	1/20/F		JIA	AU	–	–	375 mg/m <sup>2</sup> , 2-week apart	7–2 (drops)	Inactive	Success
	2/15/F		JIA	AU	–	–	375 mg/m <sup>2</sup> , 2-week apart	h–l (drops)	Inactive	Success
	3/21/F		JIA	AU+IU	–	–	375 mg/m <sup>2</sup> , 2-week apart	4–0 (drops)	Inactive	Success
	4/16/F		JIA	AU	–	–	375 mg/m <sup>2</sup> , 2-week apart	4–2 (drops)	Inactive	Success
	5/32/F		JIA	AU	–	–	375 mg/m <sup>2</sup> , 2-week apart	2–2 (drops)	Active	Failure
	6/14/F		JIA	AU	–	–	375 mg/m <sup>2</sup> , 2-week apart	6–1 (drops)	Inactive	Success
	7/22/F		JIA	AU	–	–	375 mg/m <sup>2</sup> , 2-week apart	3–3 (drops)	Inactive	Success
	8/18/F		JIA	AU	–	–	375 mg/m <sup>2</sup> , 2-week apart	2–1 (drops)	Inactive	Success
	9/24/F		JIA	AU	–	–	375 mg/m <sup>2</sup> , 2-week apart	h–h (drops)	Active	Failure
	10/15/F		JIA	AU	–	–	375 mg/m <sup>2</sup> , 2-week apart	6–6 (drops)	Active	Failure
2 <sup>36</sup>	11	Mean age 20.26 (13–34) 2M6F	JIA	–	NLP 20/40	NLP 20/40	1000 mg × 2, 2-week apart, 3rd at 12 or 21 months	7.5–0 mg/d	Inactive	Success
	12		JIA	–	20/200 20/40	20/40 20/40	1000 mg × 2, 2-week apart, 3rd at 12 or 21 months	25–12.5 mg/d	Inactive	Success
	13		JIA	–	20/20 20/20	20/20 20/20	1000 mg×2, 2-week apart, 3rd at 12 or 21 months	0–0 mg/d	Active	Failure
	14		JIA	–	20/25 20/20	20/25 20/20	1000 mg × 2, 2-week apart, 3rd at 12 or 21 months	25–12.5 mg/d	Inactive	Success
	15		JIA	–	20/40 20/60	20/40 20/60	1000 mg × 2, 2-week apart, 3rd at 12 or 21 months	20–12.5 mg/d	Inactive	Success
	16		JIA	–	NLP 20/20	NLP 20/20	1000 mg × 2, 2-week apart, 3rd at 12 or 21 months	15–0 mg/d	Inactive	Success
	17		JIA	–	20/20 20/20	20/20 20/20	1000 mg × 2, 2-week apart, 3rd at 12 or 21 months	0–0 mg/d	Inactive	Success
	18		JIA	–	20/60 NLP	20/60 NLP	1000 mg × 2, 2-week apart, 3rd at 12 or 21 months	20–2.5 mg/d	Inactive	Success

(Continued)

**Table 2** (Continued).

Ref.	Patient no./Age at Entry, Years/Sex	Disease-Causing Uveitis	Uveitis Type	Visual Acuity Before RTX	Visual Acuity at Last Visit	RTX Treatment Schedule	Steroids Before Rituximab and at the Last Visit	Inflammatory Reaction	RTX Response
3 <sup>40</sup>	19/22/F	JIA	AU+PU	NLP 20/40	NLP 20/40	1000 mg × 2, 2-week apart, 3rd at 6 months	7.5–0 mg/d	Inactive	Success
	20/23/F	JIA	AU+PU	20/20 20/200	20/20 20/60	1000 mg × 2, 2-week apart, 3rd at 6 months	25–2.5 mg/d	Inactive	Success
	21/26/F	JIA	AU	20/40 20/20	20/20 20/20	1000 mg × 2, 2-week apart, 3rd at 6 months	25–5 mg/d	Inactive	Success
	22/23/F	JIA	AU	20/25 20/20	20/25 20/20	1000 mg × 2, 2-week apart, 3rd at 6 months	25–0 mg/d	Inactive	Success
	23/22/M	JIA	AU	20/40 20/60	20/40 20/60	1000 mg × 2, 2-week apart, 3rd at 6 months	20–7.5 mg/d	Inactive	Success
	24/34/F	JIA	AU	NLP 20/20	NLP 20/20	1000 mg × 2, 2-week apart, 3rd at 6 months	15–0 mg/d	Inactive	Success
	25/17/F	JIA	AU	20/20 20/20	20/20 20/20	1000 mg × 2, 2-week apart, 3rd at 6 months	0–0 mg/d	Inactive	Success
	26/16/M	JIA	AU+PU	20/60 NLP	20/60 NLP	1000 mg × 2, 2-week apart, 3rd at 6 months	20–0 mg/d	Inactive	Success
4 <sup>38</sup>	27/12/M	JIA	AU	–	–	500 mg/m2, 2-week apart	20–5 mg/d	Active	Failure
5 <sup>39</sup>	28/13/F	JIA	AU	–	–	1000 mg × 2, 2-week apart, 3rd at 6 months	7.5 mg/d-NA	Inactive	Success
	29/55/F	RA	AU	–	–	1000 mg × 2, 2-week apart, 3rd at 6 months	5–5 mg/d	Inactive	Success
	30/26/F	BD	IU	–	–	1000 mg × 2, 2-week apart, 3rd at 6 months	40–20 mg/d	Active	Failure
6 <sup>41</sup>	31/19/F	BD	PU	–	–	1000 mg × 2, 2-week apart	0.5 mg/kg/ d-NA	Improved	Success
	32/17/M	BD	PU	–	–	1000 mg × 2, 2-week apart	0.5 mg/kg/ d-NA	Improved	Success
	33/32/M	BD	PU	–	–	1000 mg × 2, 2-week apart	0.5 mg/kg/ d-NA	Maintained the baseline	Failure

	34/24/M	BD	PU	–	–	1000 mg × 2, 2-week apart	0.5 mg/kg/ d-NA	Improved	Success
	35/28/M	BD	PU	–	–	1000 mg × 2, 2-week apart	0.5 mg/kg/ d-NA	Improved	Success
	36/20/M	BD	PU	–	–	1000 mg × 2, 2-week apart	0.5 mg/kg/ d-NA	Improved	Success
	37/22/M	BD	PU	–	–	1000 mg × 2, 2-week apart	0.5 mg/kg/ d-NA	Improved	Success
7 <sup>42</sup>	38/29/M	BD	–	2/10	8/10	1000 mg × 2, 2-week apart	20–5 mg/d	Improved	Success
8 <sup>43</sup>	39/28/F	VKH	–	20/40 CF	20/20 CF	1000 mg × 2, 2-week apart, 3rd at 6 months	1 mg/kg/d-NA	Inactive	Success
	40/33/F	VKH	–	20/40 20/40	20/30 20/30	1000 mg × 2, 2-week apart, 3rd at 6 months	1 mg/kg/d-NA	Inactive	Success
	41/22/F	VKH	–	20/200 CF	20/30 20/200	1000 mg × 2, 2-week apart, 3rd at 6 months	1 mg/kg/d-NA	Inactive	Success
	42/18/F	VKH	–	20/100 20/200	20/30 20/60	1000 mg × 2, 2-week apart, 3rd at 6 months	1 mg/kg/d-NA	Inactive	Success
	43/20/F	VKH	–	20/30 20/30	20/20 20/20	1000 mg × 2, 2-week apart, 3rd at 6 months	1 mg/kg/d-NA	Inactive	Success
	44/14/F	VKH	–	20/30 20/40	20/20 20/20	375mg/m <sup>2</sup> × 2, 2-week apart, 3rd at 6 months	1 mg/kg/d-NA	Inactive	Success
	45/35/F	VKH	–	20/40 20/40	20/25 20/30	1000 mg × 2, 2-week apart, 3rd at 6 months	1 mg/kg/d-NA	Inactive	Success
	46/8/F	VKH	–	20/80 20/60	20/40 20/40	375mg/m <sup>2</sup> × 2, 2-week apart, 3rd at 6 months	1 mg/kg/d-NA	Inactive	Success
	47/35/F	VKH	–	HM 20/200	HM 20/60	1000 mg × 2, 2-week apart, 3rd at 6 months	1 mg/kg/d-NA	Inactive	Success
9 <sup>44</sup>	48/43/F	VKH	–	20/25 20/22	20/22 20/35	1000 mg × 2, 2-week apart, 3rd at 6 months (if relapse)	DNS - < 10 mg/d	Inactive	Success
	49/50/F	VKH	–	20/22 20/25	20/20 20/20	1000 mg × 2, 2-week apart, 3rd at 6 months (if relapse)	DNS - < 10 mg/d	Inactive	Success

(Continued)

Table 2 (Continued).

Ref.	Patient no./Age at Entry, Years/Sex	Disease-Causing Uveitis	Uveitis Type	Visual Acuity Before RTX	Visual Acuity at Last Visit	RTX Treatment Schedule	Steroids Before Rituximab and at the Last Visit	Inflammatory Reaction	RTX Response
	50/53/F	VKH	–	20/50 20/25	20/20 20/20	1000 mg × 2, 2-week apart, 3rd at 6 months (if relapse)	DNS - < 10 mg/d	Inactive	Success
	51/72/M	VKH	–	20/50 20/28	20/20 20/22	1000 mg × 2, 2-week apart, 3rd at 6 months (if relapse)	DNS - < 10 mg/d	Inactive	Success
	52/57/F	VKH	–	20/25 20/32	20/22 20/50	1000 mg × 2, 2-week apart, 3rd at 6 months (if relapse)	DNS - < 10 mg/d	Inactive	Success
10 <sup>45</sup>	53/8/F	VKH	–	20/100 20/100	20/40 20/40	375 mg/m <sup>2</sup> × 2, 2-week apart, 3rd at 6 months	1 mg/kg/d-NA	Inactive	Success
11 <sup>46</sup>	54/41/F	VKH	–	0.4 CF	0.2 HM	1000 mg × 3, at 1, 6 and 16 months	1 g/d-NA	Inactive	Success
12 <sup>47</sup>	55/17/F	VKH	PAU	–	–	1000 mg × 2, 2-week apart, 3rd at 6 months	5 mg/d-NA	Inactive	Success
13 <sup>48</sup>	56/10/F	VKH		–	–	375 mg/m <sup>2</sup> × 4, at 0, 1, 6, 18 months	30 mg/d-NA	Inactive	Success
14 <sup>49</sup>	57/36/F	MS	IU	20/25 20/25	20/25 20/25	1000 mg × 2, 2-week apart, 3rd at 6 months	60–7.5 mg/d	Inactive	Success
	58/50/F	MS	IU	20/32 20/25	20/25 20/25	1000 mg × 2, 2-week apart, 3rd at 6 months	0–0 mg/d	Inactive	Success
	59/62/M	MS	IU	20/400 20/250	20/126 20/200	1000 mg × 2, 2-week apart, 3rd at 6 months	DNS-DNS	Inactive	Success
15 <sup>50</sup>	60/42/F	MS	AU	–	–	2000mg × 1, 1000 mg × 1.4-week apart, second cycle after 6 months	1 mg/kg/d-NA	Inactive	Success
16 <sup>51</sup>	61/50/M	MS	PAU	–	–	2000 mg × 2, 2-week apart	25 mg/d-NA	Active	Failure
17 <sup>52</sup>	62/62/F	MS, SS	IU	20/250 20/250	20/66 20/100	500 mg, 6-month apart	DNS-DNS		Success
18 <sup>53</sup>	63/59/F	GPA	–	–	–	2 doses of 1,000 mg (2 weeks apart) every 3–6 months	DNS-DNS	Inactive	Success
	64/56/F	GPA	–	0.3 0.3	0.1 0.4	375 mg/m <sup>2</sup> body surface area × 8 consecutive weeks, and monthly infusions thereafter	DNS-DNS	Inactive	Success



	65/72/F	GPA	–	0.3 0.1	2.0 0.1	2 doses of 1,000 mg (2 weeks apart) every 3–6 months	DNS-DNS	Inactive	Success
	66/54/M	GPA	–	0.3 0	0.4 –0.12	375 mg/m <sup>2</sup> body surface area × 4 consecutive weeks	DNS-DNS	Inactive	Success
	67/53/F	GPA	–	0.3 0.4	0 0.4	2 doses of 1,000 mg (2 weeks apart) every 3–6 months	DNS-DNS	Inactive	Success
19 <sup>54</sup>	68/39/F	AAV	PU	20/50 20/80	FC 20/1000	375 mg/m <sup>2</sup> body surface area × 4 consecutive weeks	DNS-DNS	Relapse	Failure
	69/54/M	AAV	PAU	20/20 20/25	20/20 20/25	2 doses of 1,000 mg (2 weeks apart) every 3–6 months	DNS-DNS	Inactive	Success
	70/56/F	AAV	PAU	20/20 20/20	20/25 20/20	375 mg/m <sup>2</sup> × 8 consecutive weeks, and monthly infusions thereafter	DNS-DNS	Inactive	Success
	71/60/F	AAV	PU	20/30 20/70	20/20 20/30	2 doses of 1,000 mg (2 weeks apart) every 3–6 months	DNS-DNS	Inactive	Success
	72/68/F	AAV	PU	20/20 20/25	20/25 20/25	2 doses of 1,000 mg (2 weeks apart) every 3–6 months	DNS-DNS	Inactive	Success
20 <sup>55</sup>	73/48/M	DUS	–	NLP CF	20/200 20/80	375 mg/m <sup>2</sup> × 8 consecutive weeks	20–0 mg/d	Inactive	Success
	74/14/F	DUS	–	20/20 20/200	20/20 20/200	375 mg/m <sup>2</sup> × 8 consecutive weeks	DNS-0 mg/d	Inactive	Success
21 <sup>56</sup>	75/40/M	Type II E	AU	20/80 20/70	20/20 20/20	795 mg × 4 consecutive weeks	60–5 mg/d	Inactive	Success
22 <sup>30</sup>	76/62/M	BSCR	AU+IU	6/15 6/12	6/17 6/16	1000 mg×2, 2-week apart	60–5 mg/d	Inactive	Success
23 <sup>57</sup>	77/49/F	EU	AU	20/200 20/60	20/60 20/30	375 mg/m <sup>2</sup> × 4 consecutive weeks	20–0 mg/d	Inactive	Success
24 <sup>58</sup>	78/33/F	SLE	PAU	1/60 CF	6/24 6/36	1000 mg×2, 2-week apart	15 mg/d-NA	Inactive	Success

**Abbreviations:** JIA, Juvenile Idiopathic Arthritis; RA, Rheumatoid Arthritis; BD, Behçet's Disease; VKH, Vogt-Koyanagi-Harada Disease; MS, Multiple Sclerosis; SS, Sjögren's Syndrome; GPA, Granulomatosis with Polyangiitis; AAV, ANCA-associated Vasculitis; DUS, Diffuse subretinal fibrosis uveitis; Type II E, Type II Essential; BSCR, birdshot chorioretinopathy; EU, Endogenous uveitis; SLE, Systemic Lupus Erythematosus; AU, Anterior Uveitis; IU, Intermediate Uveitis; PU, Posterior Uveitis; PAU, Panuveitis; NA, Not Available; DNS, Dose not specified.

Three main infusion protocols for RTX were identified: (a) the Rheumatologic protocol,<sup>59</sup> involving two doses of 1000 mg administered 14 days apart, followed by maintenance doses every 3 to 6 months; (b) the Oncologic protocol,<sup>60</sup> consisting of four weekly doses of 375 mg/m<sup>2</sup> of body surface area (BSA), with maintenance every 3 to 6 months; and (c) the Foster protocol,<sup>61</sup> involving eight weekly doses of 375 mg/m<sup>2</sup> BSA, followed by monthly maintenance doses. Of the 78 patients, 68.3% (54/78) adhered to the Rheumatologic protocol, 6.3% (5/78) followed the Oncologic protocol, and 3.8% (2/78) used the Foster protocol. Additional regimens were also reported, including: two doses of 375 mg/m<sup>2</sup> administered two weeks apart in 13.9% (11/78); two doses of 500 mg administered two weeks apart in 1.2% (1/78); three doses of 1000 mg at months 1, 6, and 18 in 1.2% (1/78); four doses of 375 mg/m<sup>2</sup> at months 0, 1, 6, and 18 in 1.2% (1/78); two doses of 2000 mg two weeks apart in 1.2% (1/78); one dose of 2000 mg followed by one dose of 1000 mg two weeks later in 1.2% (1/78); and 500 mg administered every 6 months in 1.2% (1/78).

## Clinical Efficacy of RTX

RTX therapy yielded positive outcomes, with 88.6% (69 out of 78) of patients demonstrating a favorable response. However, 11.4% (9 out of 78) discontinued treatment due to inadequate control of inflammation, infections, or other factors, as outlined in Table 3.<sup>35,36,38,39,41,51,54</sup> Visual acuity improvements were observed in 44.2% (23 out of 52) of patients post-treatment, while 30.8% (16 out of 52) exhibited no change, and 25% (13 out of 52) experienced a decline. In terms of ocular inflammation, 79.5% (62 out of 78) of patients achieved complete resolution, and 8.9% (7 out of 78) showed partial improvement. Moreover, corticosteroid dosage was reduced in 81.1% (20 out of 37) of patients following RTX therapy.

RTX was generally well-tolerated, with 10.3% (8 out of 78) of patients reporting adverse effects. Two patients experienced infusion-related reactions, including tremors and gastrointestinal discomfort during their initial administration.<sup>48,57</sup> Additionally, 7.5% (6 out of 78) developed infections, which included pneumonia (2 cases),<sup>41,51</sup> conjunctivitis (2 cases),<sup>41</sup> COVID-19 (1 case),<sup>52</sup> and a toenail fungal infection (1 case),<sup>55</sup> as summarized in Table 3.

**Table 3** Summary of Patients Experiencing Treatment Failure and Infection

Patient no./age at Entry, Years/Sex	Interval from Uveitis Diagnosis to RTX Treatment (Months)	Drugs used before RTX Treatment	RTX Treatment Schedule	Outcome	Adverse Events	Remark
5/32/F	48	MTX, CS, ETA, ADA, INFL	375 mg/m <sup>2</sup> , 2-week apart	Active	–	No 3 <sup>rd</sup> injection
9/24/F	168	MTX, CS, AZA, ADA	375 mg/m <sup>2</sup> , 2-week apart	Active	–	No 3 <sup>rd</sup> injection
10/15/F	48	MTX, CS, MMF, ETA, INFL, ADA	375 mg/m <sup>2</sup> , 2-week apart	Active	–	No 3 <sup>rd</sup> injection
13/-/-	132	MTX, CS, ETA, ADA, INFL	1000 mg × 2, 2-week apart, 3 <sup>rd</sup> at 12 or 21 months	Relapse At 8 <sup>th</sup> month	–	Relapse before 3 <sup>rd</sup> injection
27/12/M	120	MTX, IND, CS, ETA, INFL, ADA, ABA	500 mg/m <sup>2</sup> , 2-week apart	Relapse After 20 weeks	–	B-cell depletion not enough (> 4%)
30/26/F	168	LEF, AZA, CYC, MTX, IFN, ETA, INFL	1000 mg × 2, 2-week apart, 3 <sup>rd</sup> at 6 months	Eye enucleation	–	B-cell depletion not enough (> 3%)

(Continued)

Table 3 (Continued).

Patient no./age at Entry, Years/Sex	Interval from Uveitis Diagnosis to RTX Treatment (Months)	Drugs used before RTX Treatment	RTX Treatment Schedule	Outcome	Adverse Events	Remark
33/32/M	–	–	1000 mg × 2, 2-week apart	Active	–	Active before 3 <sup>rd</sup> injection
61/50/M	17	AZA, CS	2000 mg × 2, 2-week apart	RTX Discontinued	Pneumonia	IgG < 4 g/L, 4 months
68/39/F	–	MMF, RZB	375 mg/m <sup>2</sup> × 4 consecutive weeks	Relapse	–	–
32/17/M	–	–	1000 mg × 2, 2-week apart	Improved	Conjunctivitis	1 week after 1 <sup>st</sup> injection
34/24/M	–	–	1000 mg × 2, 2-week apart	Improved	Conjunctivitis	1 week after 1 <sup>st</sup> injection
35/28/M	–	–	1000 mg × 2, 2-week apart	Improved	Pneumonia	4 months after 1 <sup>st</sup> injection
56/10/F	40	MTX, IFN	375mg/m <sup>2</sup> × 4, at 0,1,6,18 months	Inactive	Quiver	First injection
62/62/F	12	MTX, LEF	500 mg, 6-month apart	Inactive	COVID-19 infections	–
73/48/M	7	TAC	375 mg/m <sup>2</sup> × 8 consecutive weeks	Inactive	Toenail fungal infection	1 year
77/49/F	36	MMF, CS, MTX, ETA	375 mg/m <sup>2</sup> × 4 consecutive weeks	Inactive	Gastrointestinal discomfort	First injection

**Abbreviations:** MTX, Methotrexate; CS, Cyclosporine; AZA, Azathioprine; MMF, Mycophenolate Mofetil; IND, Indomethacin; LEF, Leflunomide; IFN, Interferon; CYC, Cyclophosphamide; TAC, Tacrolimus; ETA, Etanercept; ADA, Adalimumab; INFL, Infliximab; ABA, Abatacept; RZB, Rituximab.

## Discussion

A systematic review was conducted to evaluate the efficacy of RTX in 78 patients with NIU. The analysis targeted patients who were either unresponsive or resistant to high-dose corticosteroids, conventional immunosuppressants, or biologic agents, positioning RTX as an alternative treatment. Clinical improvements following RTX therapy were evident through reduced inflammation, enhanced visual acuity, and decreased dependence on steroids. Notably, 88.5% of patients (69 out of 78) exhibited both clinical and laboratory improvements, with a particularly high response rate in those with VKH-associated uveitis (100%, 19 out of 19). While this significant response rate may be partially attributed to the small sample size, the rarity of NIU poses challenges for conducting large-scale randomized controlled trials. Despite the limited number of trials available, these findings underscore the potential benefit of early RTX intervention in managing NIU.

The prognosis of NIU is heavily influenced by the timing of diagnosis and initiation of treatment.<sup>62,63</sup> Without effective management, the disease can progress to chronic, relapsing uveitis, resulting in complications such as cystoid macular edema, vitreous haze, cataracts, glaucoma, and irreversible retinal damage.<sup>64,65</sup> Early pharmacologic intervention is essential for controlling inflammation and minimizing, or even preventing, vision-threatening complications.<sup>66</sup>

The primary therapeutic goals in NIU are to reduce inflammation, achieve disease remission, and thereby prevent ocular complications, permanent damage, and long-term visual impairment.<sup>67,68</sup> Standard treatment typically begins with topical, injectable, or oral corticosteroids, with escalation to steroid-sparing immunomodulatory therapy as necessary.<sup>10,69</sup>

Anterior uveitis is the most prevalent form of uveitis.<sup>1</sup> Studies have demonstrated the efficacy of methotrexate as an immunosuppressant and TNF- $\alpha$  inhibitors as biologics for treating anterior uveitis.<sup>11,17,70–72</sup> While RTX is considered a promising therapeutic option, its adoption has been limited by a lack of extensive supporting data rather than concerns regarding its efficacy or safety. This review highlights several cases in which RTX effectively treated anterior uveitis, providing a valuable reference for clinicians. Although specific biologics are preferred for certain types of uveitis, they are generally viewed as second- or third-line treatments in most patients.<sup>73</sup> TNF- $\alpha$  inhibitors remain the biologics of choice for NIU, with response rates for adalimumab, infliximab, and etanercept reported at 68.0%, 64.7%, and 65.2%, respectively.<sup>17</sup> In comparison, the present study demonstrated an 88.5% response rate with RTX across 78 patients.

Adalimumab, the first FDA-approved treatment for NIU,<sup>74,75</sup> is associated with a wide range of side effects, from 3% to 52%, encompassing both ocular and systemic complications. Infliximab's common adverse effects include uveitis recurrence and infusion reactions, with approximately two-thirds of patients experiencing infections, vitreous hemorrhage, and systemic infections. The most frequently reported adverse effect of etanercept is infection, which can sometimes lead to drug intolerance.<sup>17</sup> Moreover, several studies have confirmed that etanercept is not suitable for the treatment of non-infectious uveitis.<sup>76–79</sup>

In our review, 10.1% of patients (8 out of 78) experienced adverse reactions following RTX therapy. Two patients developed infusion-related reactions, while the remaining six (8.6%, 6 out of 78) experienced various infections. A similar infection rate was noted in the systematic review by Hernández-Rodríguez et al,<sup>80</sup> where 8.6% (3 out of 35) of patients treated with RTX for IgA vasculitis developed infections. However, Caleb C. Ng<sup>81</sup> reported a lower infection rate of 4.8% (4 out of 83) in patients with non-infectious scleritis treated with RTX, a finding lower than ours. In our review, five patients experienced mild infections (Nos. 32, 34, 35, 62, 73), whereas one patient (No. 61) developed a severe infection and discontinued RTX due to critically low IgG levels (< 4 g/L), which led to pneumonia. Nonetheless, studies in both pediatric and adult populations suggest that reduced immunoglobulin levels post-RTX do not necessarily correlate with an increased risk of infection,<sup>82–84</sup> indicating that individual factors, rather than RTX itself, may contribute to infection susceptibility. Although RTX depletes CD20-expressing B cells and may lower resistance to bacterial, viral, and fungal infections, it remains a relatively safe therapy with a low associated infection risk. However, this risk should still be considered.

Our retrospective evaluation of patients with poor responses to RTX treatment revealed several commonalities: (a) RTX was not administered early in the disease course of NIU; (b) treatment regimens were less aggressive than typical rheumatology protocols (two doses of 1,000 mg two weeks apart, repeated every 3–6 months); (c) post-treatment infections occurred. One patient (No. 68) lacked sufficient data to investigate the cause of inflammation recurrence, while another patient (No. 61) discontinued RTX due to a pulmonary infection. Additionally, five patients (Nos. 5, 9, 10, 13, 33) tested positive for uveitis following extended dosing intervals (>6 months). Two patients (Nos. 27 and 30) initially responded well to the first two doses of RTX but experienced a relapse as the depletion effect on CD20+ B cells diminished (>3%).

B cells serve a multitude of immune functions, including antibody and cytokine production, as well as antigen presentation through their B cell receptors.<sup>85</sup> By presenting autoantigens to pathogenic T cells, B cells facilitate autoimmunity, provide T cell help, produce pro-inflammatory cytokines, and form ectopic lymphoid follicles.<sup>86</sup> However, B cell depletion disrupts these immune processes, particularly the interaction between T and B cells, as observed in autoimmune conditions such as systemic lupus erythematosus and rheumatoid arthritis.<sup>19–21,87,88</sup> B cell depletion influences the activation, co-stimulation, and overall function of T lymphocytes. Early depletion of B cells is therefore critical in controlling inflammatory responses.

Additionally, disease relapses may be linked to the resurgence of CD20+ B cells, as highlighted in a study by Davatchi, which reported uveitis recurrence as B cell depletion waned.<sup>41</sup> A clear understanding of RTX pharmacodynamics and pharmacokinetics is essential: (a) RTX has a relatively long half-life of approximately three weeks, and (b) its administration rapidly depletes circulating CD20+ B cells.<sup>25,89,90</sup> The variability in B cell depletion and regeneration across individuals further complicates treatment.<sup>25,89</sup> Monitoring CD20+ B cells can therefore serve as an effective tool for optimizing the timing of subsequent RTX infusions. The reappearance of CD20+ B cells during treatment is a potential marker for increased relapse risk. Although RTX specifically targets CD20, fluctuations in CD19+ cells may offer additional insights into RTX's therapeutic effectiveness, as changes in CD19+ cell populations can indirectly

reflect the impact of RTX on B cells.<sup>25,91–93</sup> Thus, tracking CD19+ cell levels could provide useful information regarding the broader effects of RTX on B cell dynamics.

Lasave suggests that higher doses of RTX may be required for managing ocular inflammatory diseases, particularly in refractory cases, compared to standard rheumatologic protocols.<sup>94</sup> The relative isolation of the eye from systemic circulation, due to the blood-retinal and blood-vitreous barriers, complicates the delivery of systemic therapies to the eye. As a result, more aggressive treatment strategies aimed at maintaining consistently low levels of B cells may be necessary to achieve long-term, steroid-free remission and prevent relapse. Improving the safety and efficacy of RTX in NIU could therefore benefit from considering three key factors: (a) early initiation of RTX therapy after diagnosing NIU; (b) maintaining low levels of circulating B cells between RTX doses; and (c) evaluating the patient's infection risk profile.

In this review, RTX was administered an average of 4.13 years after NIU diagnosis, following the failure or resistance to high-dose corticosteroids and other immunotherapies. By this point, many patients may have already developed vision-threatening complications such as cataracts, glaucoma, or macular edema. Consequently, the delayed use of RTX may limit the potential for full vision restoration. Additionally, the regeneration of B cells during prolonged intervals between doses could increase the likelihood of relapse. Thus, the reported response rate of 88.5% might underestimate RTX's true efficacy in NIU due to the inherent limitations in timing and patient selection. Future research should focus on personalized RTX regimens that maintain lower levels of CD20+ B cells to further improve outcomes.

## Conclusion

In conclusion, managing NIU remains challenging, particularly in balancing treatment efficacy with safety concerns. Based on current evidence, RTX appears to be a viable and effective option for cases unresponsive to high-dose steroids and multiple immunotherapies. Given the variability in patient responses, it is crucial to personalize treatment protocols to address individual needs.

The key insights from this review are as follows: (a) RTX shows promise as a safe and effective therapy for NIU; (b) early initiation of RTX after NIU diagnosis, coupled with regular monitoring of B-cell counts during treatment intervals, may help maintain low B-cell levels and improve outcomes; and (c) further prospective clinical trials are necessary to establish the optimal RTX treatment regimen for NIU.

## Acknowledgments

We thank Bullet Edits Limited for the linguistic editing and proofreading of the manuscript.

## Funding

This research was funded by financial support from the National Natural Science Foundation of China, awarded to Xiang Ma, under grant number 81271022.

## Disclosure

The authors report no conflicts of interest in this work.

## References

1. Rosenbaum JT, Bodaghi B, Couto C, et al. New observations and emerging ideas in diagnosis and management of non-infectious uveitis: a review. *Semin Arthritis Rheum.* 2019;49(3):438–445. doi:10.1016/j.semarthrit.2019.06.004
2. Touhami S, Diwo E, Seve P, et al. Expert opinion on the use of biological therapy in non-infectious uveitis. *Expert Opin Biol Ther.* 2019;19(5):477–490. doi:10.1080/14712598.2019.1595578
3. Rosenbaum JT, Dick AD. The eyes have it: a rheumatologist's view of uveitis. *Arthritis Rheumatol.* 2018;70(10):1533–1543. doi:10.1002/art.40568
4. Bermejo I, Squires H, Poku EN, et al. Adalimumab for non-infectious uveitis: is it cost-effective? *Br J Ophthalmol.* 2019;103(11):1633–1638. doi:10.1136/bjophthalmol-2018-312756
5. Airody A, Heath G, Lightman S, Gale R. Non-infectious uveitis: optimising the therapeutic response. *Drugs.* 2016;76(1):27–39. doi:10.1007/s40265-015-0502-y
6. Dana MR, Merayo-Llodes J, Schaumberg DA, Foster CS. Prognosticators for visual outcome in sarcoid uveitis. *Ophthalmology.* 1996;103(11):1846–1853. doi:10.1016/S0161-6420(96)30417-X
7. Vegas-Revenga N, Martin-Varillas JL, Calvo-Rio V, et al. Intravenous methylprednisolone induces rapid improvement in non-infectious uveitis: a multicentre study of 112 patients. *Clin Exp Rheumatol.* 2022;40(1):142–149. doi:10.55563/clinexprheumatol/imrgo2

8. Dibas A, Yorio T. Glucocorticoid therapy and ocular hypertension. *Eur J Pharmacol.* 2016;787:57–71. doi:10.1016/j.ejphar.2016.06.018
9. Yorio T, Patel GC, Clark AF. Glucocorticoid-induced ocular hypertension: origins and new approaches to minimize. *Expert Rev Ophthalmol.* 2020;15(3):145–157. doi:10.1080/17469899.2020.1762488
10. Reddy A, Liu SH, Brady CJ, Sieving PC, Palestine AG. Corticosteroid implants for chronic non-infectious uveitis. *Cochrane Database Syst Rev.* 2023;1(1):CD010469. doi:10.1002/14651858.CD010469.pub3
11. Angeles-Han ST, Lo MS, Henderson LA, et al. Childhood arthritis and rheumatology research alliance consensus treatment plans for juvenile idiopathic arthritis-associated and idiopathic chronic anterior uveitis. *Arthritis Care Res.* 2019;71(4):482–491. doi:10.1002/acr.23610
12. Charkoudian LD, Ying GS, Pujari SS, et al. High-dose intravenous corticosteroids for ocular inflammatory diseases. *Ocul Immunol Inflamm.* 2012;20(2):91–99. doi:10.3109/09273948.2011.646382
13. van Laar JAM, Rothova A, Missotten T, Kuijpers R, van Hagen PM, van Velthoven MEJ. Diagnosis and treatment of uveitis; not restricted to the ophthalmologist. *J Clin Trans Res.* 2015;1(2):94–99.
14. Vallet H, Seve P, Biard L, et al. Infliximab versus adalimumab in the treatment of refractory inflammatory uveitis: a multicenter study from the French uveitis network. *Arthritis Rheumatol.* 2016;68(6):1522–1530. doi:10.1002/art.39667
15. Interlandi E, Leccese P, Olivieri I, Latanza L. Adalimumab for treatment of severe Behcet's uveitis: a retrospective long-term follow-up study. *Clin Exp Rheumatol.* 2014;32(4 Suppl 84):S58–62.
16. Nguyen QD, Merrill PT, Jaffe GJ, et al. Adalimumab for prevention of uveitic flare in patients with inactive non-infectious uveitis controlled by corticosteroids (VISUAL II): a multicentre, double-masked, randomised, placebo-controlled Phase 3 trial. *Lancet.* 2016;388(10050):1183–1192. doi:10.1016/S0140-6736(16)31339-3
17. Jari M, Shiari R, Salehpour O, Rahmani K. Epidemiological and advanced therapeutic approaches to treatment of uveitis in pediatric rheumatic diseases: a systematic review and meta-analysis. *Orphanet J Rare Dis.* 2020;15(1):41. doi:10.1186/s13023-020-1324-x
18. Calvo-Río V, Santos-Gómez M, Calvo I, et al. Anti-interleukin-6 receptor tocilizumab for severe juvenile idiopathic arthritis-associated uveitis refractory to anti-tumor necrosis factor therapy: a multicenter study of twenty-five patients. *Arthritis Rheumatol.* 2017;69(3):668–675. doi:10.1002/art.39940
19. Franks SE, Getahun A, Hogarth PM, Cambier JC. Targeting B cells in treatment of autoimmunity. *Curr Opin Immunol.* 2016;43:39–45. doi:10.1016/j.coi.2016.09.003
20. Hofmann K, Clauser AK, Manz RA. Targeting B cells and plasma cells in autoimmune diseases. *Front Immunol.* 2018;9:835. doi:10.3389/fimmu.2018.00835
21. Musette P, Bouaziz JD. B cell modulation strategies in autoimmune diseases: new concepts. *Front Immunol.* 2018;9:622. doi:10.3389/fimmu.2018.00622
22. Marino M, Bartocconi E, Alboini PE, Evoli A. Rituximab in myasthenia gravis: a “to be or not to be” inhibitor of T cell function. *Ann N Y Acad Sci.* 2018;1413(1):41–48. doi:10.1111/nyas.13562
23. Carubbi F, Alunno A, Cipriani P, et al. Rituximab in primary Sjogren's syndrome: a ten-year journey. *Lupus.* 2014;23(13):1337–1349. doi:10.1177/0961203314546023
24. Abu El-Asrar AM, Van Damme J, Struyf S, Opdenakker G. New perspectives on the immunopathogenesis and treatment of uveitis associated with Vogt-Koyanagi-Harada disease. *Front Med Lausanne.* 2021;8:705796. doi:10.3389/fmed.2021.705796
25. Bergantini L, d'Alessandro M, Cameli P, et al. Effects of rituximab therapy on B cell differentiation and depletion. *Clin Rheumatol.* 2020;39(5):1415–1421. doi:10.1007/s10067-020-04996-7
26. Batchelor TT, Grossman SA, Mikkelsen T, Ye X, Desideri S, Lesser GJ. Rituximab monotherapy for patients with recurrent primary CNS lymphoma. *Neurology.* 2011;76(10):929–930. doi:10.1212/WNL.0b013e31820f2d94
27. Vital EM, Dass S, Rawstron AC, et al. Management of nonresponse to rituximab in rheumatoid arthritis: predictors and outcome of re-treatment. *Arthritis Rheum.* 2010;62(5):1273–1279. doi:10.1002/art.27359
28. Cervera R, Mosca M, Rios-Garcés R, et al. Treatment for refractory lupus nephritis: rituximab vs triple target therapy. *Autoimmun Rev.* 2019;18(12):102406. doi:10.1016/j.autrev.2019.102406
29. Gottenberg JE, Guillevin L, Lambotte O, et al. Tolerance and short term efficacy of rituximab in 43 patients with systemic autoimmune diseases. *Ann Rheum Dis.* 2005;64(6):913–920. doi:10.1136/ard.2004.029694
30. Tomkins-Netzer O, Taylor SR, Lightman S. Can rituximab induce long-term disease remission in patients with intra-ocular non-infectious inflammation? *Ophthalmologica.* 2013;230(3):109–115. doi:10.1159/000351426
31. Deschenes J, Murray PI, Rao NA, Nussenblatt RB. International uveitis study G. International uveitis study group (IUSG): clinical classification of uveitis. *Ocul Immunol Inflamm.* 2008;16(1):1–2. doi:10.1080/09273940801899822
32. Jabs DA, Nussenblatt RB, Rosenbaum JT. Standardization of uveitis nomenclature working G. Standardization of uveitis nomenclature for reporting clinical data. Results of the first international workshop. *Am J Ophthalmol.* 2005;140(3):509–516.
33. Becker MD, Smith JR, Max R, Fiehn C. Management of sight-threatening uveitis: new therapeutic options. *Drugs.* 2005;65(4):497–519. doi:10.2165/00003495-200565040-00005
34. Park JY, Chung YR, Lee K, Song JH, Lee ES. Clinical experience of interferon Alfa-2a treatment for refractory uveitis in Behcet's disease. *Yonsei Med J.* 2015;56(4):1158–1162. doi:10.3349/ymj.2015.56.4.1158
35. Heiligenhaus A, Miserocchi E, Heinz C, Gerloni V, Kotaniemi K. Treatment of severe uveitis associated with juvenile idiopathic arthritis with anti-CD20 monoclonal antibody (rituximab). *Rheumatology.* 2011;50(8):1390–1394. doi:10.1093/rheumatology/ker107
36. Miserocchi E, Pontikaki I, Modorati G, Gattinara M, Meroni PL, Gerloni V. Anti-CD 20 monoclonal antibody (rituximab) treatment for inflammatory ocular diseases. *Autoimmun Rev.* 2011;11(1):35–39. doi:10.1016/j.autrev.2011.07.001
37. Vegas-Revenga N, Calvo-Río V, Santos-Gómez M, et al. Short and long-term follow-up of tocilizumab for severe juvenile idiopathic arthritis-associated uveitis. *Ann Rheumatic Dis.* 2017;76:405–406.
38. Tsang AC, Roth J, Gottlieb C. Tocilizumab for severe chronic anterior uveitis associated with juvenile idiopathic arthritis in a pediatric patient. *Ocul Immunol Inflamm.* 2014;22(2):155–157. doi:10.3109/09273948.2013.866254
39. Pelegrin L, Jakob E, Schmidt-Bacher A, et al. Experiences with rituximab for the treatment of autoimmune diseases with ocular involvement. *J Rheumatol.* 2014;41(1):84–90. doi:10.3899/jrheum.130206



40. Miserocchi E, Modorati G, Berchicci L, Pontikaki I, Meroni P, Gerloni V. Long-term treatment with rituximab in severe juvenile idiopathic arthritis-associated uveitis. *Br J Ophthalmol*. 2016;100(6):782–786. doi:10.1136/bjophthalmol-2015-306790
41. Davatchi F, Shams H, Rezaipoor M, et al. Rituximab in intractable ocular lesions of Behcet's disease; randomized single-blind control study (pilot study). *Int J Rheum Dis*. 2010;13(3):246–252. doi:10.1111/j.1756-185X.2010.01546.x
42. Sadreddini S, Noshad H, Molaeefard M, Noshad R. Treatment of retinal vasculitis in Behcet's disease with rituximab. *Mod Rheumatol*. 2008;18(3):306–308. doi:10.3109/s10165-008-0057-9
43. Abu El-Asrar AM, Dheyab A, Khatib D, Struyf S, Van Damme J, Opendakker G. Efficacy of B cell depletion therapy with rituximab in refractory chronic recurrent uveitis associated with Vogt-Koyanagi-Harada disease. *Ocul Immunol Inflamm*. 2022;30(3):750–757. doi:10.1080/09273948.2020.1820531
44. Bolletta E, Gozzi F, Mastrofilippo V, et al. Efficacy of rituximab treatment in Vogt-Koyanagi-Harada disease poorly controlled by traditional immunosuppressive treatment. *Ocul Immunol Inflamm*. 2022;30(6):1303–1308. doi:10.1080/09273948.2021.1880604
45. Tobaigy MF, AlBloushi AF, Al-Dhibi HA. Reversal of peripheral iris depigmentation associated with Vogt-Koyanagi-Harada disease. *Ocul Immunol Inflamm*. 2024;32(4):424–428. doi:10.1080/09273948.2022.2161917
46. Dolz-Marco R, Gallego-Pinazo R, Diaz-Llopis M. Rituximab in refractory Vogt-Koyanagi-Harada disease. *J Ophthalmic Inflamm Infect*. 2011;1(4):177–180. doi:10.1007/s12348-011-0027-9
47. Caso F, Rigante D, Vitale A, et al. Long-lasting uveitis remission and hearing loss recovery after rituximab in Vogt-Koyanagi-Harada disease. *Clin Rheumatol*. 2015;34(10):1817–1820. doi:10.1007/s10067-014-2781-1
48. Umrhan RMR, Shukur ZYH. Rituximab for sight-threatening refractory pediatric Vogt-Koyanagi-Harada disease. *Mod Rheumatol*. 2018;28(1):197–199. doi:10.3109/14397595.2015.1071234
49. Stascheit F, Rubsam A, Otto C, Meisel A, Ruprecht K, Pleyer U. Anti-CD20 therapy for multiple sclerosis-associated uveitis: a case series. *Eur J Neurol*. 2022;29(10):3028–3038. doi:10.1111/ene.15453
50. Babu K, Murthy GJ, Murthy KR. Uveitis, retinal vasculitis, and loss of accommodation as sole manifestations of demyelinating disease: a case report. *Indian J Ophthalmol*. 2020;68(9):2007–2009. doi:10.4103/ijo.IJO\_2017\_19
51. Lopalco G, Schiraldi S, Venerito V, Guerriero S, Iannone F. Effectiveness and safety profile of anakinra in a HLA-B27 positive patient with multiple sclerosis-associated uveitis. *Mult Scler Relat Disord*. 2020;42:102152. doi:10.1016/j.msard.2020.102152
52. Gnanaraj R, Shah AA, Palestine AG, Reddy AK. Uveitis in the setting of co-existing systemic sarcoidosis and multiple sclerosis. *Ocul Immunol Inflamm*. 2024;32(2):181–183. doi:10.1080/09273948.2023.2236211
53. Ahmed A, Foster CS. Cyclophosphamide or rituximab treatment of scleritis and uveitis for patients with granulomatosis with polyangiitis. *Ophthalmic Res*. 2019;61(1):44–50. doi:10.1159/000486791
54. Lin M, Anesi SD, Ma L, Ahmed A, Small K, Foster CS. Characteristics and visual outcome of refractory retinal vasculitis associated with antineutrophil cytoplasm antibody-associated vasculitides. *Am J Ophthalmol*. 2018;187:21–33. doi:10.1016/j.ajo.2017.12.004
55. Cornish KS, Kuffova L, Forrester JV. Treatment of diffuse subretinal fibrosis uveitis with rituximab. *Br J Ophthalmol*. 2015;99(2):153–154. doi:10.1136/bjophthalmol-2013-304686
56. Nicholson L, Sobrin L. Anterior uveitis secondary to type II essential cryoglobulinemia. *J Ophthalmic Inflamm Infect*. 2013;3(1):56. doi:10.1186/1869-5760-3-56
57. Tappeiner C, Heinz C, Specker C, Heiligenhaus A. Rituximab as a treatment option for refractory endogenous anterior uveitis. *Ophthalmic Res*. 2007;39(3):184–186. doi:10.1159/000103239
58. Hickman RA, Denniston AK, Yee CS, Toescu V, Murray PI, Gordon C. Bilateral retinal vasculitis in a patient with systemic lupus erythematosus and its remission with rituximab therapy. *Lupus*. 2010;19(3):327–329. doi:10.1177/0961203309347332
59. Cheung CM, Murray PI, Savage CO. Successful treatment of Wegener's granulomatosis associated scleritis with rituximab. *Br j Ophthalmol*. 2005;89(11):1542. doi:10.1136/bjo.2005.075689
60. Ahmadi-Simab K, Lamprecht P, Nolle B, Ai M, Gross WL. Successful treatment of refractory anterior scleritis in primary Sjogren's syndrome with rituximab. *Ann Rheum Dis*. 2005;64(7):1087–1088. doi:10.1136/ard.2004.027128
61. Foster CS, Chang PY, Ahmed AR. Combination of rituximab and intravenous immunoglobulin for recalcitrant ocular cicatricial pemphigoid: a preliminary report. *Ophthalmology*. 2010;117(5):861–869. doi:10.1016/j.ophtha.2009.09.049
62. Fox A, Jeffrey B, Hasni S, Nussenblatt R, Sen HN. Rituximab treatment for nonparaneoplastic autoimmune retinopathy. *Can J Ophthalmol*. 2015;50(6):e101–104. doi:10.1016/j.jcjo.2015.08.009
63. Sharma SM, Dick AD, Ramanan AV. Non-infectious pediatric uveitis: an update on immunomodulatory management. *Paediatr Drugs*. 2009;11(4):229–241. doi:10.2165/00148581-200911040-00002
64. Teabagay S, Wood E, Bilsbury E, Doherty S, Janardhana P, Lee DJ. Ocular immunosuppressive microenvironment and novel drug delivery for control of uveitis. *Adv Drug Deliv Rev*. 2023;198:114869. doi:10.1016/j.addr.2023.114869
65. Huang XF, Brown MA. Progress in the genetics of uveitis. *Genes Immun*. 2022;23(2):57–65. doi:10.1038/s41435-022-00168-6
66. Burkholder BM, Jabs DA. Uveitis for the non-ophthalmologist. *BMJ*. 2021;372:m4979.
67. Nguyen QD, Callanan D, Dugel P, Godfrey DG, Goldstein DA, Wilensky JT Treating chronic noninfectious posterior segment uveitis: the impact of cumulative damage: proceedings of an expert panel roundtable discussion. *Retina*. 2006;26:1–16.
68. Nguyen QD, Hatfield E, Kayen B, et al. A cross-sectional study of the current treatment patterns in noninfectious uveitis among specialists in the United States. *Ophthalmology*. 2011;118(1):184–190. doi:10.1016/j.ophtha.2010.03.029
69. Jabs DA. Immunosuppression for the uveitides. *Ophthalmology*. 2018;125(2):193–202. doi:10.1016/j.ophtha.2017.08.007
70. Wakefield D, Clarke D, McCluskey P. Recent developments in HLA B27 anterior uveitis. *Front Immunol*. 2020;11:608134. doi:10.3389/fimmu.2020.608134
71. Foeldvari I, Maccora I, Petruschkin H, et al. New and updated recommendations for the treatment of juvenile idiopathic arthritis-associated uveitis and idiopathic chronic anterior uveitis. *Arthritis Care Res*. 2023;75(5):975–982. doi:10.1002/acr.24963
72. Ramanan AV, Dick AD, Jones AP, et al. Adalimumab plus methotrexate for uveitis in juvenile idiopathic arthritis. *N Engl J Med*. 2017;376(17):1637–1646. doi:10.1056/NEJMoa1614160
73. Thomas AS. Biologics for the treatment of noninfectious uveitis: current concepts and emerging therapeutics. *Curr Opin Ophthalmol*. 2019;30(3):138–150. doi:10.1097/ICU.0000000000000562

74. LaMattina KC, Goldstein DA. Adalimumab for the treatment of uveitis. *Expert Rev Clin Immunol*. 2017;13(3):181–188. doi:10.1080/1744666X.2017.1288097
75. Gaggiano C, Sota J, Gentileschi S, et al. The current status of biological treatment for uveitis. *Expert Rev Clin Immunol*. 2020;16(8):787–811. doi:10.1080/1744666X.2020.1798230
76. Hashkes PJ, Shajrawi I. Sarcoid-related uveitis occurring during etanercept therapy. *Clin Exp Rheumatol*. 2003;21(5):645–646.
77. Suzuki J, Goto H. Uveitis associated with sarcoidosis exacerbated by etanercept therapy. *Jpn J Ophthalmol*. 2009;53(4):439–440. doi:10.1007/s10384-009-0691-6
78. Cordero-Coma M, Yilmaz T, Onal S. Systematic review of anti-tumor necrosis factor- $\alpha$  therapy for treatment of immune-mediated uveitis. *Ocul Immunol Inflamm*. 2013;21(1):19–27. doi:10.3109/09273948.2012.723107
79. Levy-Clarke G, Jabs DA, Read RW, Rosenbaum JT, Vitale A, Van Gelder RN. Expert panel recommendations for the use of anti-tumor necrosis factor biologic agents in patients with ocular inflammatory disorders. *Ophthalmology*. 2014;121(3):785–796.e783. doi:10.1016/j.ophtha.2013.09.048
80. Hernandez-Rodriguez J, Carbonell C, Miron-Canelo JA, Diez-Ruiz S, Marcos M, Chamorro AJ. Rituximab treatment for IgA vasculitis: a systematic review. *Autoimmun Rev*. 2020;19(4):102490. doi:10.1016/j.autrev.2020.102490
81. Ng CC, Sy A, Cunningham ET Jr. Rituximab for non-infectious uveitis and scleritis. *J Ophthalmic Inflamm Infect*. 2021;11(1):23. doi:10.1186/s12348-021-00252-4
82. Popa C, Leandro MJ, Cambridge G, Edwards JC. Repeated B lymphocyte depletion with rituximab in rheumatoid arthritis over 7 yrs. *Rheumatology*. 2007;46(4):626–630. doi:10.1093/rheumatology/ke1393
83. Specks U, Merkel PA, Seo P, et al. Efficacy of remission-induction regimens for ANCA-associated vasculitis. *N Engl J Med*. 2013;369(5):417–427. doi:10.1056/NEJMoa1213277
84. Rashid AN-S, Bergkamp SC, Kampinga RE, et al. Pharmacodynamics of rituximab in paediatric immune mediated diseases: b cell depletion and repopulation, effects on immunoglobulin levels and risk for infections. *Clin Exp Rheumatol*. 2023;41(11):2323–2330. doi:10.55563/clinexprheumatol/yqjz1s
85. Vallerskog T, Gunnarsson I, Widhe M, et al. Treatment with rituximab affects both the cellular and the humoral arm of the immune system in patients with SLE. *Clin Immunol*. 2007;122(1):62–74. doi:10.1016/j.clim.2006.08.016
86. Vigna-Perez M, Hernandez-Castro B, Paredes-Saharopulos O, et al. Clinical and immunological effects of rituximab in patients with lupus nephritis refractory to conventional therapy: a pilot study. *Arthritis Res Ther*. 2006;8(3):R83. doi:10.1186/ar1954
87. Gunnarsson I, Sundelin B, Jonsdottir T, Jacobson SH, Henriksson EW, van Vollenhoven RF. Histopathologic and clinical outcome of rituximab treatment in patients with cyclophosphamide-resistant proliferative lupus nephritis. *Arthritis Rheum*. 2007;56(4):1263–1272. doi:10.1002/art.22505
88. Sfrikakis PP, Boletis JN, Lionaki S, et al. Remission of proliferative lupus nephritis following B cell depletion therapy is preceded by down-regulation of the T cell costimulatory molecule CD40 ligand: an open-label trial. *Arthritis Rheum*. 2005;52(2):501–513. doi:10.1002/art.20858
89. Christou EAA, Giardino G, Worth A, Ladomenou F. Risk factors predisposing to the development of hypogammaglobulinemia and infections post-rituximab. *Int Rev Immunol*. 2017;36(6):352–359. doi:10.1080/08830185.2017.1346092
90. Golay J, Semenzato G, Rambaldi A, et al. Lessons for the clinic from rituximab pharmacokinetics and pharmacodynamics. *MAbs*. 2013;5(6):826–837. doi:10.4161/mabs.26008
91. Du Y, Li C, Hao YF, et al. Individualized regimen of low-dose rituximab monotherapy for new-onset AChR-positive generalized myasthenia gravis. *J Neurol*. 2022;269(8):4229–4240. doi:10.1007/s00415-022-11048-4
92. Jones JD, Hamilton BJ, Rigby WF. Rituximab mediates loss of CD19 on B cells in the absence of cell death. *Arthritis Rheum*. 2012;64(10):3111–3118. doi:10.1002/art.34560
93. Levy R, Mahevas M, Galicier L, et al. Profound symptomatic hypogammaglobulinemia: a rare late complication after rituximab treatment for immune thrombocytopenia. Report of 3 cases and systematic review of the literature. *Autoimmun Rev*. 2014;13(10):1055–1063. doi:10.1016/j.autrev.2014.08.036
94. Lasave AF, You C, Ma L, et al. Long-term outcomes of rituximab therapy in patients with noninfectious posterior uveitis refractory to conventional immunosuppressive therapy. *Retina*. 2018;38(2):395–402. doi:10.1097/IAE.0000000000001563

## Journal of Inflammation Research

Dovepress

## Publish your work in this journal

The Journal of Inflammation Research is an international, peer-reviewed open-access journal that welcomes laboratory and clinical findings on the molecular basis, cell biology and pharmacology of inflammation including original research, reviews, symposium reports, hypothesis formation and commentaries on: acute/chronic inflammation; mediators of inflammation; cellular processes; molecular mechanisms; pharmacology and novel anti-inflammatory drugs; clinical conditions involving inflammation. The manuscript management system is completely online and includes a very quick and fair peer-review system. Visit <http://www.dovepress.com/testimonials.php> to read real quotes from published authors.

Submit your manuscript here: <https://www.dovepress.com/journal-of-inflammation-research-journal>