

Two-Year Retrospective Study of Cataract Surgery and Schlemm Canal Hydrus Microstent in Black and Afro-Latino Patients

Daniel Laroche^{1,2,*}, Ayobami Adebayo^{3,*}, Chester Ng^{2,*}

¹Department of Ophthalmology, Icahn School of Medicine at Mount Sinai and New York Eye and Ear Infirmary of Mount Sinai, New York, NY, USA;

²Advanced Eyecare of New York, New York, NY, USA; ³Albert Einstein College of Medicine, Bronx, NY, USA

*These authors contributed equally to this work

Correspondence: Daniel Laroche, Advanced Eyecare of New York, 49 West 127th Street, New York, NY, 10027, USA, Email dlarochemd@aol.com

Background: The Hydrus Microstent has been shown to be efficacious in the treatment of Open-angle Glaucoma. We previously reported 1-year results of the Hydrus Microstent in Black and Afro-Latino patients.

Objective: Here we report two-year results of the Hydrus Microstent in Black and Afro-Latino patients with mild to moderate open-angle glaucoma.

Design: This was a retrospective, nonrandomized study that was carried out at two private practices in Harlem, NY and Queens, NY.

Methods: This study consisted of Black and Afro Latino patients who had a Hydrus Microstent implanted for the treatment of glaucoma. The evaluated parameters were intraocular pressure (IOP), reductions in the number of medications, mean deviation on visual field test and visual acuity. We excluded persons with advanced glaucoma and incomplete data. We included those with mild to moderate glaucoma and had complete two-year follow-up data.

Results: The study consisted of 86 patients and 86 eyes. The mean age was 69. The mean pre-op IOP was 14.1 on 2.17 medications. At two years the mean IOP was 14 ($p = 0.651$) on 0.42 medications ($p = 0.000003$); 88% of patients were medication free ($p = 0.651$). The MD on the visual field changed little from -5.73 preoperatively to -5.21 at two years. There were 3 intraocular pressure spikes and 1 case of hyphema that were treated and had complete resolution. No patients required secondary surgery.

Conclusion: Our results show that at two years the Hydrus Microstent can maintain low intraocular pressures, reduce medication burden and, in aggregate, experienced little change in visual field Mean Deviation in Black and Afro Latino patients with mild to moderate glaucoma.

Keywords: hydrus, microstent, glaucoma, Afro-Latino, cataract

Introduction

Glaucoma is a progressive optic neuropathy characterized by the loss of retinal ganglion cells and visual field loss usually associated with elevated eye pressure.¹ Glaucoma is also a significant contributor to global blindness and its treatment often involves the use of a combination of medicinal and surgical approaches.¹ A reduction in intraocular pressure by way of surgery or medication has been the mainstay of treatment for many years.² African Americans are three to four times more likely to be diagnosed with glaucoma when compared to Caucasians³ with primary open-angle glaucoma (POAG) being the most common cause of permanent blindness in African Americans. African Americans are less responsive to both medicinal and surgical interventions for primary open-angle glaucoma (POAG) in comparison to other ethnic groups⁴ and this phenomenon is further aggravated by socioeconomic disparities, which contribute to the restricted availability of health-care services.³

Earlier cataract surgery and microinvasive glaucoma surgery (MIGS) have shown excellent efficacy and safety in lowering intraocular pressure in patients with mild to moderate glaucoma. The enlarging lens in the eye is one of the

most identifiable causes of glaucoma.^{5,6} The aging process leads to an augmentation in both the volume and breadth of the lens, resulting in the compression of the trabecular meshwork (TM).⁷ Moreover, the enlarged lens volume enhances the interaction between the lens zonules and the posterior pigment epithelium. This interaction is intensified during accommodation due to the iris's posterior curvature and the lens's expanded breadth.¹ Augmented iridolenticular contact results in the release of pigment, which hinders the functioning of the trabecular meshwork. In adults, the expansion of Schlemm's canal and the subsequent drop in intraocular pressure (IOP) are directly proportional to the degree of expansion after cataract extraction or lensectomy.⁸

The 5-year data from the HORIZON trial has shown that Hydrus Microstent (Alcon Vision, LLC; Fort Worth, TX, USA) implantation with cataract surgery is safe, and results in lower intraocular pressure (IOP) and medication use, and shows a decreased need for secondary glaucoma filtration surgery compared to cataract surgery, alone.⁹ There are large health-care disparities globally with POAG in minority groups.¹⁰ Patients of African descent are disproportionately affected by POAG as it develops earlier, presents more severely, and progresses more rapidly.^{4,11–13} Black patients often have reduced accessibility to treatment and are oftentimes unaware of the risks of POAG.⁴ Prevalence increases with age and is higher in Black and Hispanic populations, and treatment costs are directly related to the severity of disease and the number of medications/treatments used.¹⁴ Despite the higher disease burden, racial/ethnic minority groups have a significantly lower participation rate in clinical trials for POAG than those of Caucasian descent.¹⁰ The enlarging lens, coupled with decreased access to cataract surgery and microinvasive glaucoma surgery contribute to this.³

There are sparse data on long-term, real-world outcomes for the Hydrus Microstent in a high-risk African American/Afro-Latino patient population. We previously reported 1-year results regarding the efficacy of the Hydrus Microstent in Black and Afro-Latino patients.¹⁵ There have been multiple clinical trials with a follow-up period of two years that demonstrated the efficacy of the Hydrus Microstent. However, the efficacy of the Hydrus Microstent has not yet been investigated in patients of African and Afro-Latino heritage with a follow-up period of at least two years. Here in this study, we report the efficacy of the Hydrus Microstent in a Black and Afro-Latino population with mild to moderate glaucoma with a follow-up period of two years. The ethnic makeup of the patients in this study is indicative of the groups found in Southeast Queens and Harlem in New York City.

Methods

This was a retrospective study that was carried out at two practices in Harlem, NY and Queens, NY. The study was approved by the Institutional Review Board at the New York Eye and Ear Infirmary of Mount Sinai, New York, USA (IRB- STUDY-20-0006-MODCR001); in addition, the study adhered to the tenets of the Declaration of Helsinki, all HIPPA regulations were followed, and a waiver of informed consent was obtained. We reviewed 156 number of patients who underwent cataract extraction and Hydrus Microstent. Out of 156 patients we identified 86 with mild to moderate open-angle glaucoma and complete two-year follow-up data. This study included 86 patients of African American and Afro – Latino descent that have been diagnosed with Primary Open-Angle Glaucoma. Cataract surgery with Hydrus Microstent implantation was used in these patients to reduce intraocular pressure and decrease the number of medications used. The ethnicity of the study participants reflected the ethnic composition of the surrounding local communities. Our inclusion criteria consisted of patients with mild to moderate primary open-angle glaucoma who had undergone uncomplicated cataract surgery and Hydrus Microstent implantation with 2-year follow-up data from the date of surgery. We collected the preoperative visual field (VF) data and again at 2 years. Patients who had severe POAG, angle closure, neovascular glaucoma, or uveitis were excluded from the study because they did not satisfy the inclusion criteria.

The primary metric of interest was a reduction in ocular hypotensive medications at 2 years after surgery. Our secondary metrics of interest included a comparison of clinically measured IOP pre and post Hydrus Microstent implantation at 2 years after surgery in patients with mild to moderate glaucoma. We examined the change in VF for patients following cataract surgery with Hydrus implantation comparing Humphrey 24–2 visual field mean deviation (MD) from baseline to 2 years after surgery. BCVA was compared at 2 years. Finally, the incidence of secondary surgical intervention (SSI) at 2 years was also determined.

As part of the safety evaluation, we looked at the adverse events reported from the initial phase of surgery through the final follow-up. Before beginning the procedure, both the patient's medical and surgical history were reviewed. On the day of the procedure, all medications that reduce intraocular pressure were discontinued. After surgery, each patient was given one drop of Ofloxacin Ophthalmic Solution USP, 0.3% (Akorn, Inc. Lake Forest, IL, USA), every 6 hours, one drop of Ketorolac Tromethamine ophthalmic solution, 0.5% (Sandoz Inc. Princeton, NJ, USA) every 6 hours, and one drop of prednisolone acetate Ophthalmic Suspension, USP, 1% (Sandoz Inc. Princeton, NJ, USA) every six hours. Post operatively all glaucoma medications were stopped in the operated eye and continued in the other eye as needed. Glaucoma medications were then prescribed to patients or stopped being prescribed depending on medical assessment and individualized intraocular pressure (IOP) reduction goals were set for each patient. The clinical follow-up was examined on day one, six months after, one year after and two years after the first evaluation. We only included patients with mild to moderate glaucoma. Patients with advanced glaucoma were excluded. Patients lost to follow-up while excluded. Patients with unreliable visual field were excluded.

Hydrus Microstent

The nickel-titanium alloy used in constructing the Hydrus Microstent makes this medical device suitable for patient use. It is constructed to meet the exact curvature of Schlemm's canal and allows for the expansion and support of approximately one-fourth of the canal. Using the ab interno approach and moving the instrument through the resistive TM, the device is inserted into Schlemm's canal. The aperture of the Hydrus is responsible for the drainage of aqueous fluid from the anterior chamber (AC), and this fluid is then directed into the collecting channels via Schlemm's canal.

Statistical Analysis

Data analysis was performed with Microsoft Excel for Mac. A paired *t* test for the analysis with significance threshold was set at $p \leq 0.05$.

Procedure

Patients were prepped and draped in the usual sterile fashion for ophthalmic procedure. Clear cornea temporal cataract surgery was performed with phacoemulsification in the usual manner. After the intraocular lens was placed into position, EndoCoat (Abbott, Chicago, Illinois, USA) was instilled into the anterior chamber to keep the angle open. A paracentesis was made on the right side. The head of the patient was tilted 45 degrees away from the surgeon, and the head of the microscope was tilted at about 45 degrees toward the surgeon. The cornea was brought into focus. Endocoat was placed on the cornea, and a direct gonioscopy lens (Ocular) was placed on the cornea. The microscope focus was adjusted to bring the trabecular meshwork into focus in an en-face position. An MVR blade was inserted into the anterior chamber via the corneal incision to make an incision into the trabecular meshwork, and the back wall of Schlemm's canal was visualized. The delivery cannula was inserted via the right paracentesis, and the Hydrus Microstent was positioned into Schlemm's canal (SC) by rotating the finger wheel. The patient's head and microscope were returned to the usual position. Viscoelastic was removed from the anterior chamber. Balanced saline solution was inserted via a 27-gauge cannula via the paracentesis to confirm the presence of outflow to aqueous veins. Then, 1 cc of a solution consisting of diluted moxifloxacin HCl ophthalmic solution 0.5% (Vigamox; Novartis Pharma AG, Basel, Switzerland) and balanced saline was injected into the paracentesis site. Postoperative patients were given ophthalmic drops of ofloxacin QID, prednisolone acetate QID, and ketorolac TID.

Results

We identified 86 patients with mild to moderate glaucoma with complete records for the information for the study. The average age for the 86 study participants was 69 ± 11 years (Table 1). The average preoperative IOP was 14.1 ± 3.89 mmHg with an average use of 2.17 ± 1.31 ocular hypotensive medications (Figure 1). We did not washout patients for their medications before surgery as this was a retrospective real-world look at our results. 98% of patients were managed with one to three ocular hypotensive medications, while 12.9% of patients were managed with four or more medications. At 2 years follow-up, there was a significant decrease in the number of medications used at 0.42 ± 0.94 , an 80.6% drop from baseline (Table 2). Postoperatively, there was a reduction in IOP at day 1, 6 months, 1 year, and 2 years.

Table 1 Baseline Characteristics of Patients Who Underwent Hydrus Microstent Implantation

Variable		Statistics
Age (years)	Mean \pm SD	69 \pm 11
Sex, n (%)	Male	36 (41.9%)
	Female	50 (58.1%)
Eye, n (%)	Right	38 (44.2%)
	Left	48 (55.8%)
Baseline IOP (mmHg)	Mean \pm SD	14.1 \pm 3.8
Ocular hypotensive medications	Mean \pm SD	2.17 \pm 1.31
Patients using ocular hypotensive medications, n (%)	0	2 (2.3%)
	1	34 (39.5%)
	2	18 (20.9%)
	3	21 (24.4%)
	≥ 4	11 (12.9%)
Visual acuity (logMAR)	Mean \pm SD	0.32 \pm 0.06
MD on VFT (dB)	Mean \pm SD	-5.73 \pm 3.05
Type of glaucoma	POAG	86

There was also a decrease in the number of medications used at each visit. Postoperatively on day 1, the average IOP was 12.0 ± 4.87 , a 14.9% decrease from baseline. In addition, on postoperative day 1, all patients required zero medication, a 100% decrease from baseline. At 6 months follow-up, the IOP dropped below baseline and patients experienced an 88% reduction in ocular hypotensive medications used compared to baseline. At 1 year of follow-up, the average IOP was 13.7 ± 2.96 , a 2.8% decrease from baseline values and again, a 93.5% reduction in ocular hypotensive medications used compared to baseline. At 2 years, the mean IOP was 14.0 ± 3.20 (Figure 1). There were only a few minor adverse events that posed no threat to the sight of patients. There was 1 eye in which a transient hyphema was noted as well as 3 eyes in which IOP spikes were seen. An IOP spike is defined as an IOP over 30 mmHg and an increase of at least 10 mmHg above baseline.¹⁶ The pressure spikes were treated and self-limited.

Discussion

The results from HORIZON trial, followed up over a period of three years demonstrates a significant decrease in intraocular pressure (IOP) and number of medications used after cataract surgery combined with the Hydrus microstent.^{17,18} At baseline, the washed out IOP in the Hydrus Microstent group and cataract surgery alone group was 25.5 ± 3.0 mmHg and 25.4 ± 2.9 mmHg, respectively.¹⁷ After three years of follow-up, IOP was 16.7 ± 3.1 mmHg in the Hydrus Microstent group and 17.0 ± 3.4 in the cataract surgery alone group. In addition, many more patients in the Hydrus Microstent group were medication free with 73% of patients being medication free in the Hydrus Microstent group and 48% of patients being medication free in the cataract surgery alone group.¹⁷ At five years of follow-up, 66% of the patients were medication free in the Hydrus Microstent group and 46% in the cataract surgery alone group.⁹ In addition to maintaining lower intraocular pressure, there was no significant progression in visual field loss in our study. A post-hoc Bayesian hierarchical analysis of visual field data using the five-year HORIZON data appeared to indicate that the Hydrus Microstent plus cataract surgery group experienced an overall rate of progression of -0.26 dB/yr as compared to -0.49 dB/yr for the cataract surgery-alone group.¹⁹

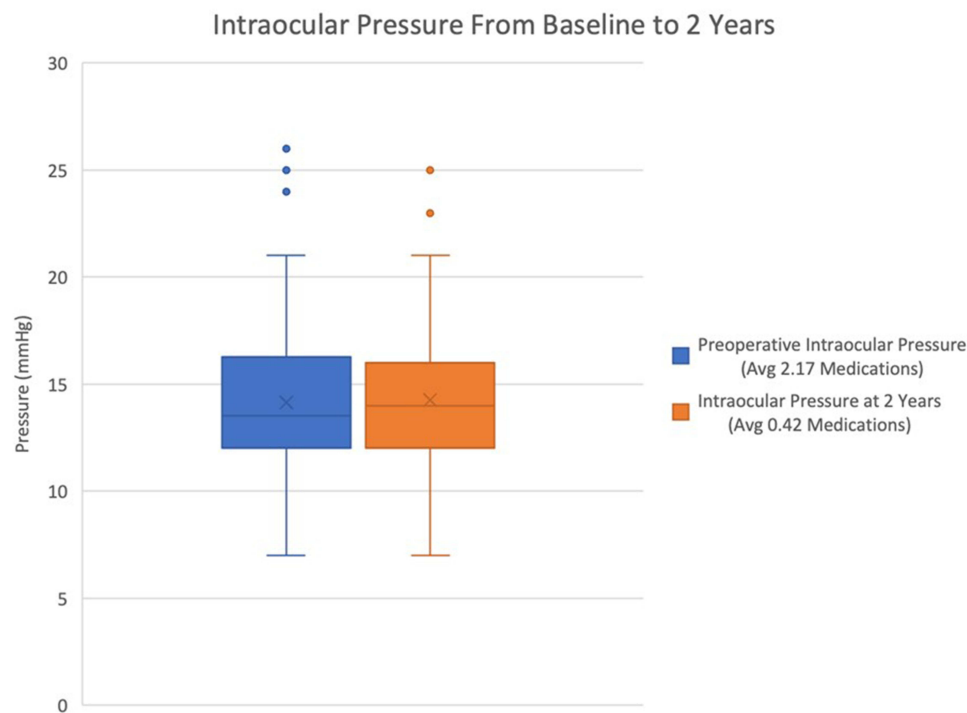


Figure 1 Box-and-whisker plot showing the changes in mean IOP from Baseline to 2 Years.

This retrospective study of 86 Black and Afro-Latino patients demonstrates the efficacy of Hydrus Microstent implantation for reducing IOP and decreasing medication dependence. All patients had an overall decrease in IOP at 2 years of 1.4% from a medication treated baseline, with 88% of patients becoming medication-free at two years. With aging, there is an enlargement of the lens which compresses the trabecular meshwork. Early cataract surgery combined with the Hydrus Microstent implant provides earlier therapeutic intervention and may favorably affect disease progression.⁵ Our patients had an average age of 69 years, which is less than the typical age (73 years) for cataract surgery.³ This suggests that earlier cataract surgery with Hydrus Microstent implantation may have a more favorable response in preserving trabecular meshwork function. All patients were able to maintain lower IOPs on either reduced or no pharmacologic agents, and patients reported improved clarity in vision. No patients required secondary surgery. Early control of IOP is important in slowing glaucoma progression and preserving vision. Black and Afro-Latino patients have a higher incidence of glaucoma, have less access to cataract and glaucoma surgery, and are also at a greater risk of

Table 2 IOP, Ocular Hypotensive Medications, CDVA, and Mean Deviation of Visual Field at Preoperative and Follow-Up Visits for All Patients

		IOP (mmHg)		Ocular Hypotensive Medications	CDVA	Visual Field Test
Timepoint	N	Mean \pm SD	N	Mean \pm SD	LogMAR (mean \pm SD)	Mean deviation \pm SD (dB)
Preoperative	86	14.1 \pm 3.89	86	2.17 \pm 1.31	0.31 \pm 0.06	-5.73 \pm 3.052
Postoperative day 1	85	12.0 \pm 4.87	–	–	–	-5.88 \pm 4.02
6 months	75	12.64 \pm 2.68	75	0.26 \pm 0.83	0.07 \pm 0.09	–
1 year	83	13.7 \pm 2.96	83	0.14 \pm 0.64	0.04 \pm 0.06	–
2 years	86	14.0 \pm 3.20 (p = 0.651)	86	0.42 \pm 0.93 (p = 0.000003)	0.04 \pm 0.07	-5.21 \pm 3.66

developing blindness from the disease.¹ Due to limited health-care accessibility and increasing medication costs which contribute to the lack of medication adherence among these patients, we believe earlier surgical intervention is important in the management of glaucoma patients over 50 years of age. This study provides further evidence of the preservation of visual field in this higher risk patient population with cataract surgery and the Hydrus Microstent. Our study was inherently limited by our relatively small sample size and the retrospective nature of our study. In the future, longer term follow-up as well as randomized trials which include a larger number of Black and Afro Latino patients are needed to better assess the efficacy of the Hydrus Microstent in this population.

Conclusion

In summary, this study demonstrates that the Hydrus Microstent effectively maintains low intraocular pressure (IOP) and significantly reduces medication dependence in Black and Afro-Latino patients with mild to moderate primary open-angle glaucoma over a two-year follow-up period. A substantial proportion of patients were able to discontinue medications and maintain lower intraocular pressure with minimal progression in visual field mean deviation. Importantly, no additional surgical interventions were required. These results suggest that the Hydrus Microstent offers a valuable therapeutic option for managing glaucoma in this high-risk population. However, further research, including larger-scale, randomized trials, is warranted to confirm its long-term efficacy and safety.

Data Sharing Statement

The datasets generated and/or analyzed during the current study are available from the corresponding author upon reasonable request.

Ethics Approval and Consent to Participate

We obtained a waiver of informed consent on 2/22/2023 as this was a retrospective conducted in accordance with the ethical standards of the Mount Sinai New York Eye and Ear Infirmary (IRB- STUDY-20-0006-MODCR001) and the principles of the Declaration of Helsinki.

Consent for Publication

Written consent is not applicable as we have an IRB waiver approval. There is no publication of identifiable information, such as images or case details.

Acknowledgments

We would like to express our gratitude to the staff of Advanced Eyecare of NY for their valuable contributions to this work. Their support and assistance have been integral to the successful completion of this project.

Author Contributions

All authors made a significant contribution to the work reported, whether that is in the conception, study design, execution, acquisition of data, analysis and interpretation, or in all these areas; took part in drafting, revising, or critically reviewing the article; gave final approval of the version to be published; have agreed on the journal to which the article has been submitted; and agree to be accountable for all aspects of the work.

Funding

This research was supported with a grant from Alcon.

Disclosure

The first author received a research grant from Alcon, a consultant to Johnson and Johnson, NIDEK, and a speaker for Sight Science. There are no other financial interests by the other co-authors.

References

1. Adebayo A, Laroche D. Unfulfilled Needs in the Detection, Diagnosis, Monitoring, Treatment, and Understanding of Glaucoma in Blacks Globally. *J Racial Ethn Health Disparities*. 2023;11(4):2103–2108. doi:10.1007/s40615-023-01679-2
2. Maier PC, Funk J, Schwarzer G, Antes G, Falck-Ytter YT. Treatment of ocular hypertension and open angle glaucoma: meta-analysis of randomised controlled trials. *BMJ*. 2005;331(7509):134. doi:10.1136/bmj.38506.594977.E0
3. Laroche D, Nkrumah G, Ng C. Real-world efficacy of the Hydrus microstent in Black and Afro-Latinx patients with glaucoma: a retrospective study. *Ther Adv Ophthalmol*. 2020;12:2515841420964311. doi:10.1177/2515841420964311
4. Racette L, Wilson MR, Zangwill LM, Weinreb RN, Sample PA. Primary open-angle glaucoma in blacks: a review. *Surv Ophthalmol*. 2003;48(3):295–313. doi:10.1016/S0039-6257(03)00028-6
5. Laroche D, Capellan P. The Aging Lens and Glaucoma in persons over 50: why early cataract surgery/refractive lensectomy and microinvasive trabecular bypass can prevent blindness and cure elevated eye pressure. *J Natl Med Assoc*. 2021;113(4):471–473. doi:10.1016/j.jnma.2021.03.001
6. Wang YH, Zhong J, Li XM. Age-related changes of lens thickness and density in different age phases. *Int J Ophthalmol*. 2022;15(10):1591–1597. doi:10.18240/ijo.2022.10.05
7. Cheng C, Parreno J, Nowak RB, et al. Age-related changes in eye lens biomechanics, morphology, refractive index and transparency. *Aging*. 2019;11(24):12497–12531. doi:10.18632/aging.102584
8. Xin C, Song S, Wang N, Wang R, Johnstone M. Effects of Schlemm's Canal Expansion: biomechanics and MIGS Implications. *Life*. 2021;11(2). doi:10.3390/life11020176
9. Ahmed IIK, De Francesco T, Rhee D, et al. Long-term Outcomes from the HORIZON Randomized Trial for a Schlemm's Canal Microstent in Combination Cataract and Glaucoma Surgery. *Ophthalmology*. 2022;129(7):742–751. doi:10.1016/j.ophtha.2022.02.021
10. Allison K, Patel DG, Greene L. Racial and Ethnic Disparities in Primary Open-Angle Glaucoma Clinical Trials: a Systematic Review and Meta-analysis. *JAMA Netw Open*. 2021;4(5):e218348. doi:10.1001/jamanetworkopen.2021.8348
11. Wilson R, Richardson TM, Hertzmark E, Grant WM. Race as a risk factor for progressive glaucomatous damage. *Ann Ophthalmol*. 1985;17(10):653–659.
12. Martin MJ, Sommer A, Gold EB, Diamond EL. Race and primary open-angle glaucoma. *Am J Ophthalmol*. 1985;99(4):383–387. doi:10.1016/0002-9394(85)90001-7
13. Glaucoma Laser Trial Research Group. The Glaucoma Laser Trial (GLT): 5. Subgroup differences at enrollment. *Ophthalmic Surg*. 1993;24(4):232–240.
14. Rouland JF, Berdeaux G, Lafuma A. The economic burden of glaucoma and ocular hypertension: implications for patient management: a review. *Drugs Aging*. 2005;22(4):315–321. doi:10.2165/00002512-200522040-00004
15. Laroche D, Oseni J, Nkrumah G, Ng C. Clear Lensectomy with Hydrus Stent in Black and Afro-Latino Patients: a 1-Year Retrospective Study. *J Ophthalmol*. 2022;2022:8011745. doi:10.1155/2022/8011745
16. Naftali Ben Haim L, Yehezkeili V, Abergel Hollander E, Dar N, Sharon T, Belkin A. Intraocular pressure spikes after gonioscopy-assisted transluminal trabeculotomy (GATT). *Graefes Arch Clin Exp Ophthalmol*. 2023;262(3):927–935. doi:10.1007/s00417-023-06265-0
17. Ahmed IIK, Rhee DJ, Jones J, et al. Three-Year Findings of the HORIZON Trial: a Schlemm Canal Microstent for Pressure Reduction in Primary Open-Angle Glaucoma and Cataract. *Ophthalmology*. 2021;128(6):857–865. doi:10.1016/j.ophtha.2020.11.004
18. Jones J, Koch DD, Vold S, et al. Results from the United States cohort of the HORIZON trial of a Schlemm canal microstent to reduce intraocular pressure in primary open-angle glaucoma. *J Cataract Refract Surg*. 2019;45(9):1305–1315. doi:10.1016/j.jcrs.2019.03.024
19. Montesano G, Ometto G, Ahmed IIK, et al. Five-Year Visual Field Outcomes of the HORIZON Trial. *Am J Ophthalmol*. 2023;251:143–155. doi:10.1016/j.ajo.2023.02.008

Clinical Ophthalmology

Dovepress

Publish your work in this journal

Clinical Ophthalmology is an international, peer-reviewed journal covering all subspecialties within ophthalmology. Key topics include: Optometry; Visual science; Pharmacology and drug therapy in eye diseases; Basic Sciences; Primary and Secondary eye care; Patient Safety and Quality of Care Improvements. This journal is indexed on PubMed Central and CAS, and is the official journal of The Society of Clinical Ophthalmology (SCO). The manuscript management system is completely online and includes a very quick and fair peer-review system, which is all easy to use. Visit <http://www.dovepress.com/testimonials.php> to read real quotes from published authors.

Submit your manuscript here: <https://www.dovepress.com/clinical-ophthalmology-journal>