

# Autologous Bone Marrow-Derived Mesenchymal Stem Cells in the Reversal of Unobstructed Azoospermia in Rats

Haifa A Al Turki<sup>1</sup>, Shaheed S Al-Suhaibani<sup>2</sup>, Danah Y AlShamlan<sup>1</sup>, Ayesha Ahmed<sup>3</sup>, Hussain A Alhawaj<sup>4</sup>

<sup>1</sup>Department of Obstetrics and Gynecology, Imam AbdulRahman Bin Faisal University, Dammam and King Fahd Hospital of the University, AlKhobar, Saudi Arabia; <sup>2</sup>Department of Urology, Imam AbdulRahman Bin Faisal University, Dammam and King Fahd Hospital of the University, AlKhobar, Saudi Arabia; <sup>3</sup>Department of Pathology, Imam AbdulRahman Bin Faisal University, Dammam and King Fahd Hospital of the University, AlKhobar, Saudi Arabia; <sup>4</sup>Department of Animal House, Imam AbdulRahman Bin Faisal University, Dammam and King Fahd Hospital of the University, AlKhobar, Saudi Arabia

Correspondence: Haifa A Al Turki, King Fahd Hospital of the University, PO. Box 2208, AlKhobar, 31952, Saudi Arabia, Tel +966505869021, Email drhturki@hotmail.com

**Background and Objective:** Non-obstructive azoospermia (NOA) is an important cause of male infertility. This study is being proposed to assess the efficacy of autologous bone marrow-derived mesenchymal stem cells (MSCs) in the reversal of busulfan-induced NOA in rats.

**Methods:** Twenty adult 3-month-old male rats were divided into two groups: a control group and a study group. In the study group, bone marrow was aspirated to culture MSCs. NOA was created by stopping endogenous spermatogenesis in all the animals by injecting two doses of busulfan 10 mg/kg body weight with a 3 week interval. Four weeks after the last dose of busulfan, two animals were euthanized and the testes were studied histologically to confirm complete azoospermia. In the study group, five million MSCs in 1 mL normal saline were injected into seminiferous tubules; and in the control group, 1 mL of normal saline was injected. After 4 weeks of MSC injection, all the rats were euthanized and epididymis tails and testes were harvested and sent for measurement of serological indices, including luminal, cellular, and total diameters, luminal, cellular, and cross-sectional areas, number of tubules per unit area of testis, numerical density of the tubules, and spermatogenesis index, pre- and post-MSC transplantation.

**Results:** The effect of busulfan on the testicular tissue was universally devastating. In the control group, there was variable length and width of markedly necrotic seminiferous tubules, whereas in the group treated with autologous bone marrow-derived MSCs there was variable height of germinal epithelium in seminiferous tubules, with active spermatogenesis, showing spermatogonia, spermatocytes, and sperm.

**Conclusion:** MSC injection in the testis has the potential to reverse the testicular function of spermatogenesis after cytotoxic therapy. Human trials should be undertaken to confirm our findings and bring the results into clinical practice.

**Keywords:** non-obstructive azoospermia, busulfan, spermatogenesis, mesenchymal stem cells

## Introduction

Many factors have been implicated in male infertility, including a reduction in sperm production, abnormal sperm functions, and obstruction to the movement of sperm. Non-obstructive azoospermia (NOA), which is defined as no sperm in the ejaculate, is an important cause of infertility. Jarow et al<sup>1</sup> reported that the incidence of azoospermia is between 10% and 15%,<sup>1</sup> and Esteves and Agarwal<sup>2</sup> found that in 75% of infertile men azoospermia is due to disorders of sperm production which are untreatable. However, despite severe spermatogenic dysfunction and no sperm in the ejaculate, there are areas of focal spermatogenesis in about 30–60% of these infertile men.<sup>3,4</sup> In these men, following sperm retrieval, the sperm is capable of inducing normal fertilization and the development of an embryo.<sup>5–7</sup>

The clinical and social management of men with NOA, without any sperm in the testis, who are seeking fertility, remains a challenge as NOA men have a wide spectrum of disorders, from genetic disorders to hormonal imbalances. At the present time, there are no treatments available that can restore spermatogenesis in the majority of NOA patients. Such men tend to be directed toward options such as adoption or donor sperm. Recent advances in stem cell therapy have raised the hopes of NOA patients with no sperm in their testes. Different cellular therapies for infertility problems have been studied, one of which is testicular transplantation of spermatogonial stem cell (SSC) tissue. Hermann et al<sup>8</sup> performed autologous transplantation of SSCs in rhesus macaques treated with busulfan, resulting in the testes producing functional sperm which fertilized the ovum. Cakici et al,<sup>9</sup> in a study on rats, demonstrated the recovery of fertility after the injection of adipose tissue-derived mesenchymal stem cells (MSCs). Later studies complemented each other, indicating that MSCs worked in the complete reversal of the testes to produce normal sperm.<sup>10–13</sup>

This study was conducted to confirm the efficacy of autologous bone marrow-derived mesenchymal stem cells (BMSCs) in the reversal of NOA induced by busulfan.

## Methods

The study was commissioned after receiving the approval of the Institutional Review Board of Imam AbdulRahman Bin Faisal University, Dammam, vide (#2023-01-110), dated 12<sup>th</sup> March 2023. Animal welfare guidelines were followed as per the Animal Welfare Act of the Cooperation Council for the Arab States of the Gulf (<https://leap.unep.org/>), and this study also adheres to the ARRIVE guidelines in regard to conducting the study and reporting the results. Twenty male adult rats were procured and divided into two groups: a control group and a study group. The rats were housed at a temperature of 25°C and fed ad libitum. The animals were anesthetized with intramuscular ketamine 50 mg/kg and 35 mg/kg of xylazine was administered. Ophthalmic ointment was applied to the eyes to prevent drying during the operation. In the study group, bone marrow was aspirated from the femoral shaft using a 18 gauge needle which was washed with heparin. The samples were transported at 4°C to StemCells Research and Regenerative Labs Inc, Hyderabad, India, to culture MSCs.

## Separation and Expansion of MSCs

MSCs were cultured from the bone marrow aspirate using the technique described by Piao et al.<sup>14</sup> Bone marrow aspirate was taken in a conical centrifuge tube and centrifuged at 2000 rpm for 5 minutes. The resultant layer containing mononuclear cells were siphoned out, and seeded onto a T75 tissue culture flask at the rate of 5000 cells/cm<sup>2</sup>. Then, 20 mL of MSC culture medium (Thermo Fisher, Massachusetts, USA) was added and the flask was incubated at 37°C, in 5% CO<sub>2</sub> and 95% humidity in a CO<sub>2</sub> incubator. The MSC culture medium was replaced every 2 days.

Non-adherent cells were washed off and the culture was continued, with a change of medium every 2 days, until the cells became confluent. Then, the cells were trypsinized and harvested. A portion of the cells was used for cell characterization using MSC-specific antibodies in a flow cytometer, and the expression of CD73, CD90, and CD105, and negativity for CD45, was confirmed. The MSCs were transported at –80°C and received at the animal facility in a Credo Cube<sup>TM</sup> (<https://www.pelibiothermal.com/products/credo-cube>). NOA was induced by stopping endogenous spermatogenesis in all the animals by injecting two doses of busulfan 10 mg/kg body weight with a 3 week interval. Four weeks after the last dose of busulfan, two animals were euthanized and the testes were studied histologically to confirm complete azoospermia.

## Surgical Procedure

Once total azoospermia had been confirmed, the testes were approached intra-abdominally; 5 million MSCs were injected into the seminiferous tubules in the study group and 0.5 mL of normal saline was injected in the control group. The testes were then returned to the abdominal cavity. Intramuscular ceftazidime 2.5 mg/kg and diclofenac 1 mg/kg were administered. Animals had free access to food and water throughout the study. After 4 weeks of MSC injection, all the rats were euthanized. Epididymis tails and testes were harvested and sent for assessment of serological indices, including luminal, cellular, and total diameters, luminal, cellular, and cross-sectional areas, number of tubules per unit area of testis, numerical density of the tubules, and spermatogenesis index.

## Statistical Analysis

All statistical tests were performed using SPSS version 25.0 (IBM Corp, Armonk, NY, USA). A *p* value of <0.05 was considered statistically significant, with a confidence interval (CI) of 95%.

## Results

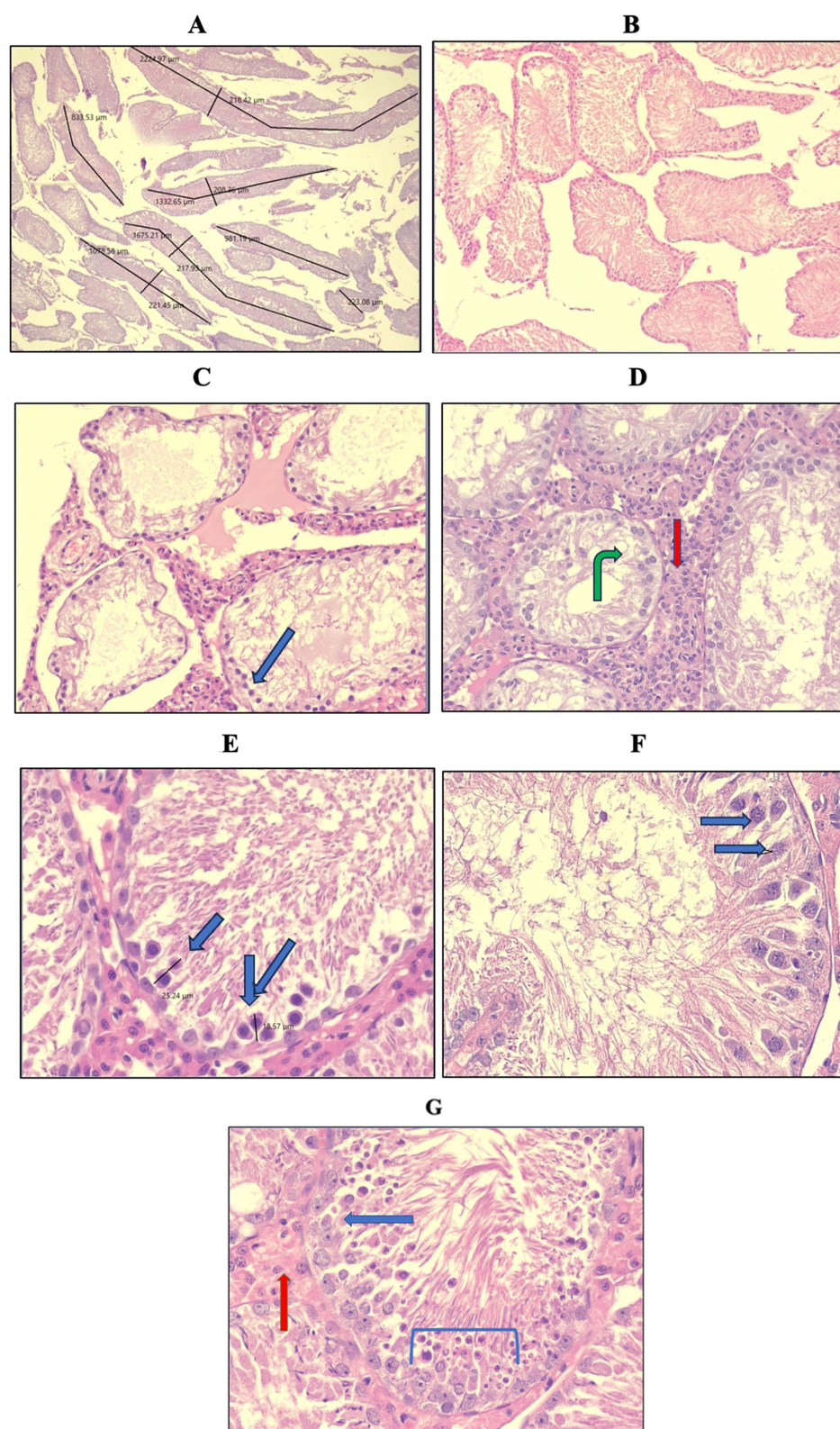
All animals survived the procedure and there were no deaths. Before injection, the autologous BMSCs were thawed and underwent flow cytometric analysis for confirmation of the MSCs. This showed negativity for CD45 and positive results for CD90, CD105, and CD166. An automated cell counter (Thermo Fisher) was used to count the autologous BMSCs; on average, 5.1 million cells were present in each vial and were injected. Post-injection of the busulfan, total necrosis of the germinal epithelium was observed. Table 1 presents the comparative data between the groups for the serological indices. All the tested and compared parameters showed that the study group animals had significantly improved, and the germinal epithelium had recovered from the insult of the busulfan, with evident spermatogonia and sperm.

## Histological Analysis

The control group showed necrosis with barely preserved germinal epithelium in the seminiferous tubules (STs), whereas in the study group, proliferating germinal epithelium with active spermatogenesis in the STs was evidenced. Histological analysis of the testes after busulfan administration revealed marked damage to STs and spermatogenic cells. In the control group, the number of STs per unit area was slightly lower (15–16/mm<sup>2</sup>) than in the study group and the STs showed marked necrosis (Figure 1A–F), irregular margins (Figure 1B and C), and foci of cytoplasmic vacuolization (Figure 1D). The germinal epithelium was predominantly lost, with STs showing just preserved Sertoli cells (Figure 1C–G). The rare foci of preserved germinal epithelium showed a mean height of 12–13 µm, reaching a maximum of 25 µm (Figure 1E), and

**Table 1** Comparative Data on the Serological Indices for the Two Groups

Parameters	Control Group	Study Group	p Value
Testicular length (cm)	1.375±0.221	1.421±0.27	0.7534
Testis width (cm)	0.825±0.15	0.872±0.17	0.66
Seminiferous tubules length maximum (mm)	1148.5±149.1	1347.5±34.57	0.0097
Seminiferous tubules diameter (µm)	233.5±10.07	203±19.23	0.006
Seminiferous tubule margins	Irregular 1.5	Smooth	NA
Basement membrane thickening	0	1	NA
Number of tubules per unit area (mm <sup>2</sup> )	14.75±0.5	16.5±1.37	0.014
Seminiferous tubule necrosis	4	0	0.0001
Cytoplasmic vacuolization	3±0.1	1.66±0.51	0.0001
Germinal epithelium height (µm) (mean of 10 fields)	9.5±6.3	84.8±14.02	0.0001
Spermatogonia	0.187±0.125	3.6±0.54	0.0001
Spermatocytes	0.187±0.125	3.2±0.836	0.0001
Sperm	0.75±0.5	2.4±1.3	0.015
Sertoli cells	4±0.1	3.8±0.44	0.21
Leydig cells	1.375±1.1	0.85±0.336	0.28

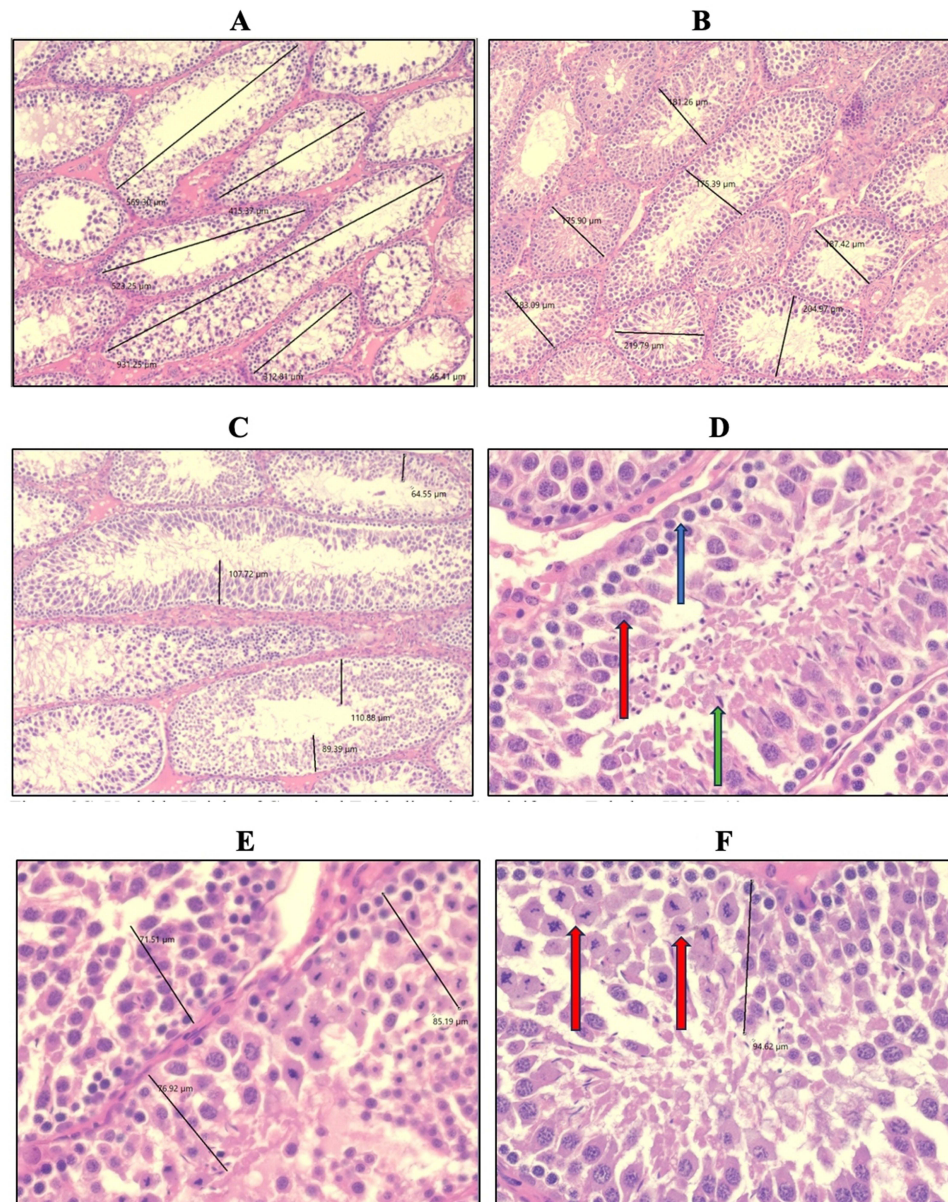


**Figure 1** Photomicrographs of cross-sections of testes of the control and study groups. **(A)** Variable length and width of markedly necrotic seminiferous tubules, H&E  $\times 4$ . **(B)** Marked necrosis seen in seminiferous tubules, showing irregular margins, H&E  $\times 10$ . **(C)** Preserved Sertoli cells in markedly necrotic, irregular seminiferous tubules (arrowhead), H&E  $\times 20$ . **(D)** Prominent Leydig cells (red arrow) around seminiferous tubules showing vacuolization (green arrow), H&E  $\times 20$ . **(E, F)** Rare foci of preserved spermatogonia with germinal epithelium height (E) and spermatocytes (F) in seminiferous tubules with marked necrosis, H&E  $\times 40$ . **(G)** Preserved Sertoli cells (blue arrow) and marked apoptosis in germinal epithelium (blue bracket). Leydig cells are seen in the interstitium (red arrow). H&E  $\times 40$ .



comprising few viable spermatogonia and rare spermatocytes (Figure 1E and F). Prominent Leydig cells (Figure 1D–H) were evident in the interstitium in all animals.

The group administered stem cells revealed slightly more STs ( $16\text{--}17/\text{mm}^2$ ), with smooth, rounded margins (Figure 2A and B). The STs showed viable, proliferating germinal epithelium (Figure 2A–F) with no evidence of necrosis. Foci of cytoplasmic vacuolization were, however, present. The germinal epithelium showed variable height, with a mean of  $80\text{ }\mu\text{m}$ , and reaching a maximum height of  $110.88\text{ }\mu\text{m}$  (Figure 2C). Brisk spermatogenesis was evidenced by prominent spermatogonia and spermatocytes, with some showing maturation to spermatozoa (Figure 2D). Active mitosis was also seen in the germinal epithelium (Figure 2F). Sertoli cells were consistently seen in all STs, along with some scattered Leydig cells in the interstitium.



**Figure 2** Restoration of germinal epithelium and spermatogenesis in necrosed testis post-transplantation of autologous bone marrow-derived mesenchymal stem cells. (A, B) Length and width of seminiferous tubules, showing active spermatogenesis, H&E  $\times 10$ . (C) Variable height of germinal epithelium in seminiferous tubules, H&E  $\times 10$ . (D) Active spermatogenesis showing spermatogonia (blue arrow), spermatocytes (red arrow), and sperm (green arrow) in seminiferous tubules, H&E  $\times 40$ . (E, F) Variable height of germinal epithelium in seminiferous tubules with active mitosis seen in (F) (red arrow), H&E  $\times 40$ .

## Discussion

In the present investigation, we found that there was notable reversal of testicular pathology after busulfan injection under the influence of BMSCs. The morphology of the testis showed obvious changes in the size and weight of the testicle, providing unequivocal evidence of the regeneration process in the study group of animals, which was not observed in the normal saline-treated animals. Furthermore, MSCs demonstrated their ability to induce a high proliferation and recovery of the testis post-busulfan therapy. The germinal epithelium, spermatocytes, and the presence of sperm were all highly significant in the study group of animals in comparison to the control group. Our findings support the results of an earlier study by Zhang et al.<sup>15</sup> It was shown that BMSCs expressed integrin- $\beta$ , suggesting that BMSCs have the potential to transform into sperm cells. Zhang et al<sup>15</sup> demonstrated that BMSCs survived and were located in the basement of the seminiferous tubule in the azoospermic rat model after transplantation because MSCs originate from the mesoderm, which can give rise to sperm cells. Karimaghai et al<sup>16</sup> reported that adipose tissue-derived MSCs had a similar result in the induction of spermatogenesis in seminiferous tubules of azoospermic hamsters. Zhankina et al<sup>17</sup> found that exosome-derived MSCs can also influence spermatogenesis in NOA.

MSCs have the unique properties of maintaining a process of recurrent self-renewal and possessing permanent pluripotency, which indirectly enhance spermatogenesis.<sup>18–20</sup> Apart from their self-renewal potential, MSCs have robust immunomodulatory effects, which are mediated through the cytokines and affect the local environment. These effects occur whether the cell is alive or apoptotic, and this suggests that even if testicular function is compromised by autoimmune disease, transplantation of MSCs in the testis can be effective.<sup>21</sup> Naji et al<sup>22</sup> concluded that therapy with MSCs now appears promising, with easily obtained cells and cultures that are genetically stable, and their regenerative properties can enable tissue repair and immune suppression. Optimized MSCs are usually derived from sources such as bone marrow, adipose tissue, or umbilical cord. Bone marrow-derived cells are the preferred choice of MSC owing to the ease of aspiration from the iliac crest.<sup>23</sup> We used bone aspiration to culture MSCs as we had previous experience of this procedure in small animals.

Our study has limitations in that we based on our conclusions on the histopathology rather than a combination of hormonal measurements and histopathology. Our results could be confirmed by the improvement of testosterone and reduction of follicle-stimulating hormone levels post-MSCT treatment. In conclusion, our study shows that MSCs can improve testicular damage following cytotoxic therapy. This is due to the paracrine factors that are secreted by MSCs. The cells secrete chemokines, cytokines, and growth factors, inducing surrounding damaged cells to renew and differentiate into mature cell lines, while immune modulation affects the testicular niche and restores the process of spermatogenesis. The use of MSCs in NOA can improve the functions of the testis in relation to spermatogenesis and spermiogenesis, which could herald a new avenue of treatment for male infertility. Human trials should be undertaken to confirm our findings and bring the results into clinical practice.

## Data Sharing Statement

The data are available from [dsr@iau.edu.sa](mailto:dsr@iau.edu.sa)

## Consent for Publication

All authors give consent for publication.

## Ethics Approval and Animal Rights

The IRB of Imam AbdulRahman Bin Faisal University gave the approval for this study, vide #2023-01-110, dated 12<sup>th</sup> March 2023. Animal experiments Were conducted in accordance with the ARRIVE guidelines.

## Funding

There was no funding for this study.

## Disclosure

The authors report no conflicts of interest in this work.

## References

1. Jarow JP, Espeland MA, Lipshultz LI. Evaluation of the azoospermic patient. *J Urol*. 1989;142(1):62–65. doi:10.1016/S0022-5347(17)38662-7
2. Esteves SC, Agarwal A. The azoospermic male: current knowledge and future perspectives. *Clinics (Sao Paulo)*. 2013;68(Suppl 1):1–4. doi:10.6061/clinics/2013(Sup01)01
3. Silber SJ. Microsurgical TESE and the distribution of spermatogenesis in non-obstructive azoospermia. *Hum Reprod*. 2000;15:2278–2284. doi:10.1093/humrep/15.11.2278
4. Esteves SC, Miyaoka R, Agarwal A. Sperm retrieval techniques for assisted reproduction. *Int Braz J Urol*. 2011;37:570–583. doi:10.1590/S1677-55382011000500002
5. Carpi A, Sabanegh E, Mechanick J. Controversies in the management of nonobstructive azoospermia. *Fertil Steril*. 2009;91:963–970. doi:10.1016/j.fertnstert.2009.01.083
6. Belva F, De Schrijver F, Tournaye H, et al. Neonatal outcome of 724 children born after ICSI using non-ejaculated sperm. *Hum Reprod*. 2011;26:1752–1758. doi:10.1093/humrep/der121
7. Esteves SC, Prudencio C, Seol B, et al. Comparison of sperm retrieval and reproductive outcome in azoospermic men with testicular failure and obstructive azoospermia treated for infertility. *Asian J Androl*. 2014;16:602–606. doi:10.4103/1008-682X.126015
8. Hermann B, Sukhwani M, Winkler F, et al. Spermatogonial stem cell transplantation into rhesus testes regenerates spermatogenesis producing functional sperm. *Cell Stem Cell*. 11: 715–726.
9. Cakici C, Buyrukcu B, Durusu G, et al. Recovery of Fertility in Azoospermia Rats after Injection of Adipose-Tissue-Derived Mesenchymal Stem Cells: the Sperm Generation. *Biomed Res. Int*. 2013;529589:18. doi:10.1155/2013/529589
10. Hajihoseini M, Vahdati A, Ebrahim Hosseini S, Mehrabani D, Tamadon A. Induction of spermatogenesis after stem cell therapy of azoospermic Guinea pigs. *Veterinarski Arhiv*. 2017;87(3):333–350. doi:10.24099/vet.arhiv.151209
11. Mehrabani D, Hassanshahi MA, Tamadon A, et al. Adipose tissue- derived mesenchymal stem cells repair germinal cells of seminiferous tubules of busulfan-induced azoospermic rats. *J Human Reproductive Sci*. 2015;8(2):103–110. doi:10.4103/0974-1208.158618
12. Tamadon A, Mehrabani D, Rahmanifar F, et al. Induction of spermatogenesis by bone marrow- derived mesenchymal stem cells in busulfan-induced azoospermia in hamster. *Int J Stem Cells*. 2015;8:134–145. doi:10.15283/ijsc.2015.8.2.134
13. Rahmanifar F, Tamadon A, Mehrabani D, et al. Histomorphometric evaluation of treatment of rat azoospermic seminiferous tubules by allotransplantation of bone marrow- derived mesenchymal stem cells. *Iran J Basic Med Sci*. 2016;19(6):653.
14. Piao H, Youn TJ, Kwon JS, et al. Effects of bone marrow derived mesenchymal stem cells transplantation in acutely infarcting myocardium. *Eur J Heart Fail*. 2005;7(5):730–738. doi:10.1016/j.ejheart.2004.09.019
15. Zhang D, Liu X, Peng J, et al. Potential spermatogenesis recovery with bone marrow mesenchymal stem cells in an azoospermic rat model. *Int J Mol Sci*. 2014;15(8):13151–13165. doi:10.3390/ijms150813151
16. Karimaghani N, Tamadon A, Rahmanifar F, et al. Spermatogenesis after transplantation of adipose tissue-derived mesenchymal stem cells in busulfan-induced azoospermic hamster. *Iran J Basic Med Sci*. 2018;21(7):660–667. doi:10.22038/IJBMS.2018.29040.7010
17. Zhankina R, Baghban N, Askarov M, et al. Mesenchymal stromal/stem cells and their exosomes for restoration of spermatogenesis in non-obstructive azoospermia: a systemic review. *Stem Cell Res Ther*. 2021;12(229). doi:10.1186/s13287-021-02295-9
18. Guan K, Nayernia K, Maier LS, et al. Pluripotency of spermatogonial stem cells from adult mouse testis. *Nature*. 2006;440:1199–1203. doi:10.1038/nature04697
19. Seandel M, James D, Shmelkov SV, et al. Generation of functional multipotent adult stem cells from GPR125+ germline progenitors. *Nature*. 2007;449:346–350. doi:10.1038/nature06129
20. Gassei PBT, K OKE, Orwig KE. Spermatogonial stem cell regulation and spermatogenesis. *Philos Trans R Soc Lond B Biol Sci*. 2010;365:1663–1678. doi:10.1098/rstb.2010.0026
21. Weiss ARR, Dahlke MH. Immunomodulation by Mesenchymal Stem Cells (MSCs): mechanisms of Action of Living, Apoptotic, and Dead MSCs. *Front Immunol*. 2019;10:1191. doi:10.3389/fimmu.2019.01191
22. Naji A, Eitoku M, Favier B, Deschaseaux F, Rouas-Freiss N, Suganuma N. (2019). Biological functions of mesenchymal stem cells and clinical implications. *Cell Mol Life Sci*. 76(17):3323–3348. doi:10.1007/s00018-019-03125-1
23. Kannan S, Gokul Krishna S, Gupta PK, Kolkundkar UK. Advantages of pooling of human bone marrow-derived mesenchymal stromal cells from different donors versus single-donor MSCs. *Sci Rep*. 14(1):12654. doi:10.1038/s41598-024-62544-8

Stem Cells and Cloning: Advances and Applications

Dovepress

Publish your work in this journal

Stem Cells and Cloning: Advances and Applications is an international, peer-reviewed, open access journal. Areas of interest in established and emerging concepts in stem cell research include: Embryonic cell stems; Adult stem cells; Blastocysts; Cordblood stem cells; Stem cell transformation and culture; Therapeutic cloning; Umbilical cord blood and bone marrow cells; Laboratory, animal and human therapeutic studies; Philosophical and ethical issues related to stem cell research. This journal is indexed on CAS. The manuscript management system is completely online and includes a very quick and fair peer-review system, which is all easy to use. Visit <http://www.dovepress.com/testimonials.php> to read real quotes from published authors.

Submit your manuscript here: <https://www.dovepress.com/stem-cells-and-cloning-advances-and-applications-journal>