

Appendicular Ureteroplasty for a Firearm Related Rupture of the Right Ureter

Bachelard Cissa Wa Numbe^{1,2}, Antoine Mulungano Mirindi^{1,2}, Juvenal Cirhuza Nnashi^{1,2}, Costa Sudi Musilimu^{1,2}, Jean de Dieu Tumusifu Manegabe^{1,2}, Dominique Chimanuka Mirindi^{1,2}, Ghislain Balemba Maheshe^{2,3}, Eric Namegabe Mugabo^{2,4}, Safari Mudekereza Paterne^{1,2}, Léon-Emmanuel Mukengeshai Mubenga^{1,2,5}

¹Department of Surgery, Faculty of Medicine, Université Catholique de Bukavu (UCB), Bukavu, Democratic Republic of Congo; ²General Provincial Reference Hospital of Bukavu, Bukavu, Democratic Republic of Congo; ³Department of Radiology, Faculty of Medicine, Université Catholique de Bukavu (UCB), Bukavu, Democratic Republic of Congo; ⁴Department of Anesthesiology, Faculty of Medicine, Université Catholique de Bukavu (UCB), Bukavu, Democratic Republic of Congo; ⁵Institut supérieur des techniques médicales de Bukavu (ISTM Bukavu), Bukavu, Democratic Republic of Congo

Correspondence: Bachelard Cissa Wa Numbe, Email wcissal@gmail.com

Abstract: One of the most challenging aspects of urology is restoring patency to ureters with long defects. In certain cases, it may not be feasible to perform plastic surgery on the ureter with its own tissue or bladder. In such instances, alternative solution like appendicular ureteroplasty may be promising solution. Ureteral injuries have several etiologies, some of them are secondary to unintentional ureteral trauma during surgery. More than half of these injuries are unrecognized during the first laparotomy. Extensive ureteral injuries are difficult to repair, even with application of several types of surgical techniques. The advantage of appendicular ureteroplasty is the simplicity of the ureteral replacement technique without compromising other substitution options in case of failure. This is a case report of a young adult with abdominal gunshot injuries, with significant loss of tissues located to distal third of the right ureter. The appendicular urethroplasty was successfully performed. The patient remained stable after one year of out follow-up as an outpatient.

Keywords: ureteroplasty, firearm, appendix

Introduction

Several ureteral injury etiologies are described; they may include iatrogenic trauma during ureteroscopy, intestinal surgery, obstetrical and gynecological surgeries, neurosurgery and penetrating trauma of various origins.¹⁻⁵

Ureteral injuries may go unnoticed during first laparotomy performed in a polytrauma patient because attention is often drawn to hemorrhagic injuries undergoing a damage control surgery.^{3,6}

Surgical repair of ureteral injuries uses several techniques such as anastomosis, ureteral reimplantation, bladder flap (Boari flap), trans-uretero-ureterostomy (TUU) and even renal auto-transplantation.⁷

Ureteral repair is more complex in the context of extensive injuries, with loss of ureteral tissues. In this context, replacement of the lost segment can be done using an ileal or appendicular flap.⁷⁻⁹

Case Presentation

We know that attempts to use the appendix in ureteral reconstruction were made over a century ago. The first mention of the possibility of using the appendix to replace the ureter was reported by Melnikoff in 1912.¹⁰ In a review of the literature on the surgical treatment of ureteral stenosis, Melnikoff mentions the Italian researcher Giannettasio (1901) and the German surgeons Rydygier (1903) and Franke (1909) who used the appendix for ureteral replacement in their experiments. Kuss et al were among the first to report successful appendicular ureteroplasty in clinical practice.¹¹ Despite this, the appendix is much more commonly used by urologists as a conduit to form the continence mechanism and appendiceal ureteroplasty is a rare surgical procedure. A review of the literature shows that there are currently only

a handful of published studies on similar use of the appendix. However, we believe that this procedure is overlooked by urologists and can be performed as part of reconstructive ureteral surgery in both adults and children.⁹

This is a 26-year-old patient. He was shot 25 days previously and had an abdominal wound (right buttock to sub umbilical region). He underwent a first laparotomy which noticed intestinal injuries and right retroperitoneal opening communicating with the right buttock. Injuries were debrided, and intestinal lesions subsequently sutured.

The evolution was marked by a persistent release of a liquid with urine odor in the right buttock wound, suggesting an ureteral injury.

The patient was then transferred to this tertiary hospital three weeks after the trauma, for further surgical treatment.

On arrival, he was clinically stable. The right buttock wound was covered with a colostomy bag, containing liquid with urine aspect.

Laboratory investigations were normal.

Intravenous urography revealed interruption in the progression of the contrast at the level of the right pelvic ureter, and its accumulation at the right pelvic level then its progression towards the right buttock in the form of a fistula (Figure 1).

During the second laparotomy, we noted a significant fibrosis in all the abdominal cavity, especially in the right ilium region, and pelvic cavity, rending laborious the exploration. The vermicular appendix was with normal appearance, but a loss of the third distal part of the right ureter (approximately 8 cm) was mentioned. Bladder mobilization was limited by fibrosis. (Figures 2 and 3).

In addition, we found urine collection in the right pelvic region, flowing towards the ipsilateral buttock.

An isoperistaltic appendiceal ureteroplasty was performed on a double J ureteral catheter 6/26 (Figure 4). The uretero-appendicular and appendicular-bladder anastomoses were performed with Vicryl 4/0 using simple stitches, after excision of the appendicular tip. An abdominal drain was left next to the anastomoses.

The patient was treated with antibiotics and analgesics postoperatively.

The abdominal drain brought back less than 20 mL of normal peritoneal fluid and was removed after 48 hours.

The abdominal-gluteal urinary fistula dried up after a week of daily normal saline dressing.

The ureteral catheter was ablated after eight weeks. Under cystoscopy, the new right ureteral meatus was observed patent, with urinary flow synchronous to that of the left side (Figure 5). Urea and Creatinine remained normal. The Urologic CT- scan confirmed the viability and permeability of the appendicular graft (Figure 6). The patient remained stable after one year of out follow-up as an outpatient.

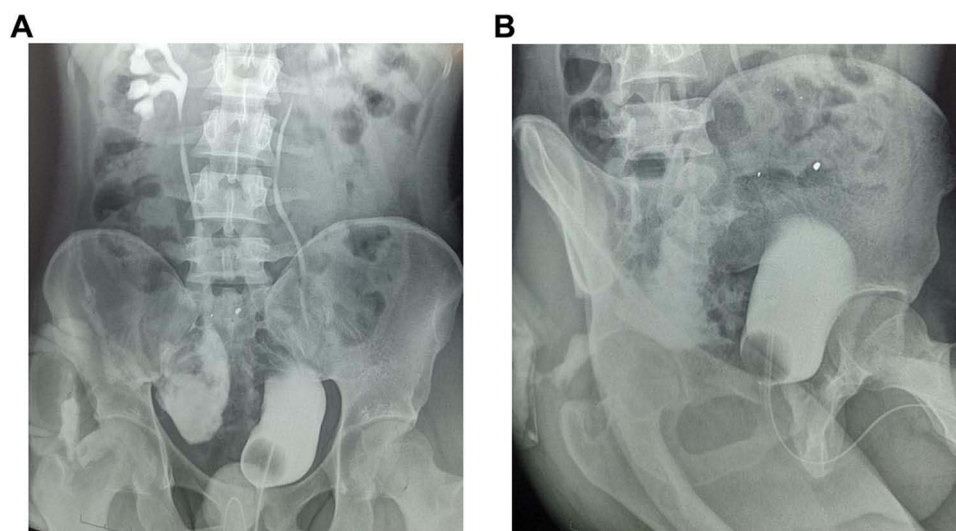


Figure 1 (A and B) Intravenous urography showing collection of contrast in the right pelvic region, draining to the gluteal region.

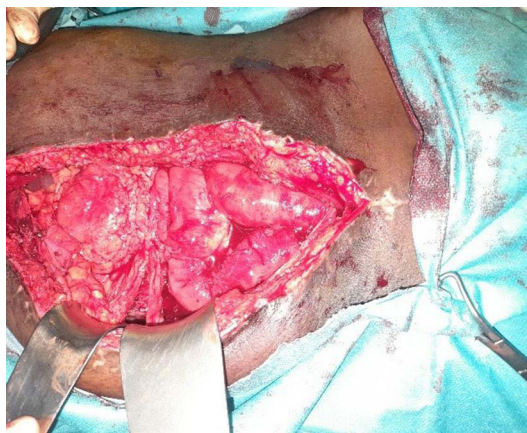

Figure 2 Adherences in the abdominal cavity.

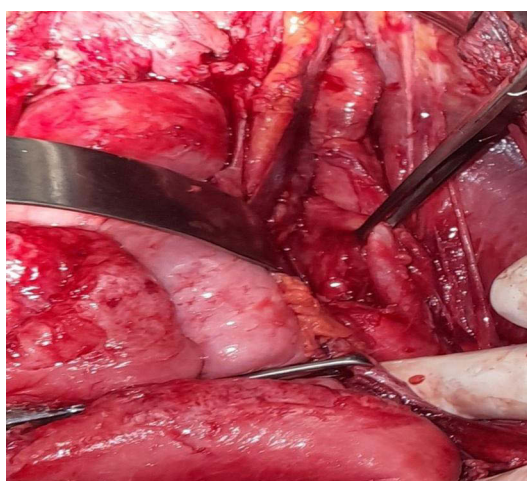

Figure 3 Important fibrosis in the right pelvic region with normal vermicular appendix.

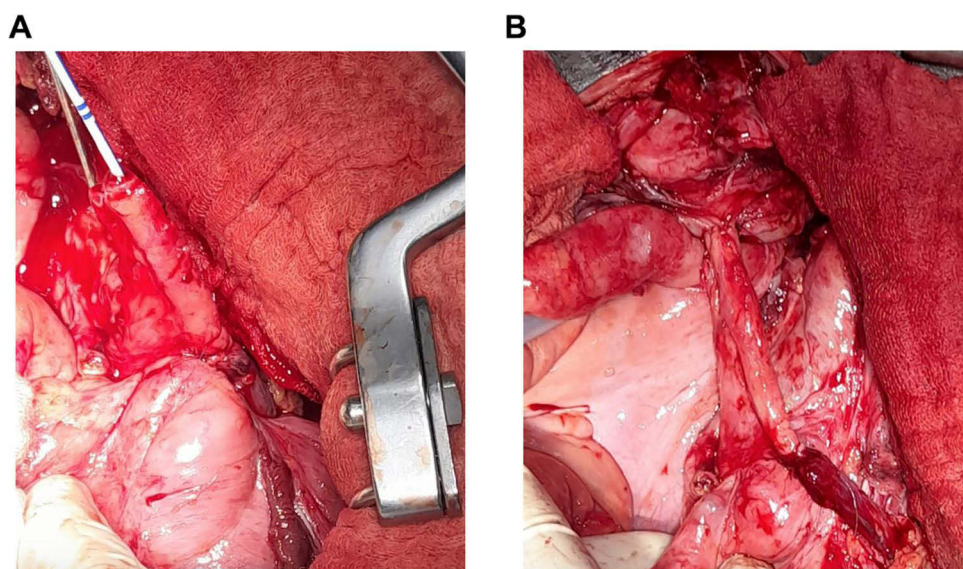


Figure 4 (A and B) Appendiceal ureteroplasty of the third distal ureter on a double J catheter.

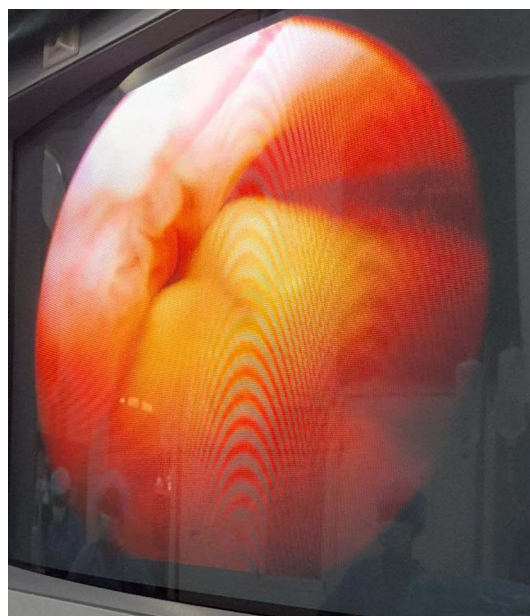


Figure 5 Cystoscopic view of the implanted ureteral meatus.

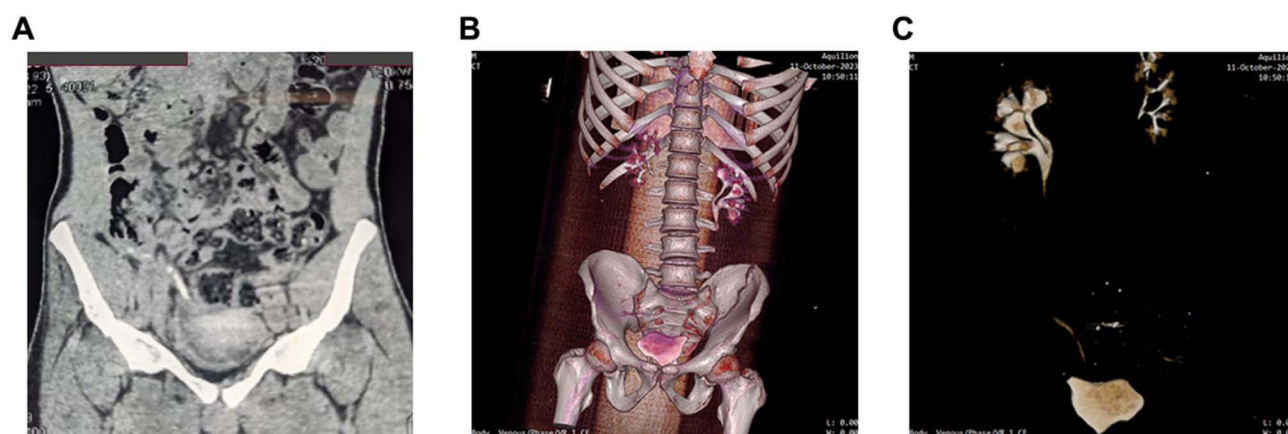


Figure 6 (A–C) Postoperative Uroscanner confirming viability and permeability of appendicular graft.

Discussion

This case report merits the attention of all surgeons worldwide to the usefulness of the appendix in the reconstruction of ureteral defects, long neglected by urologists. Several success stories have been reported in the literature.

Ureteral trauma are mainly iatrogenic, during gynecological, obstetrical, intestinal, spinal and vascular surgical procedures.^{1–5}

Endoscopic urological surgeries are currently among the main causes of ureteral injuries.^{4,12}

In a context of insecurity and armed conflicts, as in the Eastern DR Congo for more than two decades, abdominal trauma by firearms or explosives also increases the incidence of ureteral injuries.¹³

Apart from the risk of being overlooked during the first laparotomy due to associated visceral/vascular injuries which are more remarkable, ureteral wounds may pose real challenges for their repair.¹²

Several types of surgical techniques such as suturing, end-to-end anastomosis, or ureterovesical reimplantation have been described for repair of ureteral injuries.¹⁴

In the case of extensive loss of ureteral tissue, a trans-uretero-ureterostomy (TUU), an interposition of a bladder or an ileal flap, the renal descent technique, or the auto-transplantation of the kidney are possible.^{12,15}

Many indications of ureteral reconstruction using vermicular appendix are described in cases of important loss of ureteral tissue, mainly in the right ureter, regardless the site or the etiology of the injury.¹⁰

Idiopathic retroperitoneal fibrosis, also known as Ormond's disease, urogenital tuberculosis or Haematobium schistosomiasis with subsequent moniliform ureters, are among the main non-traumatic etiologies, which require ureteral reconstruction, with replacement of damaged segments.⁹

The use of the appendix for the replacement of a segment of the left ureter is of limited indication because of the increased risk of tension on the anastomosis.^{1,7,8}

In the present case, the abdominal cavity had a lot of adhesions, due to multiple gunshot intestinal injuries, the first laparotomy, the time elapsed before the second laparotomy as well as the peritoneal irritation by continuous urine flow.

This situation has made the choice of other ureteral replacement techniques impractical.

Thus, for TUU, the need to open the retroperitoneum twice and pass directly before the large abdominal vessels represented significant risk of iatrogenic vascular and/or visceral injuries.

For the Boari flap and the psoas hitch, the significant pelvic fibrosis due to the continuous irritation of the peritoneum would not have allowed the mobilization of the bladder to perform these surgical techniques.

The buccal mucosa was not used to reconstruct the ureter in this case because the patient had a long history of smoking.

As for renal auto-transplantation or renal descent techniques, they were impossible in an abdominal cavity full of intestinal adhesions and fibrosis.

Appendicular ureteral reconstruction was therefore the best surgical technique for this patient. The normal macroscopic appearance of the appendix as well as its proximity to the area of ureteral defect allowed this technique to be performed.

The appendix is considered to be a useless organ. Its role in the immune system as lymphoid organ is of limited importance. However, it constitutes an important substitution or compensation tissue for ureteral reconstruction.¹⁶

In the Mitrofanoff operation, for example, the appendix is used to create an appendico-vesicostomy allowing self-catheterization in cases of significant sphincter disorders or difficulties with bladder emptying.¹⁰

Attempts to use the appendix in ureteral reconstruction were made over a century ago. The first mention of the possibility of ureteral substitution with the appendix was reported in 1912 by Melnikoff.⁶ Literature review focused on the surgical treatment of ureteral strictures mentioned the Italian researcher Giannettasio (1901), and the German surgeons Rydygier (1903) and Franke (1909), who used the appendix for ureteral substitution.

Kuss et al were among the first to report clinically successful appendiceal ureteroplasties.¹¹

Several authors emphasized the advantages of this technique:^{8–10,17}

The appendix has a robust blood supply; in addition, the appendicular lumen (4–5 mm) is adapted to that of the ureter (8 mm), enabling good uretero-appendicular anastomosis.

The long-term success of appendiceal ureteral replacement in terms of satisfactory transport of urine and maintaining good renal function has been documented.⁸

Its small diameter prevents stasis and its small surface area minimizes urine reabsorption, thus avoiding electrolyte disorders.

The risk of having graft appendicitis has not been described in the literature; but considering that inflammation of the appendix is generally due to secretion in obstructed lumen, this probability is surely less given that the appendicular graft maintains its permeability.

However, hydronephrosis and urinary tract stones development due to anastomotic stenosis are possible and must be regularly monitored in patients who have undergone appendicular ureteral reconstruction. Some authors suggest that these two events are uncommon because of continuous urinary flow and appendicular peristalsis.¹⁰

The length of the appendicular graft for reconstruction of significant ureteral defects, the certainty of absence of inflammation at the time of harvesting, as well as the difficulties of using it on the left are the main limitations of this technique.^{15,18}

Limit

The one year follow-up is still short to confirm the long-term progression of this patient.

Conclusion

The patient had a gunshot wound that injured the distal third of the right ureter, and replacement of the ureter with the appendix is safe and feasible in this case.

Appendicular ureter reconstruction is an easy technique to perform; the vermicular appendix is a good quality graft, which can be used to replace a segment of the right ureter, regardless of its location.

Compliance with Ethical Standards

This study received ethical clearance from the Ethical Committee of the Catholic University of Bukavu.

We have obtained the approval of the Catholic University of Bukavu for the publication of this case report.

Consent

The patient provided written informed consent for publication of the case report and images.

Author Contributions

BCW: Conceptualization, initial draft and final version,

LMM: Conceptualization, supervision and validation of the final version.

All authors made a significant contribution to the work reported, whether that is in the conception, study design, execution, acquisition of data, analysis and interpretation, or in all these areas; took part in drafting, revising or critically reviewing the case report; gave final approval of the version to be published; have agreed on the journal to which the article has been submitted; and agree to be accountable for all aspects of the work.

Funding

There is no funding to report.

Disclosure

The authors report no conflicts of interest in this work.

References

1. Cao H, Zhou H, Yang F, et al. Laparoscopic appendiceal interposition pyeloplasty for long ureteric strictures in children. *J Pediatr Urol.* 2018;14:551.e1–551.e5. doi:10.1016/j.jpuro.2018.06.017
2. Astini C, Severoni S. Ureteral reconstruction using the vermiform appendix flap in a patient with a post traumatic uretero cutaneous fistula. *Trop Doct.* 1997;27:47–48. doi:10.1177/004947559702700118
3. Fernandez A, Soria S, Gomez I, Gil J, Martinez F, Otero G. Blunt traumatic rupture of the high right ureter repaired with appendix interposition. *Urol Int.* 1994;53:97–98. doi:10.1159/000282644
4. Alcantara-Quispe C, Xavier JM, Atallah S, et al. Laparoscopic left ureteral substitution using the cecal appendix after en-bloc rectosigmoidectomy: a case report and video demonstration. *Tech Coloproctol.* 2017;21:817–818. doi:10.1007/s10151-017-1694-9
5. Dias Filho AC, Martinez CAT, Côte MB, Maroccolo MVO. Left ureteral appendiceal interposition: exercise caution and do not be misled by postoperative radiological obstruction. *Int Braz J Urol.* 2018;44:400–402. doi:10.1590/s1677-5538.ibju.2017.0295
6. Melnikoff AE. Sur le remplacement de l'uretère par anse isolée de l'intestine grêle. *Rev Clin Urol.* 1912.
7. Xiong S, Zhu W, Li X, Zhang P, Wang H, Li X. Intestinal interposition for complex ureteral reconstruction: a comprehensive review. *Int J Urol.* 2020;27:377–386. doi:10.1111/iju.14222
8. Williams TR, Diallo I, Issa M, Massarweh NN. Ureteral reconstruction with appendiceal interposition graft following resection of retroperitoneal leiomyosarcoma. *J Surg Case Rep.* 2023;2023(7):rjad414. doi:10.1093/jscr/rjad414
9. Komyakov B, Ochelenko V, Guliev B, Shevnev M. Ureteral substitution with appendix. *Int J Urol.* 2020;27(8):663–669. doi:10.1111/iju.14268
10. O'Rourke TK, Gn M, Patel HV, et al. The urologist and the appendix: a review of appendiceal use in genitourinary reconstructive surgery. *Urology.* 2022;159:10–15. doi:10.1016/j.urolgy.2021.10.007
11. Kruss R, Camey JR, Roucaute IP. Replacement of the lumbar ureter with the appendix. *Mem Acad Chir.* 1959;85:315–319.
12. Onal B, Gultekin MH, Simsekoglu MF. Preputial graft ureteroplasty for the treatment of complex ureteral stricture: a new surgical technique and review of literature. *J Endourol Case Rep.* 2018;4(1):136–139. doi:10.1089/cren.2018.0055

13. Valimungighe M, Ahuka OLA, Elomba. Aspects épidémiologique et anatomoclinique des plaies abdominales par armes à l'Hopital Général de Référence de Beni, Est de la République Démocratique du Congo. *Revue Médicale de Grands Lac*. 2023. French.
14. Hefermehl LJ, Tritschler S, Kretschmer A, et al. Open ureteroplasty with buccal mucosa graft for long proximal strictures: a good option for a rare problem. *Investig Clin Urol*. 2020;61(3):316. doi:10.4111/icu.2020.61.3.316
15. Springer A, Fartacek R, Reck C, Horcher E. Appendix vermiformis as a left pyelo-ureteral substitute in a 6-month-old girl with solitary kidney. *Afr J Paediatr Surg*. 2011;8(2):218. doi:10.4103/0189-6725.86067
16. Barlow A, Muhleman M, Gielecki J, Matusz P, Tubbs RS, Loukas M. The vermiform appendix: a review. *Clin Anat*. 2013;26:833–842. doi:10.1002/ca.22269
17. Avci E, Atıcı SD, Uylas U, Kamer E. Stentless repair of left urethral defect with appendiceal interposition: a case report. *Int J Surg Case Rep*. 2022;91. doi:10.1016/j.ijscr.2022.106805
18. Yarlagaadda VK, Nix JW, Benson DG, Selph JP. Feasibility of intra-corporeal robotic-assisted laparoscopic appendiceal interposition for ureteral stricture disease: a case report. *Urology*. 2017;109:201–205. doi:10.1016/j.urology.2017.08.017

Research and Reports in Urology

Dovepress

Publish your work in this journal

Research and Reports in Urology is an international, peer-reviewed, open access journal publishing original research, reports, editorials, reviews and commentaries on all aspects of adult and pediatric urology in the clinic and laboratory including the following topics: Pathology, pathophysiology of urological disease; Investigation and treatment of urological disease; Pharmacology of drugs used for the treatment of urological disease. The manuscript management system is completely online and includes a very quick and fair peer-review system, which is all easy to use. Visit <http://www.dovepress.com/testimonials.php> to read real quotes from published authors.

Submit your manuscript here: <https://www.dovepress.com/research-and-reports-in-urology-journal>