

Ultrasound B-Scan for Posterior Segment and Extraocular Evaluation in Ocular Cysticercosis

Vaidehi D Bhatt¹, Kalpana D Bhatt¹, Deepak C Bhatt¹, Supriya Dabir², Jay U Sheth³,
Tos TJM Berendschot⁴, Roel J Erckens⁴, Carroll AB Webers⁴

¹UBM Institute, Mumbai, India; ²Department of Retina, Rajan Eye Care Pvt Ltd, Chennai, India; ³Department of Retina Services, Shantilal Shanghvi Eye Institute, Mumbai, India; ⁴University Eye Clinic Maastricht, Maastricht, The Netherlands

Correspondence: Vaidehi D Bhatt, UBM Institute, A/I Ganesh Baug, Dadar, Mumbai, 400019, India, Tel +91-9821525810, Email vaidehibhatt94@gmail.com

Purpose: Cysticercosis, caused by *Taenia solium* larvae, can affect various ocular and extraocular structures, leading to significant morbidity. Ultrasound B-scan imaging plays a pivotal role in diagnosing and classifying cysticercosis lesions. The aim of the study was to describe the ultrasound B-scan characteristics of ocular and extraocular cysticercosis, proposing a classification system based on anatomical localization to enhance understanding and management.

Patients and Methods: A retrospective study of consecutive cases with intraocular or extraocular cysticercosis was conducted from January 1993 to December 2023 in Mumbai, India. B-scan ultrasound was performed by an experienced imaging specialist. Descriptive statistics were used to summarize demographic characteristics and the proportion of cysticercosis in each anatomical location. Cysticercosis lesions were classified based on anatomical location observed during imaging.

Results: Amongst the 56 eyes evaluated, intraocular posterior segment involvement (n=25) and extraocular involvement (n=31) were observed. Extraocular cysticercosis predominantly affected the medial rectus muscle (40%), followed by the inferior rectus (28%), lateral rectus (20%), and superior rectus muscles (12%). Orbital cysts were localized in the posterior extraconal (50%), anterior extraconal (34.33%), and intraconal (16.67%) regions. Intra-vitreous cysticercosis (n=9) exhibited thin-walled cysts with minimal inflammation, progressing to thickened cyst walls in the late stages. Sub-hyaloid cysticercosis (n=8) showed initial thin vitreous detachment, progressing to thickened vitreous adhesions. Sub-retinal cysticercosis (n=9) without retinal detachment indicated early disease, while cases with detachment suggested disease progression.

Conclusion: The proposed anatomical classification system based on B-scan ultrasound features provides a structured approach to categorizing cysticercosis lesions, enhancing understanding and management in ophthalmic practice.

Keywords: cysticercosis, ultrasound, orbit, vitreous, retina

Introduction

Cysticercosis, caused by the larval stage of the tapeworm *Taenia solium*, is a parasitic infection with significant global public health implications, particularly in low- and middle-income countries.¹⁻³ The geographic distribution of cysticercosis correlates with regions where *Taenia solium* is endemic, including parts of Latin America, Sub-Saharan Africa, and South and Southeast Asia.¹⁻³ Poor sanitation, lack of veterinary control, and consumption of contaminated food or water are key risk factors contributing to its prevalence in these areas.¹⁻³ This parasitic infection affects various organs, including the eye and its surrounding structures, posing both clinical and public health challenges.

Cysticercosis is acquired through the ingestion of food or water contaminated with *Taenia solium* eggs.¹⁻³ Upon ingestion, the eggs hatch in the intestines, releasing larvae that penetrate the intestinal wall and migrate to various tissues, including the eye.⁴ Ocular cysticercosis occurs when these larvae localize to the eye or its adnexa, causing a range of clinical manifestations from mild discomfort to severe vision loss and orbital inflammation.^{5,6} The immune response to cysticerci plays a central role in the pathophysiology of the disease. The larvae elicit a granulomatous inflammatory reaction, which can cause tissue damage, fibrosis, and clinical symptoms such as pain, redness, and impaired vision.⁷ In

cases of orbital involvement, the immune-mediated inflammation may lead to complications like proptosis and optic neuropathy, further highlighting the need for timely diagnosis and management.

Diagnosing ocular and orbital cysticercosis can be challenging due to the diverse clinical presentations and the lack of specific signs and symptoms. Clinical examination alone may not always be conclusive, particularly when cysts are located in deeper ocular structures or within the orbit.⁸ Imaging modalities such as B-scan ultrasound play a crucial role in facilitating accurate diagnosis and localization of cysts in such cases.⁹

B-scan ultrasound is a non-invasive imaging technique that utilizes sound waves to visualize internal ocular structures. It is particularly useful in cases where direct visualization is limited, such as in the presence of opacities or posterior segment pathology.¹⁰ In ocular and orbital cysticercosis, B-scan ultrasound can detect characteristic features suggestive of cysticercosis, including well-defined cystic lesions with internal reflectivity and associated acoustic shadowing.¹¹ Additionally, it helps differentiate intraocular cysticercal lesions from other vitreoretinal disorders.¹²

The posterior segment of the eye, including the vitreous, retina, and choroid, is a common site of involvement for cysticercosis. Beyond the posterior segment, cysticercosis may also involve extraocular muscles, causing muscular cysticercosis.¹³ In resource-limited settings, where access to advanced imaging modalities such as CT or MRI may be restricted, B-scan ultrasound offers a practical and cost-effective alternative for detecting extraocular muscle involvement. Furthermore, orbital cysticercosis, characterized by cysticerci lesions within the orbital soft tissues, can lead to complications such as optic nerve compression and proptosis if not promptly recognized and managed.¹⁴ However, existing literature provides limited insights into the systematic characterization of cysticercosis on B-scan ultrasound, and no widely accepted classification system based on ultrasound features currently exists.

This study aims to address these gaps by describing the B-scan characteristics of 56 eyes with ocular and extraocular cysticercosis. We propose a structured classification system that categorizes cysticercosis according to its anatomical localization and B-scan ultrasound features. This approach not only enhances our understanding of the disease but also provides a practical framework for ophthalmologists to diagnose and manage this parasitic infection more effectively, particularly in settings where advanced imaging is unavailable.

Materials and Methods

This study constitutes a non-interventional retrospective examination of consecutive cases involving patients diagnosed with an intraocular posterior segment or extraocular cysticercosis. All patients were confirmed cysticercosis based on their response to medical management and/or confirmed by surgical excision and microbiological evaluation. The study was conducted at a single tertiary ophthalmic ultrasound imaging center situated in Mumbai, India, spanning from January 1993 to December 2023. The study was performed in accordance with the tenets outlined in the Declaration of Helsinki and approval was obtained from the Harmony Ethics Research Committee. Written informed consent for both scanning procedures and potential publication of findings was obtained from all participating patients.

Imaging Technique

The B-scan ultrasound examination was conducted using a specialized ophthalmic ultrasound machine (Paradigm B-scan from 1993–2003; and Sonomed VuMax HD from 2004–2023). This device is equipped with a 12.5 MHz dedicated ophthalmic probe, which features a diameter of 1 cm. This design facilitates optimal contact with the semi-circular eyelid, ensuring comprehensive imaging coverage. The gain setting and Time-Gain Compensation (TCG) were pre-configured to achieve high-quality images within the echo-poor vitreous cavity. For visualization of the orbital cavity, the TCG settings were adjusted to optimize imaging of the echogenic fatty orbital tissue. The default vitreous settings were used for imaging the vitreous cavity and the default orbital settings were utilized for scanning of the muscles and the orbit. Additionally, B-scan parameters included the use of a 10 MHz ophthalmic probe with a small diameter for effective contact with the ocular surface. The brightness was set at 70 dB, an ideal setting to visualize the anechoic vitreous cavity and to accentuate the cyst wall. The focus setting was positioned in the middle of the image to ensure optimal highlighting of the cyst. A single imaging specialist (DB) with more than 35 years of experience in ocular imaging performed all ultrasound B-scans, guaranteeing consistency and dependability in data collection.

Anatomical Classification of Cysticercosis

Cysticercosis lesions were classified based on their anatomical localization within the eye and orbit. The intraocular posterior segment included intravitreous, subhyaloid, and subretinal cysticercosis, while the extraocular segment encompassed intramuscular and orbital cysticercosis. The classification was determined through B-scan ultrasound characteristics observed during imaging. Additional features such as retinal detachment (RD), posterior vitreous detachment (PVD), and vitreous inflammation were also noted during the classification process. This classification system provided a structured approach for categorizing cysticercosis based on anatomical location, facilitating improved understanding and management of this parasitic infection in ophthalmic practice.

Statistical Analysis

Statistical analysis was performed to summarise the demographic characteristics, including mean age and gender distribution, among the study eyes. Descriptive statistics in the form of the proportion of cysticercosis in each anatomical location was determined using percentages.

Results

Study Cohort

The study cohort consisted of 56 eyes of 56 patients presenting with posterior segment or orbital cysticercosis. The average age of the study population was 45.6 years, with a standard deviation of 16.8 years. Gender distribution among the participants revealed a slight predominance of males over females (M: F = 32: 24).

Anatomical Distribution

Among the 56 eyes examined, 31 exhibited extraocular cysticercosis, while the remaining 25 displayed cysticercosis in the posterior segment. Within the subset of extraocular cysticercosis, 25 eyes manifested intramuscular involvement, with the remaining 6 eyes presenting with cysts distributed within the orbital region. Among the 25 eyes with intramuscular involvement, the cyst was predominantly observed in the medial rectus muscle (10 out of 25 eyes, accounting for 40%), followed by the inferior rectus muscle (7 out of 25 eyes, representing 28%), the lateral rectus muscle (5 out of 25 eyes, comprising 20%), and the superior rectus muscle (3 out of 25 eyes, totaling 12%), respectively.

Intra-Vitreous Cysticercosis (Figure 1)

Nine cases of intra-vitreous cysticercosis were identified in this study. In the early stages, characterized by thin-walled cysts, minimal vitreous inflammation (low echogenicity), and few vitreous membranes, were observed in three cases. Conversely, late-stage cases exhibited increased vitreous inflammation leading to the formation of multiple vitreous membranes surrounding the cyst, resulting in thickening of the cyst wall.

Sub-Hyaloid Cysticercosis (Figure 2)

Seven cases of sub-hyaloid cysticercosis were identified. Typically, sub-hyaloid cysticercosis is presented as thin-walled cysts, as they occupy a potential space within the eye. Early stages of this condition showed thin vitreous detachment with minimal vitreous reaction. However, prolonged sub-hyaloid cysticercosis led to the thickening of the vitreous detachment.

Sub-Retinal Cysticercosis (Figures 3 and 4)

Among the cases of sub-retinal cysticercosis, five were identified without retinal detachment. In the early stages, sub-retinal cysticercosis may not cause exudation, thereby avoiding retinal detachment. However, four cases were observed with retinal detachment, indicating the progression of the disease and the potential for secondary vitreous inflammation.

Muscular Cysticercosis (Figure 5)

A total of 25 cases of muscular cysticercosis were noted in this study. Among them, 15 cases exhibited cysts with scolex, while the remaining 10 cases showed only scolex without cysts. Detailed information regarding the muscles predominantly affected has been provided previously.

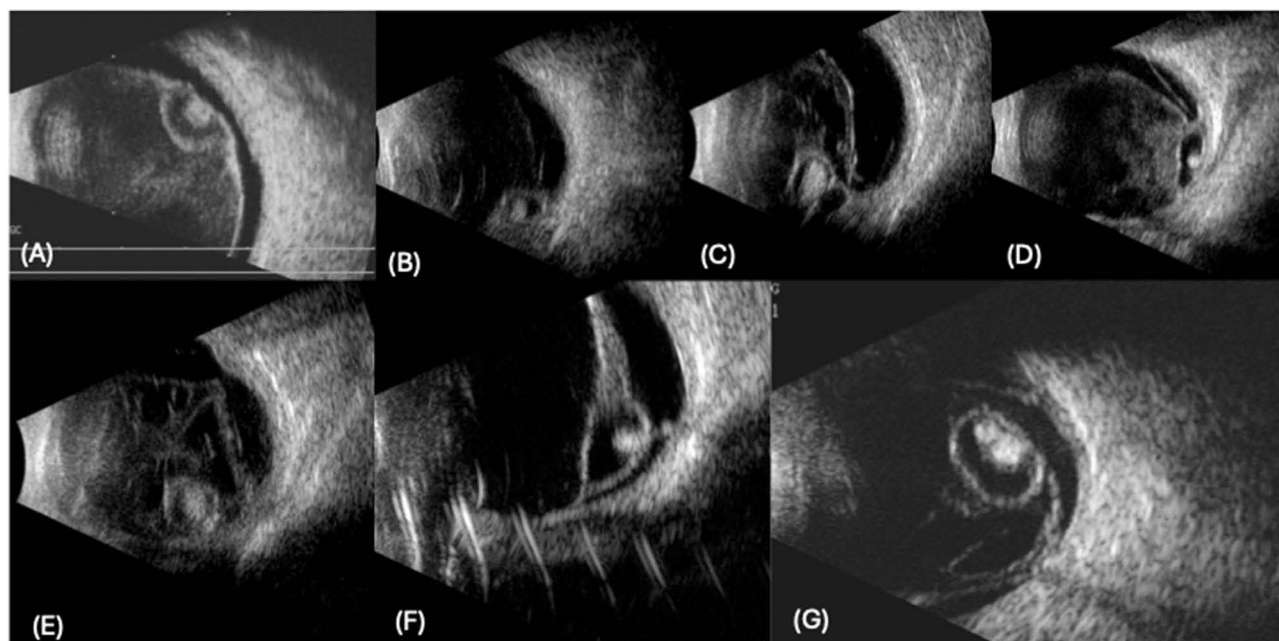


Figure 1 Cysticercosis within the vitreous cavity is seen as a thick-walled cyst with an echogenic scolex within it. (A) cysticercosis causing dense vitreous inflammation with complete vitreous detachment, (B) cysticercosis stuck to the retinal wall with minimal vitreous inflammation, (C) long standing cysticercosis leading to multiple vitreous membranes, (D) cysticercosis adherent to retinal surface with surrounding vitreous inflammation, (E) early stage of cysticercosis with thin wall and low intensity vitreous inflammation, (F) long standing cysticercosis leading to dense vitreous membrane formation around the cyst, (G) thick walled cysticercosis leading to multiple vitreous membrane formation.

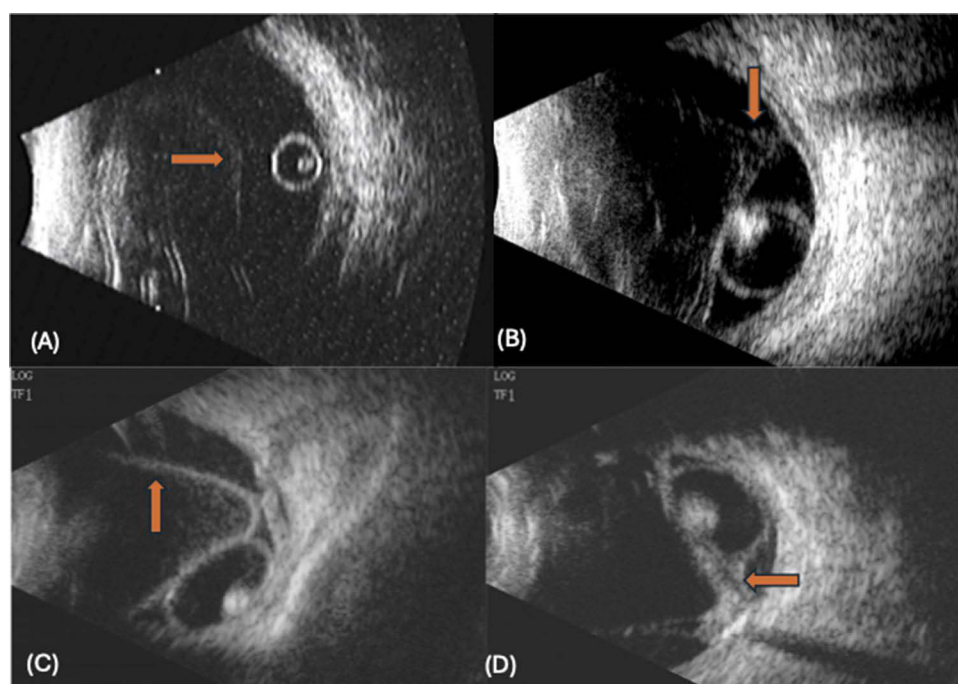


Figure 2 Sub-Hyaloid cysticercosis are usually thin walled. (A) thin walled cysticercosis with complete vitreous detachment (right arrow), (B) cysticercosis with thin vitreous detachment noted attached to the disc (down arrow), (C) cysticercosis causing severe inflammatory reaction and leading to complete thick vitreous detachment (up arrow), (D) long standing cysticercosis with thick vitreous detachment attached to the disc (left arrow).

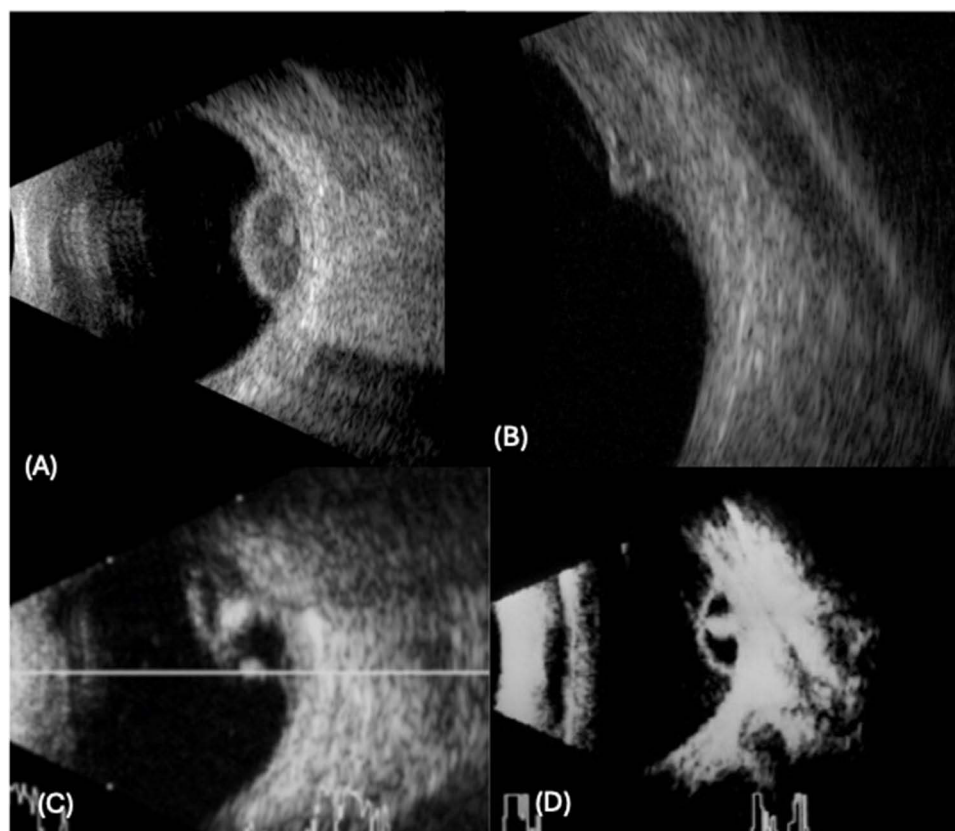


Figure 3 Sub-retinal cysticercosis with no retinal detachment. (A) thick walled cysticercosis with inflammatory reaction in the cyst, (B) small cysticercosis, (C) large sub-retinal cysticercosis with calcified scolex, (D) thin walled cysticercosis.

Orbital Cysticercosis (Figure 6)

Among the 6 eyes with orbital cysticercosis, the cyst was located in the posterior extraconal region in 3 eyes (50%), the anterior extraconal region in 2 eyes (33.33%), and the intraconal region in one eye (16.67%).

Discussion

The study presented here provides a comprehensive analysis of cysticercosis affecting the eye and its surrounding structures, involving 56 eyes with various manifestations of the disease. The anatomical distribution of cysticercosis lesions was delineated, including intraocular posterior segment and extraocular involvement, with detailed observations of cyst characteristics and associated features. Specifically, the study identified cases of intra-vitreous, sub-hyaloid, sub-retinal, muscular, and orbital cysticercosis, each presenting distinct clinical and imaging characteristics. Notably, the proposed anatomical classification system based on B-scan ultrasound features offers a structured approach for categorizing cysticercosis according to its localization, thereby enhancing the understanding and management of this parasitic infection in ophthalmic practice.

Cysticercosis, caused by the larval stage of the tapeworm *Taenia solium*, typically results from the ingestion of contaminated food or water containing tapeworm eggs.^{1–3} Upon ingestion, the eggs hatch in the intestines, releasing larvae that can migrate to various tissues and organs, including the eye.^{1–3} Ocular cysticercosis manifests when these larvae localize to ocular or periocular tissues, leading to a diverse range of clinical presentations.^{4–8} The eye serves as a unique site for cysticercosis involvement, posing diagnostic challenges due to varied symptoms and the potential for deeper tissue infiltration. In this context, imaging modalities such as B-scan ultrasound play a crucial role in facilitating accurate diagnosis and localization of cysts, aiding in timely intervention and management.

The observation that 31 out of 56 eyes exhibited extraocular cysticercosis while the remaining 25 displayed cysticercosis in the posterior segment suggests that cysticercosis can affect both ocular and periocular tissues. This

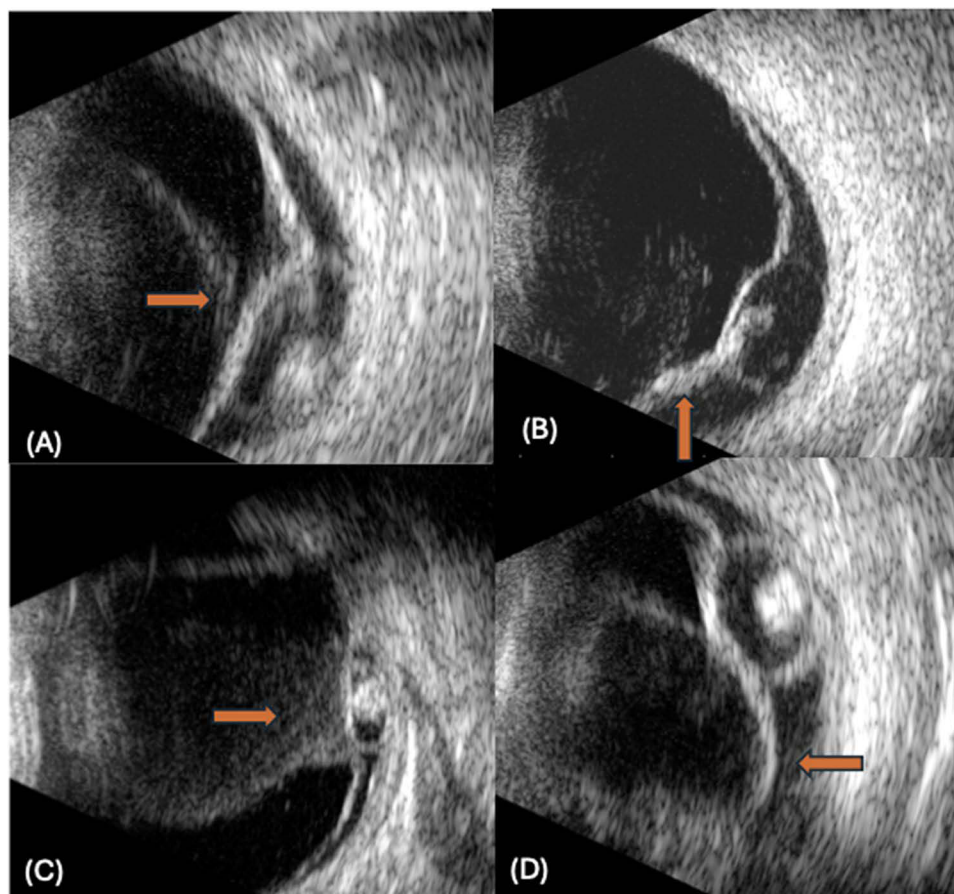


Figure 4 Sub-retinal cysticercosis with retinal detachment. (A) thick walled cysticercosis with exudative retinal detachment and vitreous detachment too (right arrow), (B) cysticercosis with thick retinal detachment (up arrow), (C) cysticercosis with shallow retinal detachment and dense vitreous inflammation (right arrow), (D) cysticercosis with large retinal detachment and retinal loops (left arrow).

distribution may be influenced by various factors such as the route of larval migration, host immune response, and local tissue susceptibility. Within the subset of extraocular cysticercosis, the findings revealed two distinct patterns of involvement: intramuscular and orbital. Among the 25 eyes with intramuscular involvement, the cysts were predominantly observed within the extraocular muscles, with varying degrees of distribution among different muscle groups. The medial rectus muscle was the most commonly affected, accounting for 40% of cases, followed by the inferior rectus muscle (28%), the lateral rectus muscle (20%), and the superior rectus muscle (12%). In contrast, in a study by Rath et al,⁸ the superior rectus was the most commonly involved muscle. The distribution pattern may reflect the relative susceptibility of different extraocular muscles to cysticercosis infiltration. In addition to intramuscular involvement, six eyes exhibited cysticercosis within the orbital region. The localization of cysts within the orbit was further categorized into three regions: posterior extraconal, anterior extraconal, and intraconal. The majority of orbital cysts were located in the posterior extraconal region (50%), followed by the anterior extraconal region (33.33%) and the intraconal region (16.67%). This distribution pattern underscores the potential for cysticercosis to affect various anatomical compartments within the orbit, highlighting the importance of comprehensive imaging evaluation for accurate localization and management. The observed distribution patterns of cysticercosis within the ocular and orbital regions may be attributed to several factors related to the pathogenesis and progression of the disease. The preferential involvement of certain extraocular muscles, such as the medial rectus muscle, may be influenced by factors such as muscle size, vascular supply, and proximity to the optic nerve. Similarly, the localization of orbital cysts within specific regions may be influenced by factors such as tissue vascularity, lymphatic drainage, and anatomical barriers within the orbit.

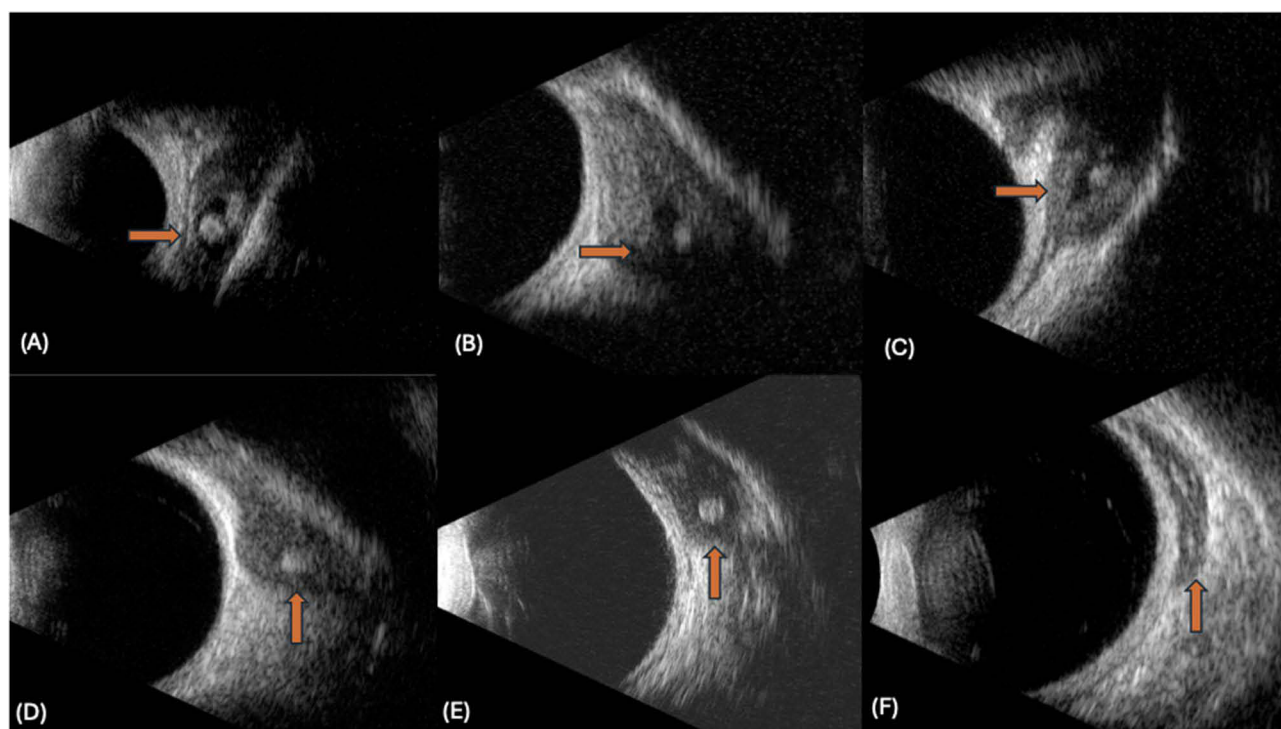


Figure 5 Muscular cysticercosis. (A–C) shows cysticercosis with cyst in muscles (right arrow), (D–F) shows cysticercosis with scolex and muscular thickening, no cyst noted (up arrow).

Intra-vitreous cysticercosis, identified in nine cases, exhibited distinct features at different stages of the disease. In the early stages, characterized by thin-walled cysts and minimal vitreous inflammation, the cysts appeared as relatively discrete entities within the vitreous cavity. The low echogenicity observed in these cases suggests limited inflammation and cellular activity within the vitreous humor. Additionally, the presence of a few vitreous membranes surrounding the cyst indicates a relatively localized inflammatory response. However, few eyes demonstrated increased vitreous inflammation, manifested by the formation of multiple vitreous membranes encasing the cyst. This would represent the late stages of intra-vitreous cysticercosis. This increased inflammatory reaction likely contributes to the thickening of the cyst wall observed in late-stage cases. There have been cases reported with the presence of tractional bands from the vitreous base up to the optic disc and even development of full-thickness macular hole (FTMH) secondary to progressive vitreous traction in these eyes.^{10,11} The progression from early to late-stage intra-vitreous cysticercosis underscores the dynamic nature of the inflammatory process and its impact on the structural integrity of the cyst.

Sub-hyaloid cysticercosis, observed in eight cases, also exhibited characteristic features reflective of its pathogenesis and progression. Typically, sub-hyaloid cysts present as thin-walled structures occupying a potential space within the eye, often between the posterior hyaloid membrane and the retina. In the early stages of this condition, thin vitreous detachment with minimal vitreous reaction was observed, indicating a relatively benign inflammatory response. However, with prolonged sub-hyaloid cysticercosis, there was evidence of thickening of the vitreous detachment. This thickening may result from chronic inflammation and fibrosis, leading to the formation of adhesions between the posterior hyaloid membrane and the underlying retina. The progression of sub-hyaloid cysticercosis highlights the potential for complications associated with chronic inflammation and fibrotic changes within the vitreous cavity.

Sub-retinal cysticercosis, identified in cases with and without retinal detachment, demonstrated varying degrees of disease severity and progression. In cases without retinal detachment, the early stages of sub-retinal cysticercosis may not cause exudation, thereby avoiding retinal detachment. This suggests that the cysts may initially remain localized within the sub-retinal space without disrupting the integrity of the neurosensory retina. However, in cases where retinal detachment occurred, it indicates the progression of the disease and the potential for secondary vitreous inflammation.

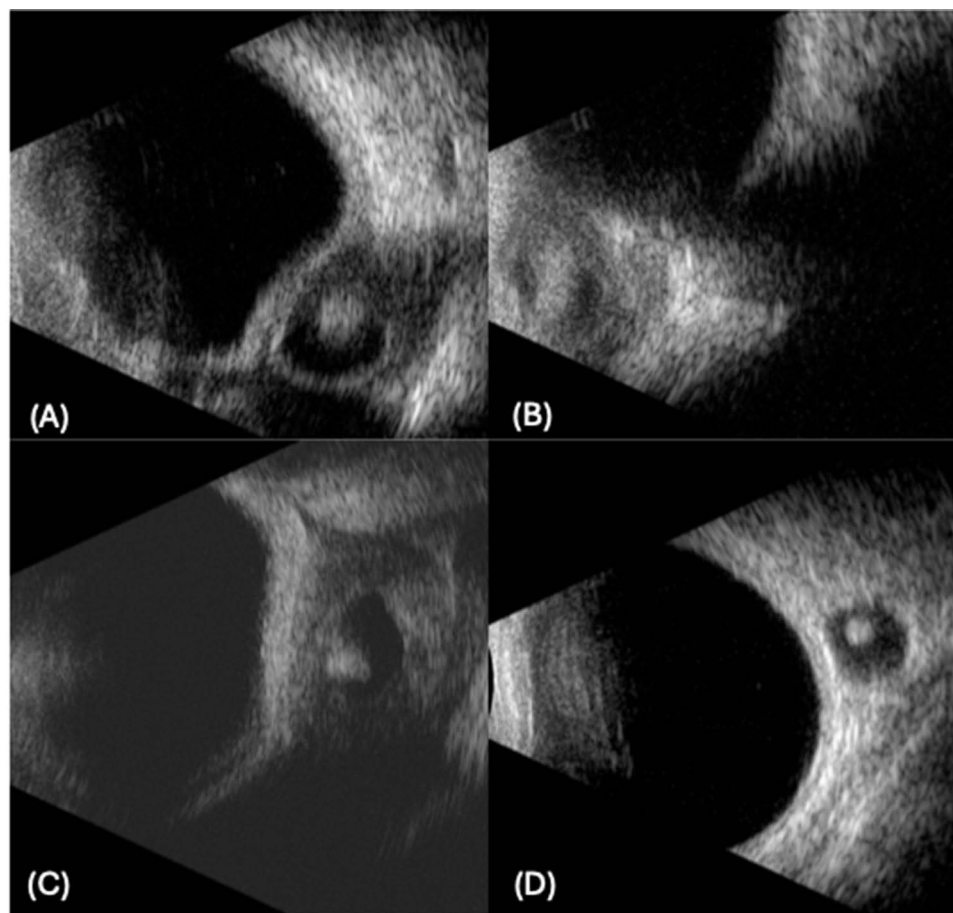


Figure 6 Orbital cysticercosis: (A) cysticercosis noted in the temporal extra-conal space, (B) cysticercosis noted in the nasal quadrant of the orbit anteriorly, (C) cysticercosis noted in the inferior extra-conal space, (D) intra-conal cysticercosis.

Retinal detachment likely results from tractional forces exerted by the cyst on the retina or from inflammatory changes disrupting the retinal architecture. Grover et al reported a case with twin cysticercosis, in which one cyst was present intravitreally and the other was present in the subretinal location along with the presence of an RD.¹² Cases with subretinal cysticercosis have been reported to have associated retinal vasculitis and vitreous hemorrhage.^{13,14} Nonetheless, the presence of retinal detachment underscores the need for prompt intervention to prevent irreversible visual impairment.

B-scan ultrasound offers several advantages in the evaluation of cysticercosis affecting the eye and orbit. As a non-invasive imaging modality, B-scan ultrasound provides real-time visualization of internal ocular structures, allowing for the detection of characteristic features suggestive of cysticercosis lesions.^{7,8,15,16} These features include well-defined cystic lesions with internal reflectivity and associated acoustic shadowing, which aid in differentiating cysticercosis from other vitreoretinal disorders.^{7,8,15,16} Additionally, B-scan ultrasound enables the localization of cysticercosis lesions within deeper ocular structures, facilitating accurate diagnosis and guiding treatment strategies.^{7,8,15,16} Moreover, B-scan ultrasound serves as a cost-effective alternative to advanced imaging modalities like CT or MRI, particularly in resource-limited settings where access may be limited.^{7,8,15,16}

Despite its strengths, the current study is not without limitations. Firstly, the retrospective nature of the study may introduce selection bias and limit the generalizability of the findings. The study was conducted at a single tertiary ophthalmic ultrasound imaging center, which may also restrict the applicability of findings to other geographic or clinical settings. Additionally, reliance on a single imaging specialist introduces the possibility of operator-dependent bias, and results may differ in settings with varied operator expertise. Furthermore, the study spans three decades during which

advancements in imaging technology occurred. At the same time, efforts were made to maintain consistency by adjusting the brightness and the gain settings. Additionally, the reliance on B-scan ultrasound for lesion characterization may overlook subtle features that could be detected with other imaging modalities such as CT or MRI. Moreover, the sample size of the study cohort may be relatively small, potentially impacting the statistical power and precision of the results. Future studies with larger, prospective cohorts, inclusion of multimodal imaging approaches, and evaluations across diverse geographic and clinical settings are warranted to validate the proposed classification system and further elucidate the clinical implications of cysticercosis affecting the eye and orbit.

Despite the limitations, the current study offers several strengths that contribute to its clinical significance. The comprehensive characterization of cysticercosis lesions using B-scan ultrasound provides valuable insights into the imaging features and anatomical distribution of the disease. Furthermore, the proposed anatomical classification system offers a practical framework for clinicians to categorize cysticercosis lesions based on their localization, aiding in diagnostic accuracy and treatment planning. The inclusion of detailed observations on cyst characteristics and associated features enhances the utility of the classification system in clinical practice, enabling tailored management strategies for patients with ocular and orbital cysticercosis.

Moving forward, future research efforts should focus on evaluating the diagnostic accuracy of B-scan ultrasound against other imaging modalities such as CT or MRI could provide valuable insights into the optimal approach for lesion characterization. Longitudinal studies are warranted to assess the natural history of cysticercosis and evaluate the effectiveness of various treatment modalities, including medical and surgical interventions. Additionally, integrating the findings into routine clinical practice could involve developing standardized imaging protocols, which would help streamline the diagnostic process and facilitate earlier detection and management of ocular cysticercosis.

Conclusion

In conclusion, this study provides valuable insights into the imaging characteristics and anatomical distribution of ocular and orbital cysticercosis. The proposed anatomical classification system, based on B-scan ultrasound features, offers a structured framework for categorizing lesions by localization. This can potentially aid in differentiating cases requiring surgical versus medical management and in identifying those at higher risk of complications such as retinal detachment. Compared to other imaging modalities like CT and MRI, B-scan ultrasound remains a cost-effective, accessible tool with unique advantages in resource-limited settings. Furthermore, early-stage identification and precise localization of cysts are critical in minimizing visual morbidity, with potential implications for improving treatment outcomes. However, this single-center study acknowledges the need for broader validation through prospective, multicenter studies to enhance its generalizability. Future research should focus on refining the classification system and exploring its impact on clinical decision-making and treatment strategies in cysticercosis management.

Disclosure

The authors report no conflicts of interest in this work.

References

1. White AC. Neurocysticercosis: updates on epidemiology, pathogenesis, diagnosis, and management. *Annu Rev Med.* 2000;51(1):187–206. doi:10.1146/annurev.med.51.1.187
2. Nash TE, Garcia HH. Diagnosis and treatment of neurocysticercosis. *Nat Rev Neurol.* 2011;7(10):584–594. doi:10.1038/nrneurol.2011.135
3. Dixon MA, Winskill P, Harrison WE, Basáñez MG. Taenia solium taeniasis/cysticercosis: from parasite biology and immunology to diagnosis and control. *Adv Parasitol.* 2021;112:133–217. doi:10.1016/bs.apar.2021.03.003
4. Pujari A, Bhaskaran K, Modaboyina S, et al. Cysticercosis in ophthalmology. *Surv Ophthalmol.* 2022;67(2):544–569. doi:10.1016/j.survophthal.2021.07.002
5. Dhiman R, Devi S, Duraipandi K, et al. Cysticercosis of the eye. *Int J Ophthalmol.* 2017;10(8):1319–1324. doi:10.18240/ijo.2017.08.21
6. Chowdhary A, Bansal R, Singh K, Singh V. Ocular cysticercosis—a profile. *Trop Doct.* 2003;33(3):185–188. doi:10.1177/004947550303300327
7. Pujari A, Chawla R, Singh R, Mehta A. Ultrasound-B scan: an indispensable tool for diagnosing ocular cysticercosis. *BMJ Case Rep.* 2017;2017:bcr2017219346. doi:10.1136/bcr-2017-219346
8. Rath S, Honavar SG, Naik M, et al. Orbital cysticercosis: clinical manifestations, diagnosis, management, and outcome. *Ophthalmology.* 2010;117(3):600–605.e1. doi:10.1016/j.ophtha.2009.07.030

9. Bhatt V, Bhatt D, Barot R, Sheth J. Ultrasound biomicroscopy for zonular evaluation in eyes with ocular trauma. *Clin Ophthalmol*. 2021;15:3285–3291. doi:10.2147/OPTH.S323349
10. Seo MS, Woo JM, Park YG. Intravitreal cysticercosis. *Korean J Ophthalmol*. 1996;10(1):55–59. doi:10.3341/kjo.1996.10.1.55
11. Kumar V, Padhy SK. Intravitreal cysticercosis with full-thickness macular hole. *Ophthalmol Retina*. 2021;5(1):22. doi:10.1016/j.oret.2020.09.014
12. Grover R, Varshney A, Juneja S, Awashti U, Singh SR. Intraocular twin cysticercosis. *GMS Ophthalmol Cases*. 2023;13:Doc18. doi:10.3205/oc000226
13. Bartholomew RS. Subretinal cysticercosis. *Am J Ophthalmol*. 1975;79(4):670–673. doi:10.1016/0002-9394(75)90809-0
14. Jain RS, Kumar S, Bhana I, Agarwal R. Ocular cysticercosis with vitreous hemorrhage: a rare complication of a common disease. *Springerplus*. 2015;4(1):217. doi:10.1186/s40064-015-1006-7
15. Babalola O, Adu A, Akano A. Ocular cysticercosis in a 32-year-old man in Abuja: ultrasonic features as an aid in diagnosis. *Clin Ophthalmol*. 2013;7:2275–2279. doi:10.2147/OPTH.S52690
16. Soman N, Khandelwal R, Maheshwari S. Case of orbital cysticercosis presenting as recurrent cellulitis diagnosed on multi-modality imaging. *Cureus*. 2021;13(9):e18242. doi:10.7759/cureus.18242

Clinical Ophthalmology

Publish your work in this journal

Clinical Ophthalmology is an international, peer-reviewed journal covering all subspecialties within ophthalmology. Key topics include: Optometry; Visual science; Pharmacology and drug therapy in eye diseases; Basic Sciences; Primary and Secondary eye care; Patient Safety and Quality of Care Improvements. This journal is indexed on PubMed Central and CAS, and is the official journal of The Society of Clinical Ophthalmology (SCO). The manuscript management system is completely online and includes a very quick and fair peer-review system, which is all easy to use. Visit <http://www.dovepress.com/testimonials.php> to read real quotes from published authors.

Submit your manuscript here: <https://www.dovepress.com/clinical-ophthalmology-journal>

Dovepress

Taylor & Francis Group